

EARLY INTRAUTERINE CYTOMEGALOVIRUS INFECTION: EXTREME SEQUELS WITH GOOD SEIZURE CONTROL

MAŠA MALENICA¹, LJERKA CVITANOVIĆ ŠOJAT¹, ROMANA GJERGJA JURAŠKI¹,
OKTAVIJA ĐAKOVIĆ RODE², HRVOJE IVAN PEČINA³

Cytomegalovirus (CMV) is the most common congenital viral infection in humans with great propensity to infect and injure developing nervous system. The extent of damage directly depends on the time of infection. In early CMV infections, the extent of neurologic damage most likely causes fetal death. We present a child with serology indicative of acute CMV infection and neuroimaging showing signs of early congenital infection. Seizures caused by severe central nervous system damage were well controlled with phenobarbital maintained within reference values in blood. In conclusion, severe neurologic damage caused by early congenital CMV infection emphasizes the importance of CMV infection stigmata recognition with early fetal sonography, and in suspected cases with serology. This case reveals insufficient diagnostic strategies, as well as deficient treatment options including the need for developing a safe and efficient vaccine. This child is an extraordinary example of surviving infant with extreme central nervous system damage and good seizure control.

Descriptors: CYTOMEGALOVIRUS; NERVOUS SYSTEM; FETAL DEATH; INFANT, PREMATURE; SEIZURES

INTRODUCTION

Cytomegalovirus (CMV) is the most common congenital viral infection in humans, occurring in 0.2%-2.5% of all live births, with great propensity to infect and damage developing nervous system (1). Even though the majority of infants exposed to CMV *in utero* will have no symptoms, in symptomatic ones the severity of neurologic injuries depends on the gestational age of the embryo or fetus at the time of infection, so an early infection leads to more severe migrational and developmental anomalies (2-4). Accord-

ingly, neuroimaging studies in symptomatic infants reveal a variety of findings such as intracranial calcifications, periventricular leukomalacia, cortical dysplasia, and migrational abnormalities such as schizencephaly, pachygyria, and lissencephaly (3, 4). Infection with CMV, in surviving infants, even in ones free from symptoms at birth, can lead to permanent central nervous system sequels such as perceptive hearing loss, mental retardation, cerebral palsy, seizures and visual defects (1). Among other known clinical symptoms of congenital CMV that are found in 10%-20% of infected neonates are intrauterine growth retardation (IUGR), microcephaly, hepatosplenomegaly, petechiae, jaundice, chorioretinitis, thrombocytopenia, and anemia (1).

We present a case of surviving infant with early congenital CMV infection showing extremely severe neurologic damage and good control of seizures.

after a complicated pregnancy which required bed-resting from 18th gestational week, and tocolytic therapy from 27th gestational week. The mother has already had two deliveries and one missed abortion. Neurologic damage suggestive of CMV infection was first noted in 35th gestational week by prenatal ultrasonography (US) scan revealing oligohydramnion, intrauterine growth retardation (IUGR), and enlarged lateral brain ventricles. The pregnancy was terminated by inducing premature delivery at 36 gestational weeks. The infant's birth weight was 2280 g, birth length 48 cm, head circumference 31.8 cm and Apgar score 9/10. He was microcephalic, with small mandible, high arched palate, short neck, poorly shaped ears, skin petechiae and edema, signs of retinitis and hepatosplenomegaly, with hypertonic musculature and systolic heart murmur. Within the first few hours of life, he expressed tonic contractions, hyperexcitability, irritability, tremor, and signs of respiratory distress. Initial routine workup confirmed thrombocytopenia (54x10⁹ platelets/L), raised liver function tests, and severe anemia. Bacterial culture of cere-

¹ Division of Pediatric Neurology, Department of Pediatrics, University Hospital Centre "Sestre milosrdnice"

² Department for Serological Diagnostics, University Hospital for Infectious Diseases "dr. Fran Mihaljević"

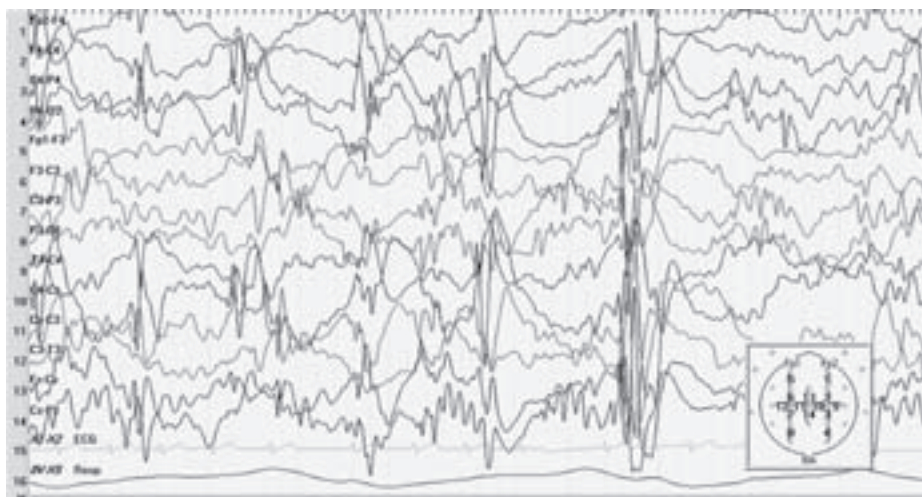
³ Department of Radiology, University Hospital Centre "Sestre milosrdnice"

Correspondence to:

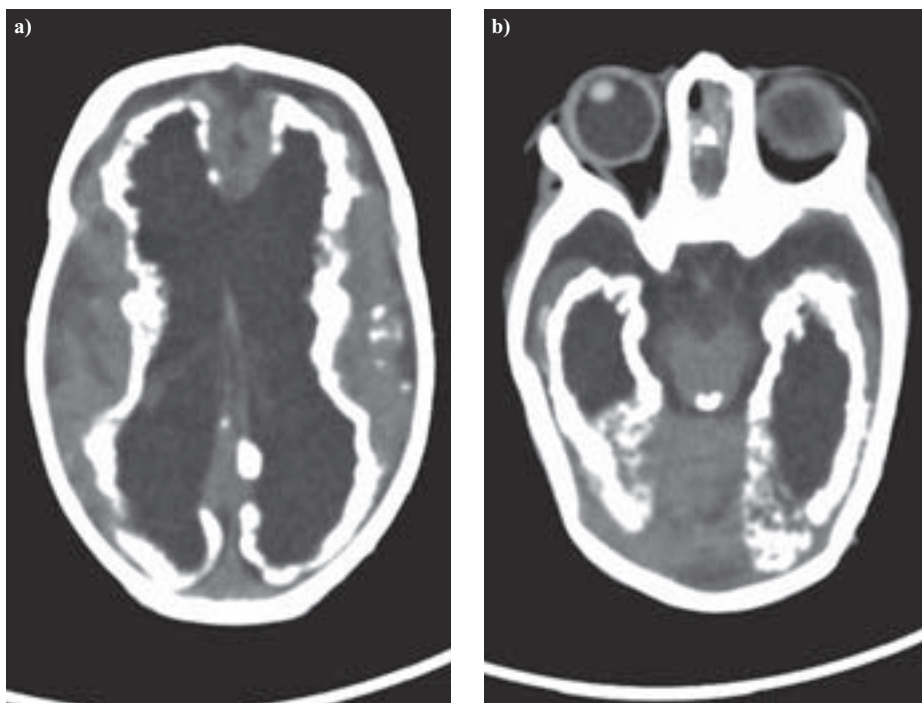
Maša Malenica, MD, Department of Paediatrics, University Hospital Centre "Sestre milosrdnice", Vinogradska cesta 29, 10 000 Zagreb, Croatia, e-mail: mgnjidic@yahoo.com

CASE REPORT

A male child with noted neurologic damage was born to a 36-year-old woman



Slika 1. EEG tijekom spavanja obavljen u dobi od 21 mjeseca
Figure 1. EEG during sleep done at 21 months



Slika 2a, 2b. CT mozga u dobi od 2,5 mjeseca
Figure 2 a and b. Unenhanced CT imaging of the brain done at the age of 2.5 months

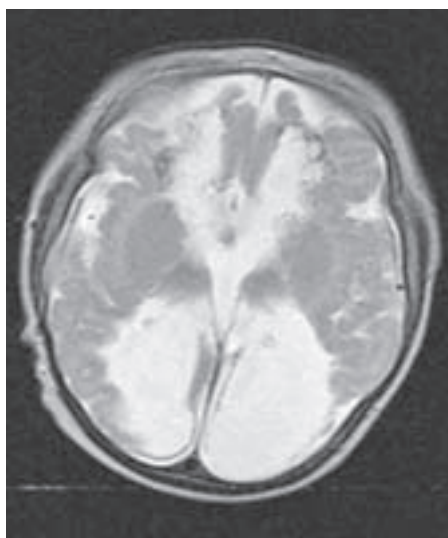
brospinal fluid, blood, nasopharyngeal, umbilical and ear canal smears as well as gastric aspirate were negative. He was immediately transferred to the intensive care unit where he received treatment for septicemia and anemia.

Clinical symptoms and laboratory findings prompted further evaluation of congenital infection. On the second day of the infant's life, routine serology tests were done to specify the causative agent. Suspected CMV infection was confirmed (using DiaSorin test, Saluggia, Italy): CMV IgM positive 1.156 index (positive

>1.1), CMV IgG positive 3.5 IU/mL (positive >0.4 IU/mL) with no evidence of rubella, toxoplasmosis, or other infection. Control serology done at 16 months of the infant's life showed no signs of acute CMV infection. Polymerase chain reaction (PCR) done within the first week of life revealed 1430 CMV DNA copies/mL. Parallel serology tests done in the mother (both on second day from delivery and 16 months later) showed no signs of acute CMV infection (CMV IgM negative, with no signs of rubella, toxoplasmosis or other infection).

Brain US done during the first week of life showed internal and external hydrocephaly, absent gyration, thin cortical and subcortical structures, cystic parenchyma changes, largely dilated lateral ventricles with massive periventricular calcifications and hypoplastic cerebellum. The brain stem evoked potentials revealed left-sided severe perceptive hearing loss with right-sided normal hearing. Later follow-up audiologic examinations showed no hearing loss progression. Ophthalmologic examination at birth and on follow-up showed chorioretinitis and optic pit.

Motor delay and signs of global retardation became apparent during the first month of life. Head did not follow in traction test, in ventral suspension legs were crossed, he would not release airways while on his stomach, musculature tonus was very high, there was no reaction to auditory or visual stimulus. There was no interest for his surroundings, nor was there any reaction to it. Seizure attacks started after the first month of life when antiepileptic therapy with phenobarbital was introduced. Blood concentration of phenobarbital has since been maintained within the reference values, with good control of seizures, even though electroencephalography (EEG) during sleep done at 21 months showed multifocal discharges (Figure 1). Unenhanced head computed tomography (CT) (Figure 2a and b) done at the age of 2.5 months revealed destructive encephalopathy, complete brain atrophy with cerebellar hypoplasia, extreme ventriculomegaly with a massive wall of periventricular calcifications, punctiforme calcifications in the thalamus, nucleus lentiformis and basal ganglia, with broad, flat gyri and shallow sulci. The brain parenchyma was severely reduced and dysmorphic with punctate calcifications. Magnetic resonance imaging (MRI) (Figure 3) done at the age of 12 months provided additional information on delayed myelinization, irregularity of the gray-matter to white-matter border, extremely thin corpus callosum, dilated cerebrospinal fluid space, hippocampal dysplasia, lissencephaly, colpocephaly, abnormal signal intensity in the white matter, hypoplastic brain stem and thickened cortex. During the first 6 months of life, the boy was hospitalized several times due to aspiration pneumonia caused by severe feeding problems, which gradually resolved. At the age of two years, af-



Slika 3. MR mozga u dobi od 12 mjeseci
Figure 3. MRI imaging of the brain done at the age of 12 months

ter having been receiving polyvalent physical therapy, he does not walk or talk, musculature tonus is diffusely increased, but social contact is improved. With phenobarbital blood concentrations still within the reference values, he has not had any seizures.

DISCUSSION

This is a case report of extremely severe early congenital CMV infection with extensive neurologic damage and good control of seizures. There are no reports of surviving infants with such a clinical course and extensive neurologic damage supported by serologic and neuroimaging findings, and with good control of seizures. It is not surprising that there is only paucity of reported cases since the risk of symptomatic congenital CMV among infected fetuses is 5%-15% after primary infection and less than 2% in previously seropositive mothers (1, 5).

Although rare, this case implies numerous diagnostic and treatment problems in CMV infections. For example, the exact time of infection is practically impossible to determine. The mother in this case did not record any illnesses during pregnancy, and since maternal infection may manifest itself as a mild flu-like illness, or may even be asymptomatic, it is a very unreliable factor in suspecting a CMV infection (4, 6). Moreover, being a mother of two children, one could assume she had been exposed to CMV earlier, hence considering a primary maternal infection is very unlikely. Besides primary

infection, CMV, like all herpes viruses, may undergo latency and reactivation perhaps due to suppressed immune system during pregnancy, thus causing a recurrent CMV infection. Such congenital infections following reactivated maternal infection are mostly asymptomatic, thus making it highly doubtful in this case with almost every possible infection sequel (1). It is also possible that an already seropositive pregnant woman becomes reinfected with a new strain of CMV (secondary CMV infection) different from the original by a key antigenetic site of envelope glycoprotein H (7). These secondary CMV infections are the major cause of symptomatic congenital infections (7). Knowing that as many as 80% of pregnant women are CMV seropositive, especially those that already have children at home, it is most likely that a new CMV strain was the source of infection in this case.

Unless done prior to pregnancy, serologic findings obtained during and after pregnancy cannot confirm the exact time of infection. Pass et al. (6) have shown that IgM antibody to CMV may persist from one to over 6 months after primary infection, so the presence of both IgG and IgM antibodies to CMV may indicate an infection that has occurred weeks or even months prior to pregnancy. In this case, serology done on the second day of the infant's life revealed positive IgM, which would lead to assuming an acute infection. However, the extent of neurologic damage clearly implied an early congenital infection, most likely somewhere towards the end of the first and beginning of the second trimester of pregnancy.

Fetal brain ultrasound (US) as the earliest applicable imaging method raised the question of intrauterine infection, later proven to be CMV by PCR and serology. The reported accuracy of US in predicting the outcome in congenitally infected newborns with symptoms at birth (8) proved to be correct in our case as well. In their series, Barkovich et al. (4) describe features seen on head CT and MRI that were all indicative of late first and early second trimester CMV infection. Published literature reviews and the extent of neural damage ruled out the possibility and efficacy of ganciclovir treatment. A few reports in which ganciclovir was used included treatment of acute organ disease such as pneumonia or hepatitis, which was not the case in our patient

(9). Other published cases report various drug doses, ages at treatment initiation, as well as treatment duration (10-12). Perhaps the major problem in the treatment seems to be resumption of viral replication following initial clinical efficacy.

Besides surviving such central nervous system damage and with the early onset of seizures, it is unexpected that in our patient it was possible to achieve good seizure control in these two years of his life only with antiepileptic monotherapy using phenobarbital twice daily in reference blood values.

CONCLUSION

After seeing the catastrophic result of this early congenital CMV infection, it is clear how necessary it is to emphasize the importance of CMV infection stigmata recognition with early fetal sonography, and furthermore with serology. It has been proven that both methods provide good correlation with the newborn outcome. As there is no successful antiviral treatment during pregnancy or after birth, it is necessary to prepare the parents for the possible severe outcomes. Perhaps the major issues this case reveals are the insufficient diagnostic strategies, as well as deficient treatment options including the need for developing a safe and efficient vaccine. This child is an extraordinary example of surviving infant with extreme central nervous system damage and good seizure control.

REFERENCES

- Ornoy A, Diav-Citrin O. Fetal effects of primary and secondary cytomegalovirus infection in pregnancy. *Reprod Toxicol* 2006;21:399-409.
- DeVries J. The ABCs of CMV. *Adv Neonatal Care* 2007;7:248-55.
- Malinger G, Lev D, Zahalka N, Aroia ZB, Watterberg N, Kidron D, et al. Fetal Cytomegalovirus infection of the brain: the spectrum of sonographic findings. *Am J Neuroradiol* 2003;24:28-32.
- Barkovich AJ, Lindan CE. Congenital cytomegalovirus infection of the brain: imaging analysis and embryologic considerations. *AJNR Am J Neuroradiol* 1994;15:703-15.
- Revello MG, Gerna G. Diagnosis and management of human cytomegalovirus infection in the mother, fetus, and newborn infant. *Clin microbial rev* 2002;15:680-715.
- Pass RF, Fowler KB, Boppana SB, Britt WJ, Stagno S. Congenital cytomegalovirus infection following first trimester maternal infection: symptoms at birth and outcome. *J Clin Virol* 2006;35:216-20.
- Boppana SB, Rivera LB, Fowler KB, Mach M, Britt WJ. Intrauterine transmission of cytomegalovirus to infants of women with preconceptual immunity. *NEJM* 2001;344:1366-71.

8. Ancora GL, Lazzaroto T, Venturi V, Tridapalli E, Sandri F, Menarini M, et al. Cranial ultrasound scanning and prediction of outcome in newborns with congenital cytomegalovirus infection. *J Pediatr* 2007;150:157-61.

9. Michaels MG, Greenbergs DP, Sabo DL, Wald ER. Treatment of children with congenital cytomeg-

alovirus infection with ganciclovir. *Pediatr Infect Dis J* 2003;22:504-9.

10. Fan-Harvard P, Nahata NC, Brady MT. Ganciclovir – a review of pharmacology, therapeutic efficacy and potential use for treatment of congenital cytomegalovirus pneumonia. *J Clin Pharmacol Ther* 1989;14:329-40.

11. Hocker JR, Cook LN, Adams G, Rabalais GPF. Ganciclovir therapy of congenital cytomegalovirus pneumonia. *Pediatr Infect Dis J* 1990;9:743-5.

12. Lombardi G, Garofoli F, Stornati M. Congenital cytomegalovirus infection: treatment, sequelae and follow-up. *J Matern Fetal Neonatal Med* 2010;3:45-8.

S a ž e t a k

RANA INTRAUTERINA CITOMEGALOVIRUSNA INFEKCIJA: EKSTREMNE POSLJEDICE S DOBROM KONTROLOM KONVULZIJA

M. Malenica, Lj. Cvitanović Šojat, R. Gjergja Juraški, O. Đaković Rode, H. I. Pečina

Citomegalovirusna infekcija (CMV) najčešća je kongenitalna virusna infekcija u ljudi s velikom sklonošću oštećenju živčanog sustava u razvoju. Opseg oštećenja izravno ovisi o vremenu pojave infekcije. U ranim CMV infekcijama opseg neurološkog oštećenja najčešće uzrokuje smrt ploda. Prikazano je dijete čija serologija upućuje na akutnu citomegalovirusnu infekciju i neuroradiološki nalazi koji upućuju na znakove rane kongenitalne infekcije. Konvulzije uzrokovane teškim oštećenjima središnjeg živčanog sustava izvršno su kontrolirane fenobarbitalom koncentracijama unutar referentnih vrijednosti u krvi. Teška neurološka oštećenja uzrokovana ranom CVM infekcijom naglašavaju potrebu otkrivanja CMV stigmi ranom fetalnom sonografijom, a u sumnjivim slučajevima i serologijom. Ovaj prikaz upućuje na nedovoljne dijagnostičke strategije kao i na nedovoljne opcije liječenja, uključujući i potrebu za razvojem sigurnog i učinkovitog cjepiva. Ovo dijete je izvanredan primjer teškog oštećenja centralnog živčanog sustava kod kojeg je postignuta dobra kontrola konvulzija.

Deskriptori: CITOMEGALOVIRUS; ŽIVČANI SUSTAV; FETALNA SMRT; NOVOROĐENČE, PREMATURUS; NAPADAJI

Primljeno/Received: 18. 1. 2011.

Prihvaćeno/Accepted: 3. 3. 2011.