

#3 HSF Meeting @ Croatia  
December 6-8, 2017  
THE WESTIN ZAGREB HOTEL  
ZAGREB, CROATIA  
  
PROGRAM BOOK

MEETING ORGANIZER & DIRECTOR:  
Igor Rudez, MD, PhD  
Department of Cardiac and Transplant Surgery  
University Hospital Dubrava  
Zagreb, Croatia  
Editor in Chief  
The Heart Surgery Forum

## Wednesday, December 06, 2017

Check in hotel Westin, participants registration, submitting and downloading presentations (on USB stick).

Registration Desk and Speaker-ready-room will be set on the 17th floor of hotel Westin. Details and timetable will follow soon.

---

20.00            **WELCOME COCKTAIL** in hotel Westin

---

## Thursday, December 7, 2017

9.00            **OPENING CEREMONY:**  
**I.R. Rudez and M.L. Levinson**

**M.Klarica:** CELEBRATING 100 YEARS OF MEDICAL SCHOOL, UNIVERSITY OF ZAGREB

---

9.15-9.30        **HONORED GUEST LECTURE: D. Milicic:** ADVANCED HEART FAILURE STATE OF THE ART

---

9.30-11.00      **D. Baric:** WAR OF THE VALVES: NO MAN'S LAND SCOUTING REPORT  
**S. Moten:** THE ROLE OF SUTURELESS AVR 10 YEARS ON. WHO, WHEN, HOW AND WHY  
**M. Solinas:** MINIMALY INVASIVE AVR, FROM NICHE TO ROUTINE

---

11.00-11.30     **COFFEE BREAK**

---

11.30-13.15     **M. Ehrlich:** ACUTE TYPE A DISSECTIONS  
**K-H. Park:** SURGERY FOR CHRONIC AORTIC DISSECTION – A SINGLE SURGEON'S 18 YEARS EXPERIENCE  
**K. Tsagakis:** HOW TO DEAL WITH MALPERFUSION IN ACUTE TYPE I AORTIC DISSECTION  
**D. Unic:** SOMETIMES DOING TOO MUCH DOESN'T GET YOU FAR: ACUTE TYPE A DISSECTION IN A MARFAN PATIENT

---

13.15-14.30     **LUNCH**

---

14.30-16.00     **M. Levinson:** MANAGEMENT OF THE AORTIC ROOT IN ASCENDING DISSECTIONS  
**E. Lansac:** RATIONALE OF AORTIC ANNULOPLASTY TO STANDARDIZE AORTIC VALVE REPAIR  
**I. Rudez:** HOW TO START AORTIC VALVE REPAIR PROGRAM

---

16.00-16.30     **COFFEE BREAK**

---

16.30-18.00     **B. Biocina:** CROSS CORDOPEXY: A NOVEL METHOD IN MITRAL VALVE REPAIR – INTERMEDIATE RESULTS  
**H. Roberts:** CURRENT MANAGEMENT OF POSTOPERATIVE COX-CRYOMAZE  
**T.C. Nguyen:** MINIMALY INVASIVE CONCOMITANT MITRAL AND TRICUSPID SURGERY: PEARLS AND PITFALLS  
**T. Asai:** BUTTERFLY TECHNIQUE AND GEOMETRIC MITRAL VALVE REPAIR

---

20.30            **HSF DINNER**

---

## Friday, December 8, 2017

9.00-10.30	<p><b>T. Asai:</b> A NOVEL REPAIR FOR VENTRICULAR SEPTAL RUPTURE, THE EXTENDED SANDWICH PATCH METHOD</p> <p><b>D. Harris:</b> MULTIVESSEL CABG VIA MINI-THORACOTOMY</p> <p><b>G. Di Giammarco:</b> THE IMPORTANCE OF HIGH RESOLUTION IMAGING DURING CORONARY SURGERY</p> <p><b>L. Ramirez:</b> CARDIAC AND PERIPHERAL VASCULAR COMPLICATIONS OF HEMODIALYSIS ACCESS</p>
10.30-11.00	<b>COFFEE BREAK</b>
11.30-13.15	<p><b>M. Firstenberg:</b> EVOLVING ROLE FOR SURGEONS IN THE MANAGEMENT OF ACUTE CADIOGENIC SHOCK: OPPORTUNITIES FOR MECHANICAL CIRCULATORY SUPPORT</p> <p><b>Z. Sutlic:</b> VENTRICULAR RECOVERY FOLLOWING LVAD IMPLANTATION-EVIVAL OF THE FIELD AND NEW ALOGORITAM FOR LVAD EXPLANTATION</p> <p><b>F.H. Cheema:</b> MECHANICAL CIRCULATORY SUPPORT FOR ADVANCED HEART FAILURE: WHERE WE ARE NOW AND WHAT IS THE FUTURE?</p> <p><b>M. Kutlesa:</b> ECMO IN ARDS</p> <p><b>M. Firstenberg:</b> THE ECONOMICS OF ECLS: MYTH VS REALITY IN THE UNITED STATES</p>
13.15-14.30	<b>LUNCH</b>
14.30-16.00	<p><b>TEA'S PHYLOSOPHY CORNER</b></p> <p><b>T. Acuff:</b> AUTHORITY, LOGIC, STATISTICS, ARTIFICIAL INTELLIGENCE: WHERE SHOULD MEDICINE FIND FUTURE?</p> <p><b>G. Rescigno:</b> EXPERIENCES OF A EUROPEAN SURGEON WORKING IN DIFFERENT NATIONAL ENVIRONMENTS</p>
16.00-16.30	<b>COFFEE BREAK</b>
16.30-18.00	<b>RESIDENTS AND YOUNG SURGEONS SELECTED ABSTRACTS</b>
18.00	<b>AWARD CEREMONY TO THE BEST RESIDENT'S PRESENTATION &amp; FAREWELL COCKTAIL</b>

THURSDAY, DECEMBER 7, 2017

## Selected Abstracts

### NEW RAPID DEPLOYMENT VALVE: PERSONAL AND DEPARTMENT EXPERIENCE

Ricardo Arruda Pereira

HOSPITAL DE SANTA MARIA, LISBON, PORTUGAL

Abstract N/A

### EARLY OUTCOME AFTER MINIMALLY INVASIVE AORTIC VALVE REPLACEMENT WITH A SUTURELESS VALVE THROUGH A RIGHT MINI-THORACOTOMY VERSUS TRANSCATHETER AORTIC VALVE IMPLANTATION AT UNIVERSITY MEDICAL CENTER LJUBLJANA

Tomislav Klokocovnik<sup>1</sup>, Matija Jelenc<sup>1</sup>, Eva Hrovat<sup>1</sup>, Polonca Kogoj<sup>2</sup>, Matjaz Bunc<sup>2</sup>, Nikola Lakić<sup>1</sup>

<sup>1</sup> DEPARTMENT OF CARDIOVASCULAR SURGERY, UNIVERSITY MEDICAL CENTER, LJUBLJANA, SLOVENIA

<sup>2</sup> DEPARTMENT OF CARDIOLOGY, UNIVERSITY MEDICAL CENTER, LJUBLJANA, SLOVENIA

**Objectives:** The aim of the study was to compare the early outcome of patients with severe aortic stenosis undergoing minimally invasive surgical aortic valve replacement through right anterior mini-thoracotomy with sutureless valve (AVR) with patients undergoing transcatheter aortic valve implantation (TAVI).

**Methods:** From June 2014 to August 2017, 223 patients with severe aortic stenosis underwent either AVR (n = 123 patients) or TAVI (n = 100; 79 transfemoral, 14 transapical and 7 transaortic) in our institution. Of these, 43 surgical patients were matched to 43 TAVI patients using propensity score.

**Results:** Baseline characteristics were similar in both groups (mean age 79 ± 8 years, 58% female, mean EuroSCORE II 2.1 ± 1.9%). Thirty-day and 1-year survival rates were 97 vs 95% and 97 vs 83% in patients after AVR and TAVI, respectively (P = 0.21). The incidence of stroke was 2% (n = 1) vs 0% in the AVR and TAVI groups (P = 0.31). The incidence of permanent pacemaker implantation was the same in both groups at 12% (5 patients in each group). There was a trend towards higher incidence of renal failure in the TAVI group 12% (n = 5) vs 2% (n = 1) (P = 0.09). In the TAVI group, 55% (n = 24) had mild paravalvular leak (PVL) and 14% (n = 6) had moderate PVL, whereas 2% (n = 1) had mild PVL in the AVR group (P < 0.001). Post procedural paroxysmal atrial fibrillation was more common after AVR (33% (n = 14) vs 5% (n = 2)) (P = 0.02).

**Conclusions:** Early outcomes after AVR and TAVI are comparable, with much higher rate of paravalvular leakage in the TAVI group and higher rate of postprocedural atrial fibrillation in AVR group.

### PERCEVAL S SUTURELESS AORTIC VALVE IMPLEMENTATION - OUR EXPERIENCE

Gorazd Kosir, Tamara Mohorko, Rene Petrovic, Anze Djordjevic  
UNIVERSITY MEDICAL CENTER MARIBOR, SLOVENIA

**Background:** Surgery on the aortic valve is one of the most common surgeries in cardiac surgery. With the development of sutureless implementation technique the duration of cross-clamp time has decreased significantly. A higher incidence of conduction disturbances, especially left bundle branch block (LBBB), has been reported in comparison to the conventional technique. We aimed to identify predicting factors of new-onset LBBB.

**Methods:** We observed and studied patients who underwent implantation of Perceval S Sutureless bioprosthesis between October 2013 and August 2017. We monitored baseline characteristics, procedural data, and the electrocardiogram (ECG) pre- and postoperatively and compared our data with other similar studies.

**Results:** 32 patients underwent the beforementioned procedure with the mean age of 76,4 ± 4,7 years and mean EuroSCORE II of 3,4% ± 4,2%. Postoperatively 42 % (p=13) of our patients developed a new-onset postoperative left bundle branch block (LBBB), with 64 % of our patients (p=20) having some sort of ECG changes on discharge (atrial fibrillation, atrial undulation, atrioventricular block, LBBB). No patient needed permanent pacemaker implantation. During our study we did not discover any significant relevance between patient characteristic, procedural data and the new-onset of LBBB.

**Conclusion:** We observed a higher incidence of LBBB in patients who underwent the Perceval S sutureless aortic valve implantation at our CENTER in comparison to conventional AVR reported incidence rate in literature. Our results matched the results in different other studies, where similar incidence rates were reported. Compression of the conduction system during prosthesis expansion is thought to be the major mechanism of postoperative conduction disorder. Modification of the procedure can lower the incidence of conducting disturbances with sutureless valve implantation."

### JEHOVAH'S WITNESSES PATIENTS AND CARDIAC SURGERY OUTCOMES - OUR EXPERIENCE

Igor Medved, Salem Osman, Aleksandra Ljubacev

DEPARTMENT OF CARDIAC SURGERY, UNIVERSITY HOSPITAL RIJEKA, RIJEKA, CROATIA

**Introduction:** Jehovah's Witnesses believe that the Bible prohibits ingesting blood and that Christians should not accept blood transfusions or donate or store their own blood for transfusion. The belief is based on an interpretation of scripture that differs from that of other Christian denominations. That is the reason why medical treatment, specially surgical procedures such as cardiac surgery is so challenging for surgeons and anesthesiologist as well; including preoperative preparation, operative procedure alone and postoperative period. Their refusal of blood products faced all medical staff in a difficult position to make decisions which could be in conflict with patient wishes and rights to make decisions about way of treatment on the one hand and ethical and low consequences from the other hand.

**Aim:** To present our experience and outcomes of small group of Jehovah witnesses patients underwent cardiac surgery in our department.

**Methods:** It is retrospective study which includes 7 Jehovah's witnesses patients in period from January 2012 to September 2017. Monitored records include age, gender, preoperative iron level, hemoglobin values in preoperative, early postoperative and discharge period, type of cardiac procedure, postoperative complications and recovery duration including intensive care unit (ICU) days.

**Results:** The mean age was 68, two of the patients (28%) were female and four of them (71%) were male. Mean preoperative iron level was 14,28  $\mu\text{mol/L}$ ; mean preoperative hemoglobin value was 123,71 g/L, first postoperative mean value of hemoglobin was 102,85 and on the discharge day from hospital mean hemoglobin value was 106 g/L.

Two of the patients (28%) underwent combined cardiac procedure; aortic valve replacement with CABG and other one was reoperated due to stenosis of implanted aortic bioprosthesis with aortic valve replacement and mitral valve annuloplasty procedure. On the other five of the patient off pump CABG was done. Average stay in ICU was three days and average postoperative stay in hospital was 6,71 days. Only one of the patients (14%) showed signs of transitory respiratory failure and urine retention and was discharged with urine catheter.

**Conclusion:** According our experience based on small group of patients we found cardiac surgery procedures on Jehovah's witnesses patient could be safe if adequate preoperative preparation, careful surgical technique with detail hemostasis and postoperative management is performed correctly. It is also important to emphasize need for good communication with patient and his family about possible serious even life threatening consequences in case of refusal of blood transfusion. It is even more important in case other family members not sharing patient beliefs and do not belong to Jehovah's witnesses community.

On the other side still remain fact we have not been faced within our group of patients with so dramatic clinical outcome which require blood transfusion treatment and possibility to be in conflict with ethical and legal issues.

## FROZEN ELEPHANT TRUNK WITH E-VITA HYBRID PROSTHESIS: OUR RESULTS

Josip Varvodic, Savica Gjorgijevska, Daniel Unic, Davor Baric, Igor Rudez

DEPARTMENT OF CARDIAC AND TRANSPLANT SURGERY,  
UNIVERSITY HOSPITAL DUBRAVA, ZAGREB, CROATIA

**Introduction:** Elephant trunk is still the golden standard in treating complex aortic pathologies, even though patients require second surgery via thoracotomy. With implementation of frozen elephant trunk, such procedures can be done without need for second operation. We present our initial results of frozen elephant trunk with E-Vita hybrid prosthesis.

**Patients and methods:** From July 2011 to December 2016 we used this procedure in twenty four patients, five female, nineteen male. Average age was  $59 \pm 11$  years with mean logistic EuroSCORE II of 11,65 ( $\pm 8,74$ ), with mean EuroSCORE II of 7,25 ( $\pm 3$ ) in chronic setting, and 15,10 ( $\pm 10,5$ ) in acute setting. We routinely used right

axillary cannulation for cardiopulmonary bypass and bilateral antegrade cerebral perfusion with the left common carotid artery. When target temperature was achieved the stent was deployed and the graft sutured to the proximal aorta with reimplantation of the supraaortic branches starting from the left subclavian artery to the brachiocephalic trunk respectively.

**Results:** Twelve patients (50%) were operated in acute setting, and twelve in chronic setting. Ten patients (42%) underwent isolated E-vita implantation, and fourteen patients underwent concomitant aortic valve or aortic root surgery, and we did mitral and tricuspid valve repair in one patient and coronary artery revascularisation in one patient. Median cooling temp was  $25^\circ\text{C}$  ( $18^\circ\text{C}$ - $28^\circ\text{C}$ ). We mostly used graft size 24, although the range was from 20 to 36. Seven patients (29%) underwent revision due to bleeding, one of who also had TEA of left subclavian artery due to occlusion of the graft. One patient was reoperated for sternal wound infection. One patient had CVI with long term complications, and one with short term complications, also damage of the recurrent nerve was observed in three patients (15%), and resolved in two of these. Three patients (12%) died during short term follow up and two patients (8%) died during long term follow. All patients who died during short term follow up were operated in acute setting.

**Conclusion:** The stented elephant trunk with E-vita is a good alternative for treatment of complex cases of aortic pathology with acceptable surgical risks and satisfactory results especially in elective patients.

## SURGICAL REPAIR OF A PSEUDOANEURISM DUE TO ENDOCARDITIS AFTER A BENTALL PROCEDURE: A CASE REPORT

Humberto Juarez<sup>1</sup>, Alejandro Ramirez<sup>2</sup>, Carlos Dallos<sup>3</sup>, Gerardo Flores<sup>3</sup>

<sup>1</sup> UNIVERSIDAD PONTIFICIA BOLIVARIANA, MEDELLÍN, COLOMBIA

<sup>2</sup> CLINICA EL ROSARIO, MEDELLÍN, COLOMBIA

<sup>3</sup> CLINICA CARDIOVASCULAR DEL CARIBE, CÓRDOBA, COLOMBIA

**Introduction:** Endocarditis and Pseudoaneurism are complications of the Bentall Procedure are associated with an important morbidity and mortality. The following case is of a patient who developed a subclinically endocarditis and a giant pseudoaneurism.

**Case:** A 30 years old male with Annuloaortic ectasia and severe aortic regurgitation and 9 months ago, a Bentall Procedure was performed with a mechanical aortic valve. He developed a superficial wound infection treated with antibiotics and wound caring with excellent evolution. Six months after the procedure, he began with a history of 3 months with right chest pulsations with a decreased of EF from 58 to 43%, with global hypokinesia

Angiotomography reports a giant pseudoaneurism around the ascending aorta with expansion to the right. Echocardiography: reported endocarditis with massive aortic regurgitation. In the initial examen white blood cells were elevated and blood cultures were taken, positive with *Staphylococcus aureus*. It was decided to performed a surgery.

A cardiopulmonary bypass was established with femoral artery and venous cannulation. Cross-clamp before the native aortic arch

### Surgical findings:

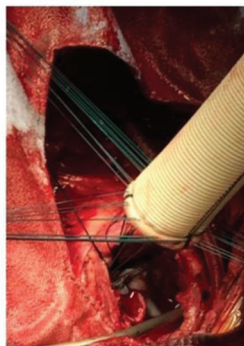
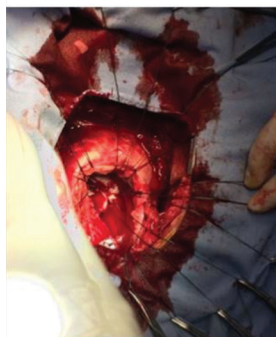– Giant Pseudoaneurism 15 cm around the Ascending Aorta and extension to the right chest

– Free aortic valve inside the pseudoaneurism

A new Bentall Procedures was done with mechanical valve. Perfusion time 200 and Aortic cross-clamp 156 minutes, temperature 32°C.

**Conclusion:** Subclinically endocarditis is a risk factor for developing pseudoaneurism and it can be treated surgically with the proper planning. Peripheral cannulation is an excellent option for this re-do surgery."

### Images during Surgery



#### IMMUNOGLOBULIN G4 - RELATED SCLEROSING DISEASE: A SHORT OVERVIEW AND A CASE PRESENTATION

Robert Blazekovic, Mislav Planinc, Josip Varvodic, Marko Kusurin, Savica Gjorgjievaska, Igor Rudez  
UNIVERSITY HOSPITAL DUBRAVA, DEPARTMENT OF CARDIAC AND TRANSPLANT SURGERY, ZAGREB, CROATIA

The close relationship between immunoglobulin (Ig) G4 and fibrous sclerosing lesions was first reported with regard to sclerosing pancreatitis, also known as autoimmune pancreatitis. Ten years ago an association between disease mentioned above and the cardiovascular system has been reported. We report herein a short overview of the disease and a case of IgG4-related periaortitis of the ascending aorta mimicking intramural hemathoma, which misled us to an emergency surgery.

#### SURGICAL APPROACH TO THORACOABDOMINAL ANEURYSMS - DEVELOPMENT AND IMPLEMENTATION

Ivan Budimir, Andrija Macina Skopljanac, Igor Alfirevic, Zvonimir Ante Korda  
MAGDALENA - CLINIC FOR CARDIOVASCULAR DISEASES OF THE FACULTY OF MEDICINE, J. J. STROSSMAYER UNIVERSITY OF OSIJEK, CROATIA

Thoracoabdominal aneurysm surgical repair generally presents technically most challenging issue in cardiovascular surgery since its introduction in 1950s. Even though it is a condition of an increasing incidence, number of patients treated surgically in Croatia is still low. In our clinic we surgically repair around 6 thoracoabdominal aneurysms every year and there is no reliable data of number of surgically treated patients at national level but grounded on our numbers we suppose there are 20 open surgical repairs of TAAA in Croatia every year. Considering this low patient volume and technical demands of surgical repair it is in our opinion that clinic or department should

create a program and team for treating TAAAs. Our team consists of cardiac surgeon, vascular surgeon, perfusionist and anesthesiologist. Between 2011 and 2016 there were 18 surgically repaired TAAAs at our institution 14 of which were elective while 4 of them were emergency procedures due to rupture of aorta. 12 of 14 electively treated TAAAs were caused by atherosclerosis and 2 were state after Stanford B aortic dissection. Perfusion techniques used were left heart bypass (36%), selective organ perfusion (21%) and in almost half cases (43%) aorta was cross clamped without circulatory support. Reimplantation of intercostal arteries was conducted in 10 of 14 procedures. In this elective series 30-day survival was 93%(13) while acute renal failure, paraplegia and death occurred in 7%(1) each. In emergency treated ruptured TAAAs mortality was 50%. Our elective series is a small sample but treatment results are comparable to those reported by Crawford and Coselli who reported 30-day survival in 92% and 95%, acute renal failure in 9% and 5.6% and spinal cord ischemia in 15.5% and 3.8% but their series were much larger 1509 and 2286 respectively. These results acknowledge that accurately procedure planning and team approach may lead to favorable outcomes even in low volume centers.

#### DEEP HYPOTHERMIC CIRCULATORY ARREST USED IN EXTIRPATION OF RENAL CELL CARCINOMA WITH TUMOR THROMBUS IN INFERIOR VENA CAVA EXTENDING INTO THE RIGHT ATRIUM: CASE REPORT

Aleksandra Ljubacev<sup>1</sup>, Igor Medved<sup>1</sup>, Salem Osman<sup>1</sup>, Goran Popovic<sup>2</sup>, Branka Kurtovic<sup>2</sup>, Noris Buskulic<sup>2</sup>, Danijela Medved<sup>2</sup>, Damir Kurbasic<sup>2</sup>

<sup>1</sup> DEPARTMENT OF CARDIAC SURGERY, UNIVERSITY HOSPITAL RIJEKA, RIJEKA, CROATIA

<sup>2</sup> DEPARTMENT OF CARDIAC SURGERY, CARDIOVASCULAR PERFUSION UNIT, UNIVERSITY HOSPITAL RIJEKA, RIJEKA, CROATIA

**Introduction:** Renal cell carcinoma (RCC) has a tendency to infiltrate venous system and in 4-10% of patients there is a tumor thrombus present in the renal vein and/or inferior vena cava (IVC). In 1% of the patients there is a thrombus extending to the right atrium (RA). These patients are in Mayo class level IV and have a 5-year survival of 47-69%. Radical surgery offers a chance for curative treatment.

**Case report:** Between January 2014 and February 2017 we operated on 7 patients with renal cell carcinoma which infiltrated IVC and RA (3 female, 4 male). In 1 patient tumor thrombus infiltrated contralateral renal vein and left iliac vein. 1 patient had a history of pulmonary embolism, in 3 patients deep vein thrombosis of the lower extremity occurred prior to the diagnosis of RCC.

A single surgical procedure was made with a team of cardiac surgeons and urologists while using cardiopulmonary bypass (CPB) and deep hypothermic circulatory arrest (DHCA) at 18°C.

Radical nephrectomy was made during the cooling period, and extirpation of the tumor thrombi of the IVC and RA was made in DHCA. In 1 patient vena cava filter was also implanted. Mean duration of CPB was 273±21 minutes, and mean duration of DHCA was 48±minutes. There were no major postoperative complications.

Complete remission was observed in 3 patients (at 26, 17 and 8 months after surgery). 4 patients have been diagnosed metastatic

lesions in other organs and were referred to further oncological treatment.

**Conclusion:** Cooperation between cardiac surgeons and urological teams with the help of cardiopulmonary bypass and deep hypothermic circulatory arrest enabled a precise and safe extirpation of primary renal cell carcinoma with its thrombotic lesions in inferior vena cava and right atrium in a single surgical procedure."

#### **AORTIC VALVE REPAIR WITH EXTRAORTIC RING – LANSAC PROCEDURE**

Josip Varvodic, Savica Gjorgijevska, Daniel Unic, Davor Baric, Igor Rudez

DEPARTMENT OF CARDIAC AND TRANSPLANT SURGERY,  
UNIVERSITY HOSPITAL DUBRAVA, ZAGREB, CROATIA

**Objective:** Aortic valve replacement (AVR) is still the most commonly used therapeutic option for patients suffering from AR. Aortic valve repair (AVRep) is an attractive alternative method, since it avoids the risks of prosthesis-related complications. We would like to present our experience with the Yacoub root remodeling, valve sparing technique with the extraortic expansible ring.

**Methods:** Between November 2014 and August 2017, a total of 49 patients (52.1±12.5) years; 18.9% female, EuroScore II of (2.4%±1%) underwent AVRep, 6 due to isolated cusp malcoaptation and 43 with associated with aortic root dilatation. Reconstruction was done with the Coroneo Extraortic Ring (27 (25-31)) and the Gelweave graft (28 (26-32)). Concomitant procedures included MVRRep in three patients with TVRep in two of them, CABG in two patients and replacement of aortic arch and placement of EVITA stent graft in two patients. Echocardiography was used to determine AR severity grade pre-operatively, during immediate post-operative period (within 7 days from operation) and at early follow-up.

**Results:** In postoperative followup no patients died. Freedom from reoperation was 94% (3/37) and there were 2 patients reoperated due to early postoperative regurgitation, and one because of early cardiac tamponade. A significant decrease in LV end-diastolic diameter was observed (LVEDD) (61.3/53.5 mm) with further decrease at early follow-up. At follow up none of the patients had major AR (AR0=40,AR1+=7, AR2+=2).

**Conclusions:** We have proved that AVRep is a good alternative for patients with aortic insufficiency and leads to LV reverse remodeling with comparable results in terms of LVEDD and LVEF immediately post-operatively and at early follow.

#### **AORTIC VALVE REIMPLANTATION PROCEDURE AT UNIVERSITY MEDICAL CENTER LJUBLJANA**

Matija Jelenc, Tomislav Klokocovnik  
DEPARTMENT OF CARDIOVASCULAR SURGERY, UNIVERSITY  
MEDICAL CENTER LJUBLJANA, SLOVENIA

**Background:** At University Medical Center Ljubljana, the first reimplantation procedure was performed in 2006, however active program began in 2012. Most cases were done using the original David I procedure using a straight Dacron graft.

**Methods:** Retrospective analysis of all David procedures done at University Medical Center Ljubljana between January 2012 and August 2017 was performed.

**Results:** We operated 82 patients with mean age 54.9 ± 15.6 years, 67 (82%) were male. The main indication for surgery was root aneurysm in 70 patients (85%) and acute type A aortic dissection in 12 patients (15%). Moderate to severe aortic regurgitation was present in 40 patients (49%), bicuspid aortic valve in 16 patients (20%). In bicuspid valves 14 were Sievers type 1 and 2 Sievers type 0. Leaflet repair was needed in 21 patients (26%). All patients left the operating room with none or mild aortic regurgitation. Revision for bleeding was needed in 8 pts (10%) and 1 pt (1%) needed permanent PM implantation. 5-year survival was 93% (95% CI 85-97). Reoperation was needed in 3 patients because of aortic regurgitation. Freedom from reoperation was 88% at 5 years (95% CI: 65-96%).

**Conclusion:** Reimplantation procedure is safe and effective surgical option for selected patients with reasonable reoperation rate.

#### **CONGENITAL INFUNDIBULAR PULMONARY STENOSIS AS A RISK FACTOR FOR PULMONARY VALVE ENDOCARDITIS IN THE ADULT AGE: CASE REPORT**

Marko Borojevic, Darko Anic, Drazen Belina, Martina Zrno, Ivica Safradin, Bojan Biocina

UNIVERSITY HOSPITAL CENTER ZAGREB, DEPARTMENT OF  
CARDIAC SURGERY, ZAGREB, CROATIA

**Introduction:** Congenital pulmonary valve stenosis has an incidence of 10% among all congenital heart anomalies. Form which occurs with predominantly infundibular pulmonary stenosis is present in less than 10% of patients with mentioned anomaly. Patients with mild and moderate stenosis up to 60mmHg require monitoring and, if necessary, conservative therapy. When the gradient increases above 60mmHg, it is expected that surgical treatment will be performed within ten year interval.

**Case report:** The patient, thirty-six years old female with asymptomatic pulmonary valve stenosis known since childhood was reported to a regional hospital due to the febrile condition with the occurrence of acute renal insufficiency and anemia. Diagnostic procedure established the growth of vegetations on the pulmonary valve with obstruction of right ventricle outflow tract with infundibular pulmonary stenosis. Antibiotic treatment with vancomycin and ciprofloxacin had been initiated. The subsequent course of treatment was complicated by the development of the right side heart decompensation as a consequence of high gradient on a pulmonary valve of 150mmHg with complete disintegration of the valve and the occurrence of massive pulmonary insufficiency. Echocardiography showed the appearance of large vegetations that were registered with the infundibulum and the lateral wall of the pulmonary artery trunk. Chest CT scan showed the existence of septic lung microembolizations. Progression of renal insufficiency has appeared which required hemodialysis. The appearance of respiratory insufficiency required occasional use of non-invasive mechanical ventilation with inhalation of nitrogen monoxide. On the twenty-fourth day of hospitalization, a cardiogenic shock occurrence! due to ventricular fibrillation, she was defibrillated, endotracheally intubated, sedated, and mechanically ventilated. In the

aforementioned condition, in the state of septic shock she was presented to the consultant cardiac surgeon of our institution. In moderate hypothermia with the assistance of cardiopulmonary bypass in cold cardioplegic arrest of the heart the infundibular obstruction of right ventricular outflow tract has been resected and the 24mm pulmonary homograft was implanted. Postoperative hemodynamic stabilization is achieved by the use of dobutamine, adrenaline and levosimendan. The adrenaline was gradually suppressed through the first two postoperative days, followed only by dobutamine support which was abolished after seven days. She was separated from the mechanical ventilation on the third postoperative day. During the first four postoperative days CVVHD was performed, after which the renal filtration function returned. Antimicrobial therapy of vancomycin for staphylococcal endocarditis was performed during 6 weeks and tazobactam with piperacillin for *E. coli* (103) isolated from tracheal aspirates for eight days.

**Conclusion:** Although moderate pulmonary stenosis mostly has asymptomatic course, bacterial endocarditis can occur. Therefore, prevention of bacterial endocarditis represents a mandatory procedure which prevents onset of morbidity and disabilities.

#### THE SINGLE-CENTER ROBOTIC MITRAL VALVE REPAIR EXPERIENCE IN JAPAN

Tatsuya Tarui, Ishikawa Norihiko, Tomita Shigeyuki, Ohtake Hiroshi, Watanabe Go  
NEW HEART WATANABE INSTITUTE, TOKYO, JAPAN

**Background:** Robotic mitral valve repair provides the least-invasive surgical approach. We report the single-center robotic mitral valve repair (rMVP) experience in Japan. Methods: Between May 2014 to August 2017, 87 patients (age:56.1±10.7 ,male59, 68%) underwent a rMVP for severe nonischemic degenerative mitral regurgitation using da Vinci surgical system. Demographic of prolapsed leaflet was, anterior leaflet prolapse in 14 patients, posterior leaflet prolapse in 50 patients, and bileaflet prolapse in 13 patients. All rMVP were done via a 4-5 thoracic ports less than 3cm, trans-thoracic aortic occlusion, and peripheral cardiopulmonary bypass.

**Results:** All patient underwent successful rMVP, and there was no conversion to sternotomy. The procedure for rMVP included, resection suture in 28 cases, artificial neo-chordae by loop technique in 49 cases, leaflet foldoplasty in 13 cases, and edge to edge technique in 14cases. Mean operation time, cardiopulmonary bypass time, and aortic cross clamp time was, 218±60, 131±24, 72±15 minutes, respectively. Transfusion was performed in 15 (17.2%) patients. Mean post operative follow up was 573 days and all patients survived without reoperation. Post-operative echocardiograms showed the following degrees of mitral regurgitation: none 50 (57%), trivial 30 (34%) ,mild 6 (7%), moderate 1 (1%), and severe 0.

**Conclusions:** Safety and efficacy after rMVP were higher than the EVREST II trial and rMVP has an infrequent complications, and a low likelihood of MR recurrence, regardless of mitral valve repair complexity.

#### RIGHT ATRIAL ECHO CONTRAST AND GERBODE TYPE VENTRICULAR SEPTAL DEFECT

Drazen Belina, Mario Pavlek, Zeljko Colak  
UNIVERSITY HOSPITAL CENTER ZAGREB, CROATIA

Spontaneous echo contrast (SEC) can be seen mostly in the left atrium on transesophageal echocardiography (TEE) exam. We will describe a child with the Gerbode type ventricular septal defect (VSD) and atrial septal defect type II (ASD II) with a curious SEC in the right atrium on intraoperative TEE. In Gerbode type VSD left ventricle communicate with the right atrium through tricuspid valve. We speculated that high velocity stream from the left ventricle directly into a low pressure right atrium produced microcavitations or microbubble pattern seen on TEE. The pathophysiology of SEC is not completely clear, but surgical exploration will resolve dilemma at the end.

**FRIDAY, DECEMBER 8, 2017**

### Selected Abstracts

#### DOUBLE-PATCH REPAIR OF POSTINFARCTION POSTERIOR VENTRICULAR SEPTAL DEFECT

Harun Avdagic, Nermir Granov, Bedrudin Banjanovic  
CLINICAL CENTER UNIVERSITY OF SARAJEVO, DEPARTMENT OF CARDIAC SURGERY, BOSNIA and HERZEGOVINA

**Introduction:** Post infarction VSD is a rare complication. Leak free closing of post infarction VSD with as much as possible preservation of ventricular geometry and function is important for early and late outcomes.

**Patient and methods:** We report a case of a 66-year-man with post infarction VSD at posterior location. VSD occur 4 days after myocardial infarction. Coronary Angiography reveal single vessel disease – occluded RCA. We have decided to perform surgery after full stabilization because clinical improvement was evident on conservative treatment. Using double patch technique VSD was closed with Impra patch. Recovery was uneventful and discharge from hospital 11 day after surgery. Follow up was until now, 3 months, with no residual shunt and patient is clinically in good condition.

**Conclusion:** We conclude that using double patch technique for VSD closing assure that there will not be residual shunt, bleeding or sever los of ventricular geometry. Also, if patient start to recover than, it is better to postponed surgery.



## HOW WE MANAGED TO CREATE GRAFTS FOR CORONARY ARTERY BYPASS GRAFTING IN A PORCELAIN PATIENT: A CASE REPORT

Ivan Burcar<sup>1</sup>, Marjan Urlic<sup>1</sup>, Mate Petricevic<sup>1</sup>, Tomislav Kopjar<sup>1</sup>, Stjepan Ivankovic<sup>1</sup>, Ranko Smiljanic<sup>2</sup>, Ana Marija Alduk<sup>2</sup>, Andrea Grman Fanfani<sup>4</sup>, Vjekoslav Radeljic<sup>3</sup>, Sime Manola<sup>3</sup>, Dijana Delic Brkljacic<sup>3</sup>, Hrvoje Gasparovic<sup>1</sup>, Bojan Biocina<sup>1</sup>

<sup>1</sup> UNIVERSITY HOSPITAL CENTER ZAGREB, DEPARTMENT OF CARDIAC SURGERY, ZAGREB, CROATIA

<sup>2</sup> UNIVERSITY HOSPITAL CENTER ZAGREB, DEPARTMENT OF RADIOLOGY, ZAGREB, CROATIA

<sup>3</sup> UNIVERSITY HOSPITAL CENTER ZAGREB „SISTERS OF MERCY“, DEPARTMENT OF RADIOLOGY, ZAGREB, CROATIA

<sup>4</sup> GENERAL HOSPITAL KARLOVAC, DEPARTMENT OF RADIOLOGY, KARLOVAC, CROATIA

**Case presentation:** Sixty-eight years old Caucasian female patient was presented to our center for coronary artery bypass grafting (CABG). Coronarography revealed three vessels coronary disease unsuitable for percutaneous coronary intervention (PCI). Coronarography was unsuccessfully performed via right radial access due to a disease of the innominate artery level and was performed via right femoral access. Multislice Computed Tomographic Angiography revealed subtotal occlusion of the left subclavian artery (LSA). Color doppler (CD) of the arteries of lower extremities showed occlusion of both common femoral arteries, so the veins of the lower extremities were unsuitable for harvesting. Forearm Rtg and CD of the arteries of the left hand showed no calcifications and good flow through radial artery, without stenosis. The only graft harvesting region was LSA irrigation region and the plan was harvesting of the left internal mammary artery (LIMA) and left radial artery (LRA) after performing LSA percutaneous transluminal angioplasty and stenting.

We performed CABGx2 with skeletonized LIMA anastomosed to left anterior descending artery (LAD) and LRA anastomosed to obtuse marginal branch of circumflex artery. LIMA, harvested in skeletonized clip and cut technique fashion had a good flow.

CABG was performed on a beating heart with extracorporeal circulation support. The postoperative period was uneventful. The patient was discharged from the hospital 7th postoperative day with arranged additional PCI of the proximal LAD 2 months after CABG.

**Conclusion:** In this patient we used combination therapy (LSA PTA + surgery) and made porcelain patient operable. 6 weeks after operation patient is doing fine.

## PREPONDERANCE OF POSITIVE MICROBIAL ISOLATES AMONG HEART TRANSPLANTATION RECIPIENTS REQUIRING DIALYSIS: A PROPENSITY SCORE ADJUSTED ANALYSIS

Hrvoje Gasparovic<sup>1</sup>, Lucija Svetina<sup>1</sup>, Filip Loncaric<sup>1</sup>, Jana Ljubas<sup>2</sup>, Maja Cikes<sup>2</sup>, Bojan Biocina<sup>1</sup>, Davor Milicic<sup>2</sup>

<sup>1</sup> UNIVERSITY HOSPITAL CENTER ZAGREB, DEPARTMENT OF CARDIAC SURGERY, ZAGREB, CROATIA

<sup>2</sup> UNIVERSITY HOSPITAL CENTER ZAGREB, DEPARTMENT OF RADIOLOGY, ZAGREB, CROATIA

**Introduction:** Infections are an important source of morbidity and mortality among heart transplantation (HTx) recipients. Understanding the origins and predisposing conditions are critical for improvement of outcomes. Patients requiring renal replacement therapy (RRT) after HTx are particularly susceptible to infections.

**Methods:** All 167 consecutive patients undergoing heart transplantation in a single academic CENTER from January 2008 to December 2016 were screened for analysis. Patients with missing microbial data were excluded (N=9). The remaining 158 patients were dichotomized according to the need for periprocedural RRT. Twenty-seven patients required RRT (17%). Patients requiring postoperative RRT had lower preoperative creatinine clearance (53±21 vs. 62±21 ml/min, P=0.044), greater body mass indices (27±3 vs. 25±5, P=0.014) and were more likely to be diabetic (41% vs. 20%, P=0.026). Propensity score adjustment was used in order to account for multiple covariates (recipient age and gender, organ ischemic time, body mass index, pulmonary vascular resistance, creatinine clearance, duration of cardiopulmonary bypass, diabetes, preoperative and postoperative mechanical circulatory assistance).

**Results:** The incidence of any positive microbial isolates among patients requiring RRT after Htx was significantly higher on unadjusted analysis (25/27 (93%) vs. 95/131 (73%), OR 4.77 [1.01-30.53], P=0.026). Patients requiring RRT had an increased susceptibility to positive microbial isolates from blood cultures (13/26 (50%) vs. 20/90 (22%), OR 3.50 [1.28-9.67], P=0.012). Propensity score adjusted analysis corroborated the significant difference for positive blood cultures (OR 3.97 [1.28-12.32], P=0.017), while the incidence of total microbial isolates was just below the level of statistical significance (OR 4.55 [0.90-23.05], P=0.067).

**Conclusions:** We have shown that patients requiring early RRT following HTx had an increased susceptibility to infections via various portals of entry, predominantly due to an increase in blood borne infections. Understanding the underlying conditions leading to infection-related morbidity is paramount in infection control and prevention

## RESULTS OF HEART TRANSPLANTATION IN PATIENTS REFERRED BY DIVISION OF CARDIOLOGY OF UNIVERSITY HOSPITAL DUBRAVA

Mario Udovicic<sup>1</sup>, Mira Stipcevic<sup>2</sup>, Sandra Jaksic Jurinjak<sup>1</sup>, Vanja Ivanovic<sup>1</sup>, Dubravka Susnjar<sup>3</sup>, Zeljko Sutlic<sup>3</sup>, Igor Rudez<sup>3</sup>, Davor Baric<sup>3</sup>, Daniel Unic<sup>3</sup>, Boris Starcevic<sup>1</sup>

<sup>1</sup> DIVISION OF CARDIOLOGY, DEPARTMENT OF INTERNAL MEDICINE, UNIVERSITY HOSPITAL DUBRAVA, ZAGREB, CROATIA

<sup>2</sup> GENERAL HOSPITAL ZADAR, ZADAR, CROATIA

<sup>3</sup> DEPARTMENT OF CARDIAC AND TRANSPLANT SURGERY, UNIVERSITY HOSPITAL DUBRAVA, ZAGREB, CROATIA

Despite all efforts in conservative medical treatment and the availability of mechanical circulatory support, heart transplantation (HTx) remains the gold standard and treatment of choice for advanced terminal heart failure refractory to other methods.

In this study we report the single center experience and outcomes of patients referred to HTx by Division of Cardiology, University Hospital Dubrava. All patients underwent HTx at the Department of Cardiac and Transplant Surgery of University Hospital Dubrava, and were subsequently referred for follow up in close collaboration of two departments. We retrospectively examined the outcomes from 79 HTx recipients between 1995 and September 2017. The mean recipient age was 54.5±8.0 years, and 87% were male. Dilated cardiomyopathy was present in 51%, ischemic in 43% and 6% were other causes. Twelve recipients (15%) were placed on high urgent list of Eurotransplant. As induction of immunosuppressive therapy antithymocyte globulin was used, while for maintenance we apply the concept of individualized immunosuppression, using combinations of drugs according to patients' needs and occurrence of side effects. Survival was studied using Kaplan-Meier curves. Early in-hospital mortality was 12%. The global survival rates at 1, 5, and 10 years are 83.3%, 78.8% and 70.2% respectively. The mean survival is 135.9 months (95% CI, 116.2-155.7). Early main causes of death were sepsis (44%) and primary graft failure (19%) while late causes were cardiac allograft vasculopathy (13%), malignant disease and other causes (25%). In University Hospital Dubrava, post-HTx survival rates at 1, 5, and 10 years are better than those reported by the International Society of Heart and Lung Transplantation, as a result of careful selection of patients and combined effort of all medical personnel involved in pre-, peri- and postoperative management.

## DIAGNOSIS AND CONTEMPORARY MANAGEMENT OF ACQUIRED VONWILLEBRAND DEFICIENCY IN HEART DISEASE: A REVIEW OF LITERATURE

Mate Petricevic<sup>1</sup>, Jadranka Knezevic<sup>2</sup>, Gordan Samoukovic<sup>3</sup>, Ivica Safradin<sup>1</sup>, Marjan Urlic<sup>1</sup>, Helena Fucek<sup>1</sup>, Hrvoje Gasparovic<sup>1</sup>, Ante Lekic<sup>1</sup>, Bojan Biocina<sup>1</sup>

<sup>1</sup> DEPARTMENT OF CARDIAC SURGERY, UNIVERSITY HOSPITAL CENTER ZAGREB, CROATIA

<sup>2</sup> UNIVERSITY HOSPITAL CENTER MOSTAR ; DIVISION FOR TRANSFUSION AND BLOOD MANAGEMENT, MOSTAR, BOSNIA AND HERZEGOVINA

<sup>3</sup> MCGILL UNIVERSITY, MONTREAL, CANADA

Acquired von Willebrand syndrome (AVWS) in patients with heart disease may be perceived as rare, but in fact, it is underestimated and underdiagnosed leading to increased morbidity and mortality in this patient group.

Among the patients with cardiac disease, AVWS usually occurs either in those with structural heart disease or in those supported with ventricular assist devices (VAD) / extracorporeal life support (ECLS).

AVWS usually manifests as a bleeding diathesis characterized by gastrointestinal or mucocutaneous haemorrhage followed by signs of anemia and impaired hemostasis. The primary hemopathologic change is loss of high-molecular weight von Willebrand factor multimers (HMWM). Whereas the loss of HMWM in patients with structural heart disease is caused by increased HMWM cleavage by VWF -cleaving protease, ADAMTS13, AVWS in mechanical circulatory support (MCS) patients is predominantly a result of mechanical destruction of VWF itself.

Herein we provide comprehensive review of the evidence regarding both diagnosis and contemporary management of AVWS in patients with heart disease.

## PHYSICIAN BURNOUT IN THE U.S.

Ajit Damle<sup>1</sup>, Rachele Damle<sup>2</sup>

<sup>1</sup> TAMPA GENERAL HOSPITAL, TAMPA, FLORIDA, UNITED STATES OF AMERICA

<sup>2</sup> UNIVERSITY OF ST. LOUIS, MISSOURI, UNITED STATES OF AMERICA

Physician burnout in the U.S. is surprisingly high, on average some 30 to 40% physician experience some kind of burnout. Moreover, it is on the rise. The physicians that report it most often are the front-line physicians, working in ER, Ob/Gyn, and internal medicine; surgeons are closer to the average. The four top reasons for burnout are too many administrative tasks, feeling like just a cog in the wheel, long working hours and increasing computerization.

The burnout can affect the quality of care. Considering the high degree of precision and the low safety margin in cardiothoracic cases, combined with long difficult operations, the adverse effects of burnout could be catastrophic for their patients. It is therefore particularly important for cardiac surgeons to maintain a positive outlook.

I will discuss the current surveys on this topic, present tools for self-assessment and therapeutic interventions.

### **BIG BROTHER IS WATCHING YOU! CARDIAC SURGEONS' QUALITY MONITORING IN THE U.S.**

Ajit Damle

TAMPA GENERAL HOSPITAL, TAMPA, FLORIDA, UNITED STATES OF AMERICA

Cardiac surgery was one of the earliest pioneers in outcomes data collection, analyses and reporting. In the US, the payers, primarily the government program Medicare, is increasingly requires surgeons to submit mortality, morbidity and other outcomes data.

Increasingly, these outcomes will result adjusting payments for sub-optimal outcomes. There are similar quality parameters for cardiologists, and even more stringent for hospitals providing cardiac services.

### **SURPRISING DISCOVERIES IN DEPTHS OF HUMAN HEARTS: BLACKNESS AND COLDNESS**

Mislav Planinc<sup>1</sup>, Igor Rudez<sup>1</sup>, Davor Baric<sup>1</sup>, Daniel Unic<sup>1</sup>, Robert Blazekovic<sup>1</sup>, Josip Varvodic<sup>1</sup>, Josip Vincelj<sup>2</sup>, Boris Starcevic<sup>2</sup>, Marko Kusurin<sup>1</sup>, Savica Gjorgijevska<sup>1</sup>, Zeljko Sutlic<sup>1</sup>

<sup>1</sup> DEPARTMENT OF CARDIAC AND TRANSPLANT SURGERY, UNIVERSITY HOSPITAL DUBRAVA, ZAGREB, CROATIA

<sup>2</sup> DEPARTMENT OF CARDIOLOGY, UNIVERSITY HOSPITAL DUBRAVA, ZAGREB, CROATIA

Although infrequent, a surprising surgical finding can occur during regular cardiac surgical procedure. We present altogether four patients with strange findings during open heart surgery. Firstly, two female patients with aortic stenosis who were diagnosed with rare autosomal recessive disorder alkaptonuria during aortic valve replacement by black discoloration of stenotic aortic valve and sternal cartilage. The diagnosis was later confirmed histologically and clinical hallmarks such as dark urine and bluish ear cartilage and sclera were observed. The second case pertain to 60-years-old man with pulmonary valve endocarditis due to a 45 mm long sewing needle entrapped into the right ventricle which was successfully removed along with pulmonary valve replacement and tricuspid valve annuloplasty. The third case is 26-years-old patient with severe aortic valve insufficiency and pseudoaneurysm formation of left coronary sinus presenting two years after aortic valve repair with extraortic ring. The surprising finding was a silicon part of extraortic ring protruding in left sinus of Valsalva which was successfully repaired by pericardial patch along with aortic valve replacement with mechanical valve.

### **COMPARISON OF AORTIC VALVE REPAIR DAVID SURGERY AND BIOLOGICAL BENTALL PROCEDURE WITH ECHOCARDIOGRAPHY FOLLOW-UP AFTER 6 YEAR PRACTICE AT OUR CENTER**

Aleksandra Ljubacev, Igor Medved, Salem Osman

DEPARTMENT OF CARDIAC SURGERY, UNIVERSITY HOSPITAL RIJEKA, RIJEKA, CROATIA

**Objectives:** The aim of this study was to compare two methods for surgical management of aortic regurgitation and aortic root pathology performed in our hospital - aortic valve repair David surgery and Bentall procedure with biological composite graft.

**Methods:** Our analysis included 71 patients that underwent surgery between January 1st 2011 and March 30th 2017. David procedure was done in 37 patients, and 34 patients underwent biological Bentall procedure. All the patients were operated by the same surgical team and received the usual anaesthesia protocol.

**Results:** We observed no statistical significant difference between two groups regarding demographic data, comorbidities, postoperative course of treatment and mortality. The cardiopulmonary bypass time and aortic cross clamp time were significantly longer for David procedure group, with  $p=0.05$  and  $0.01$  respectively, but the duration of surgery for David procedure did not reach statistical significance compared to Bentall surgery group.

Mortality after David procedure was 2.70% (1 patient), and 2.94% (1 patient) after Bentall surgery.

Follow-up echocardiography was made yearly after David surgery. The majority of patients had no aortic regurgitation at follow-up (80.55% at 1 year, 62.85% at 2 years, 58.06% at 3 years, 47.82% at 4 years, 47.36% at 5 years). Grade 1 aortic regurgitation was observed in 11.11% of patients at 1 year, 28.57% at 2 years, 34.48% at 3 years, 43.47% at 4 years, 36.84% at 5 years. Grade 2 aortic regurgitation was present in 5.55% of patients at 1 year, 8.57% at 2 years, 6.45% at 3 years, 8.69% at 4 years, 15.78% after 5 years.

Reoperation was done in one patient with bicuspid aortopathy (2.70%) in David procedure group due to severe aortic regurgitation.

**Conclusion:** Aortic valve repair David surgery is well-established and complementary method to biological Bentall procedure considering early postoperative morbidity, mortality and follow-up echocardiography.

## REPAIR OF ATRIAL SEPTAL DEFECT DUE TO PENETRATING TRAUMA, A CASE REPORT

Humberto Juarez<sup>1</sup>, Lucas J. Ramirez<sup>2</sup>, Carlos Dallos<sup>2</sup>, Gerardo Flores<sup>2</sup>

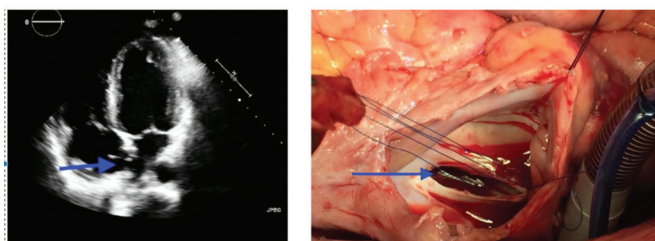
<sup>1</sup> UNIVERSIDAD PONTIFICIA BOLIVARIANA, MEDELLÍN, COLOMBIA

<sup>2</sup> HOSPITAL GENERAL DE MEDELLÍN, COLOMBIA

**Introduction:** The cardiac trauma represents the second place in mortality, after the severe cranioencephalic trauma. The cardiac penetrating wounds in the majority of cases have an elevated mortality; almost all patients die in the place where the trauma takes place. There are only a few cases of traumatic atrial defects reported in the literature, all of them are due to blunt trauma.

**Case summary:** A 27 year old male with traumatic atrial septal heart defect secondary due to penetrating wound. In the emergency room had hypotension and was delivered to operating room. He had multiple wounds: diaphragm, right lung and a bleeding on the inferior cavoatrial junction. He was managed initially with damage control surgery. After the initial surgery, he was diagnosed with traumatic atrial septal defect. The septal defect was repaired in cardiopulmonary bypass with an autologous pericardial patch.

**Conclusions:** Damage control surgery is the best option in an unstable patient with trauma, the repair of traumatic septal cardiac defects can be performed with autologous pericardial



Blue arrows showing atrial septal defect in echo and during surgery; respectively

## LEFT VENTRICULAR PSEUDOANEURYSM FOLLOWING ATRIOVENTRICULAR GROOVE RUPTURE AFTER MITRAL VALVE REPLACEMENT

Anze Djordjevic<sup>1</sup>, Miha Antonic<sup>1</sup>, Rene Petrovic<sup>1</sup>, Robert Lipovec<sup>2</sup>, Peter Juric<sup>1</sup>

<sup>1</sup> UNIVERSITY MEDICAL CENTER MARIBOR, SLOVENIA

<sup>2</sup> KLINIKUM KLAGENFURT AM WÖRTHERSEE, KLAGENFURT, AUSTRIA

Left ventricular (LV) pseudoaneurysm is a partial cardiac rupture, contained by surrounding pericardium that maintains communication with the LV lumen. Whereas most cases of LV pseudoaneurysms are associated with myocardial infarction (loss of myocardial integrity), only a handful is associated with valve surgery. It has been estimated that a significant LV pseudoaneurysm occurs in 0.8% of cases after mitral valve replacement (MVR). We present a female patient, who was admitted for elective MVR. After the implantation of a mechanical valve, we encountered a rupture of

the atrioventricular groove. Having repaired the rupture with a pericardial patch, weaning from the cardiopulmonary bypass was uneventful. After three months, a LV pseudoaneurysm was identified and the patient was re-operated. The valve was explanted and the inspection of the annulus and previously implanted pericardial patch revealed a loosened stitch on the inferior (ventricular) side. The defect was reinforced with additional stitches and the valve was re-implanted. An intraoperative trans-oesophageal echocardiography showed that the connection between the pseudoaneurysm and the left ventricle was closed. In conclusion, we report an unusual case with two serious complications after MVR - atrioventricular groove rupture and LV pseudoaneurysm with a high risk for spontaneous rupture. Although valve removal and intra-ventricular rupture repair is associated with high mortality (65% to 100%), we successfully repaired the LV pseudoaneurysm with excellent post-operative results.

## THE ASSOCIATION BETWEEN TIMING OF PREOPERATIVE CLOPIDOGREL DISCONTINUATION, PLATELETS REACTIVITY AND BLEEDING COMPLICATIONS IN PATIENTS UNDERGOING CORONARY ARTERY BYPASS GRAFTING

Mate Petricevic<sup>1</sup>, Bojan Biocina<sup>1</sup>, Ivica Safradin<sup>1</sup>, Marjan Urlic<sup>1</sup>, Helena Fucek<sup>1</sup>, Ante Rotim<sup>2</sup>, Hrvoje Gasparovic<sup>1</sup>, Jadranka Knezevic<sup>3</sup>, Klaus Goerlinger<sup>4</sup>

<sup>1</sup> DEPARTMENT OF CARDIAC SURGERY, UNIVERSITY HOSPITAL CENTER ZAGREB, CROATIA

<sup>2</sup> SCHOOL OF MEDICINE, UNIVERSITY OF RIJEKA, RIJEKA, CROATIA

<sup>3</sup> UNIVERSITY HOSPITAL CENTER MOSTAR ; DIVISION FOR TRANSFUSION AND BLOOD MANAGEMENT, MOSTAR, BOSNIA AND HERZEGOVINA

<sup>4</sup> UNIVERSITY DUISBURG ESSEN ; UHC ESSEN ; TEM INTERNATIONAL GMBH, GERMANY

**Objectives:** The purpose of the study was to determine how does the timing of preoperative clopidogrel discontinuation influence bleeding complications and transfusion requirements in patients undergoing coronary artery bypass grafting (CABG) and whether the preoperative platelet function testing may provide clinically relevant information regarding the risk of bleeding complications.

**Methods:** The study was designed as retrospective analysis of prospectively collected data. With regard to the period between preoperative clopidogrel cessation and surgery, patients undergoing CABG were divided into three groups: Group 1 (n=94, clopidogrel discontinued in ≤3 days before surgery); Group 2 (n=100, clopidogrel discontinued in 4-5 days before surgery) and Group 3 (n=83, clopidogrel discontinued in 6-7 days before surgery). Impedance aggregometry with drug specific platelet function assays (ASPItest sensitive to aspirin and ADPtest sensitive to clopidogrel) were performed in all cases just before the surgery. 24h chest tube output (CTO) was considered as primary outcome, whereas transfusion requirements were considered as secondary outcomes.

**Results:** A total number of 277 patients exposed to clopidogrel within 7 days of CABG were enrolled in the study. Group 1 patients were found to have a significantly higher amount of 24h CTO

(Median ml/kg 11.04 (7.80-17.64)) relative to those in group 2 (Median ml/kg 9.51 (6.87-13.00)) and group 3 (Median ml/kg 8.11 (6.74-12.00)), respectively ( $p=0.003$ ). Group 1 patients experienced more frequently both excessive bleeding ( $p=0.013$ ) and reexplorations for excessive bleeding ( $p=0.045$ ) relative to patients in groups 2 and 3, respectively. Group 1 patients were also more frequently transfused and if transfused, significantly higher amount of transfusion requirements was also noted relative to patients in groups 2 and 3. Multiple electrode aggregometry ASPI and ADP tests significantly correlated to 24h CTO (ASPI test –  $r= -0.258$ ,  $p<0.001$  ; ADP test –  $r= -0.164$ ,  $p=0.007$ ). A significant correlation was observed between clopidogrel free interval and 24h CTO ( $r= -0.200$ ,  $p<0.001$ ). Receiver operating curve (ROC) analysis revealed cut-of values to delineate bleeding tendency (ASPI test  $\leq 25$  AUC, ADP test  $\leq 63$  AUC and clopidogrel free interval  $\leq 3$  days). The number of parameters found to be below the cut-off values, as defined by ROC analysis, reflected bleeding amount and transfusion requirements. Different combinations of the parameters being below or above the cut-of value yielded different OR's for excessive bleeding (Figure 1 and Table 1). Interestingly, the OR for excessive bleeding was calculated to be 0.25 (0.05 - 0.85) in cases with clopidogrel free interval  $\leq 3$  days, ADP test  $\leq 63$  AUC but sufficient residual platelet reactivity in aspirin sensitive test (ASPI test  $> 25$  AUC).

**Conclusion:** Bleeding complications and transfusion requirements occur less frequently after 3 days of waiting period following clopidogrel cessation. The shortening of the waiting period after clopidogrel discontinuation (even shorter than 3 days) may be considered if coupled with adequate platelet reactivity. Platelet function testing may shift preoperative antiplatelet drugs management towards personalized approach."

#### ACUTE PULMONARY THROMBOEMBOLISM AND CONCOMITANT LEFT ATRIAL MYXOMA: A CASE REPORT

Humberto Juarez<sup>1</sup>, Alejandro Ramirez<sup>2</sup>, Camilo J. Jaramillo<sup>2</sup>

<sup>1</sup> UNIVERSIDAD PONTIFICIA BOLIVARIANA, MEDELLÍN, COLOMBIA

<sup>2</sup> CLINICA EL ROSARIO, MEDELLÍN, COLOMBIA

**Introduction:** Cardiac myxoma is the most prevalent cardiac tumor, the most common location is left atrium. The myxoma can produce lysis of red blood cells due to turbulent flow, this phenomenon can enhance coagulation. There are few cases of left atrial myxoma and concomitant pulmonary thromboembolism without communication between left and right cavities.

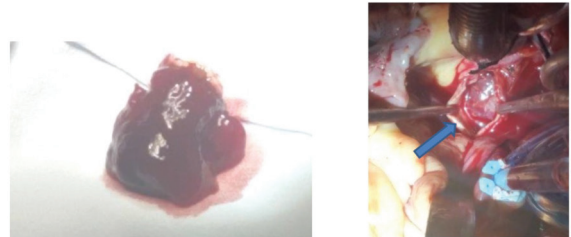
**Case:** A 57 years old male active smoker, with: acute chest pain, wheezing and desaturation was diagnosed with acute pulmonary embolism and deep venous thrombosis. Echocardiogram reported a left atrial mass lying at atrial septum of 2 cms without septal defects. A venous cava filter was deployed before surgery. A cardiopulmonary bypass was established with the bicaval conventional cannulation.

with reconstruction of the right pulmonary artery with bovine pericardium patch and the atrial septum defect. Perfusion time was 88 minutes and Aortic cross-clamp 103 minutes. Three days

after the surgery the patient was weaned off the ventilator and ten days was discharged home.

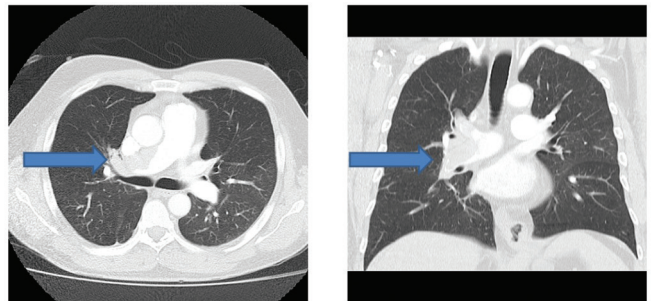
**Conclusions:** Patients with Cardiac Myxoma are in risk of developing Deep venous thrombosis. In patients with small left atrium transeptal approach is an excellent alternative. A pericardial patch to close Right pulmonary artery is a good choice, to avoid arterial stenosis.

H. JUAREZ photo ACUTE PULMONARY THROMBOEMBOLISM AND CONCOMITANT LEFT ATRIAL MYXOMA, A CASE REPORT



Left image: left atrial myxoma. Right Image: blue arrow showing thrombus in right pulmonary artery.

H. JUAREZ photo ACUTE PULMONARY THROMBOEMBOLISM AND CONCOMITANT LEFT ATRIAL MYXOMA, A CASE REPORT



Blue arrows showing right pulmonary thrombus

#### EARLY VALVE SURGERY SIGNIFICANTLY REDUCES PERIOPERATIVE MORTALITY IN INFECTIVE ENDOCARDITIS – 22 YEARS EXPERIENCE

Marko Kusunin<sup>1</sup>, Igor Rudez<sup>1</sup>, Zeljko Sutlic<sup>1</sup>, Davor Baric<sup>1</sup>, Daniel Unic<sup>1</sup>, Robert Blazekovic<sup>1</sup>, Mislav Planinc<sup>1</sup>, Josip Varvodic<sup>1</sup>, Savica Gjorgijevska<sup>1</sup>, Marko Kutlesa<sup>2</sup>, Vladimir Krajinovic<sup>2</sup>, Bruno Barsic<sup>2</sup>

<sup>1</sup> DEPARTMENT OF CARDIAC AND TRANSPLANT SURGERY, UNIVERSITY HOSPITAL DUBRAVA, ZAGREB, CROATIA

<sup>2</sup> UNIVERSITY HOSPITAL FOR INFECTIOUS DISEASES „DR. FRAN MIHALJEVIC“, ZAGREB, CROATIA

**Background:** Acute infective endocarditis is associated with high morbidity and mortality, and optimal timing of surgical treatment in current guidelines is still unclear. We performed retrospective analysis to compare early valve surgery with postponed surgery after full 6 weeks course of antibiotics to 30 day in hospital mortality.

**Methods:** From Jan 1995 to Sept 2017, 224 patients were operated because of IE in our institution. Late valve surgery was considered standard treatment for IE in a period from 1995 to 2007, but after comprehensive review of literature early valve surgery

treatment was decided by consensus of a multidisciplinary team made by cardiac surgeons and infective disease specialists. Late valve surgery was defined as replacement or repair of infected valve after the resolution of the infection to reduce the risk of operation and of relapse of IE. Early valve surgery was introduced to reduce the risk of embolization, progressive deterioration of cardiac function, which can result in more difficult repair, progressive cardiogenic shock and organ failure, thus increased mortality.

**Results:** Total of 224 patients in a period from 1995 to 2017 was eligible for analysis. Overall 65 (29,1%) vs 179 (79.9 %) patients underwent late valve surgery (LVS) vs early valve surgery (EVS), respectively. Average logistic mortality was 16.4%, EuroSCORE II 7.77% for patients underwent LVS vs 18.3%, EuroSCORE II 9.32% for patients in EVS group. Total in hospital mortality was 28/244 (11,47%). In EVS group, we observed significantly lower mortality vs LVS group, 16/179 (8,67%) vs 12/65 (18,46%), P .038, respectively.

**Conclusion:** The results of this retrospective analysis suggests that compared with conventional treatment with the completion of a full therapeutic course of antibiotics, early surgical intervention is associated with significantly lower risk of in hospital mortality in patients with acute infective endocarditis. Our observations are accordant with 2015 ESC Guidelines for the management of infective endocarditis.

#### ASPIRIN SENSITIVE PLATELET FUNCTION ASSESSED PREOPERATIVELY BY MULTIPLATE® AND ROTEM PLATELET® WHOLE BLOOD IMPEDANCE AGGREGOMETERS IN PATIENTS UNDERGOING ELECTIVE CARDIAC SURGERY

Mate Petricevic<sup>1</sup>, Bojan Biocina<sup>1</sup>, Daniel Dirkmann<sup>2</sup>, Ivica Safradin<sup>1</sup>, Marjan Urlic<sup>1</sup>, Sanja Konosic<sup>3</sup>, Vasil Papestiev<sup>1</sup>, Tomislav Madzar<sup>4</sup>, Ante Rotim<sup>5</sup>, Klaus Goerlinger<sup>6</sup>

<sup>1</sup> DEPARTMENT OF CARDIAC SURGERY, UNIVERSITY HOSPITAL CENTER ZAGREB, CROATIA

<sup>2</sup> DEPARTMENT OF ANESTHESIOLOGY AND INTENSIVE MEDICINE ; UNIVERSITY OF DUISBURG - ESSEN ; UHC ESSEN, GERMANY

<sup>3</sup> DEPARTMENT OF ANESTHESIOLOGY AND INTENSIVE CARE, UNIVERSITY HOSPITAL CENTER ZAGREB, CROATIA

<sup>4</sup> SCHOOL OF MEDICINE, UNIVERSITY OF OSIJEK

<sup>5</sup> SCHOOL OF MEDICINE, UNIVERSITY OF RIJEKA

<sup>6</sup> DEPARTMENT OF ANESTHESIOLOGY AND INTENSIVE MEDICINE ; UNIVERSITY OF DUISBURG - ESSEN ; UHC ESSEN - GERMANY ; AND TEM INTERNATIONAL GMBH, MUNICH, GERMANY

**Objectives:** A substantial proportion of patients have inadequate platelet inhibitory response to Aspirin treatment. In this study, we evaluated Aspirin resistance (AR) preoperatively and its relation to bleeding and transfusion outcomes, using two whole blood impedance aggregometers: 1) Multiplate® and 2) ROTEM Platelet.

**Methods:** Prospective observational study consecutively enrolled patients undergoing elective cardiac surgery. Based on previously published Multiplate® ASPI test cut-off value of AUC $\geq$ 30 AUC

defining AR, we divided cohort into the two subgroups: 1) Aspirin sensitive - AS (ASPI test <30 AUC) and 2) Aspirin resistant - AR (ASPI test  $\geq$ 30 AUC) patients. Patient subgroups were compared with respect to transfusion requirements and bleeding outcomes.

**Results:** Study cohort was consisted of 71 patients. Multiplate® ASPI test was performed preoperatively in all patients whereas ROTEM Platelet® was performed in 34 patients. According to the Multiplate® ASPI test, 44 out of 71 patients were found to be AS preoperatively, whereas 27 patients were found to be AR. AS patients were more frequently under dual antiplatelet regime (18.2% vs 3.7%). AS patients had a higher 24 hours chest tube output (12.2 (9.3) vs. 9.4 (7.9) ml/kg, p=0.049) relative to AR patients. AS patients were transfused with higher amount of packed red blood cells (1005 (790.5) ml vs. 578.9 (931.1), p=0.004). ARAtem test was performed at 34 patients, of which, 24 were AS and 10 patients were AR. ARAtem test paralleled ASPI test with higher values observed in AR patients (57.5 (46.25-70.25 [6-97] vs. 35.5 (8-45[0-70])).

**Conclusion:** Platelet inhibitory response to Aspirin therapy reflects both bleeding and transfusion outcomes. Those findings revise the current recommendations on preoperative Aspirin discontinuation management by generating the hypothesis about the subset of patients with pronounced platelet inhibitory response to Aspirin who could benefit from preoperative Aspirin discontinuation.

#### NEW SILENT BRAIN ISCHEMIC LESIONS AFTER CORONARY ARTERY BYPASS GRAFTING ARE ASSOCIATED WITH POSTOPERATIVE NEUROCOGNITIVE DECLINE

Tomislav Kopjar<sup>1</sup>, Hrvoje Gasparovic<sup>1</sup>, Milan Rados<sup>4</sup>, Alan Anticevic<sup>3</sup>, Marko Radoš<sup>2</sup>, Branko Malojcic<sup>5</sup>, Visnja Ivancan<sup>6</sup>, Tea Fabijanic<sup>1</sup>, Maja Cikes<sup>7</sup>, Davor Milicic<sup>7</sup>, Vladimir Gasparovic<sup>8</sup>, Bojan Biocina<sup>1</sup>

<sup>1</sup> UNIVERSITY HOSPITAL CENTER ZAGREB, DEPARTMENT OF CARDIAC SURGERY, ZAGREB, CROATIA

<sup>2</sup> CROATIAN INSTITUTE FOR BRAIN RESEARCH, UNIVERSITY OF ZAGREB, ZAGREB, CROATIA

<sup>3</sup> DEPARTMENTS OF PSYCHIATRY AND PSYCHOLOGY, YALE UNIVERSITY SCHOOL OF MEDICINE, NEW HAVEN, USA

<sup>4</sup> DEPARTMENT OF RADIOLOGY, UNIVERSITY HOSPITAL CENTER ZAGREB, CROATIA

<sup>5</sup> DEPARTMENT OF NEUROLOGY, UNIVERSITY HOSPITAL CENTER ZAGREB, CROATIA

<sup>6</sup> DEPARTMENT OF ANAESTHESIOLOGY, UNIVERSITY HOSPITAL CENTER ZAGREB, UNIVERSITY HOSPITAL CENTER ZAGREB, CROATIA

<sup>7</sup> DEPARTMENT OF CARDIOVASCULAR DISEASES, UNIVERSITY HOSPITAL CENTER ZAGREB, CROATIA

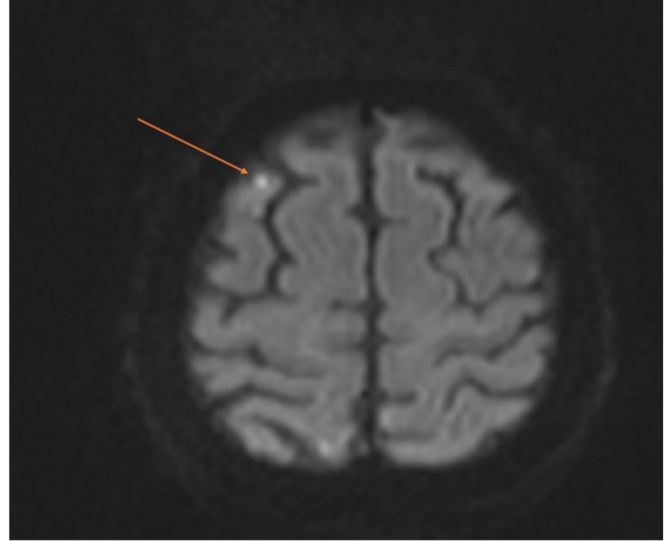
<sup>8</sup> DEPARTMENT OF INTERNAL MEDICINE, UNIVERSITY HOSPITAL CENTER ZAGREB, CROATIA

**Introduction:** The potential of magnetic resonance imaging (MRI) to detect clinically silent brain injury has been clearly recognized. We hypothesized that new clinically silent ischemic events following coronary artery bypass grafting (CABG) employing cardiopulmonary bypass could be associated with postoperative neurocognitive decline.

**Methods:** This is a post hoc analysis of the Impact of remote ischemic preconditioning preceding coronary artery bypass grafting on inducing neuroprotection (RIPCAGE) trial (NCT02177981). Patients were dichotomized depending on the presence or absence of new ischemic events on postoperative structural brain (MRI). Postoperative neurocognitive decline was defined as a decrease of at least one standard deviation in at least two components of neurocognitive testing. Neurocognitive testing consisted of the Montreal Cognitive Assessment (MoCA), Trail Making A and Trail Making B Test (TMT A and B). Per protocol paired neurocognitive and brain MRI data were acquired preoperatively and on postoperative day 7. Comparisons were performed using the Fisher's exact test and two-sided P values.

**Results:** Out of the 70 patients included in the trial, 84% (59/70) had undergone paired neurocognitive assessment and brain MRI. Twenty % (12/59) of patients had new silent brain ischemic lesions on postoperative MRI, without clear clinical signs of stroke. There is a borderline statistically significant difference in postoperative neurocognitive decline among patients with and without new brain ischemic lesions (25% (3/12) vs. 4% (2/47),  $P=0.052$ ). No difference was observed in the decline for the MoCA test (33% (4/12) vs. 17% (8/47),  $P=0.24$ ). Statistically significant difference in the decline for the TMT A (33% (4/12) vs. 9% (4/47),  $P=0.046$ ) and the TMT B (17% (2/12) vs. 0% (0/47),  $P=0.039$ ) were observed.

**Conclusions:** New, clinically silent, ischemic brain lesions after CABG are frequently detected on brain MRI. These, silent ischemic lesions on postoperative brain MRI are associated with postoperative neurocognitive decline.



**Figure.** Postoperative structural brain magnetic resonance imaging of a patient in the RIPCAGE trial with a new subcortical vascular lesion about 3 mm in diameter in the right middle frontal gyrus, not visible preoperatively. A fluid attenuated inversion recovery diffusion-weighted imaging sequences were used to detect new ischemic brain injury.