

# Chapter XIV

## **Clinical application of laser in oncological neurosurgery**

Josip Paladino and Goran Mrak

*Zagreb University School of Medicine*

*Department of Neurosurgery, Clinical Hospital Centre, Zagreb*

Today laser has become a standard tool in modern minimal invasive microneurosurgery and it is being increasingly used in functional neurosurgery as well. Lasers have found their full and extensive application for their capacity of acting on pathological tissues without direct contact, through relatively small craniotomy, and in deep hardly accessible regions. In accordance with worldwide experience in successful use of laser power in neurosurgical procedures, in 1986 laser instruments were introduced into clinical practice at University School of Medicine, Department of Neurosurgery, at Clinical Hospital Centre in Zagreb.

Following the initial efficiency testing of Neodymium: Yttrium Aluminium Garnet (Nd:YAG) laser equipment on experimental animals, its application soon began in neurosurgical procedures, to be continued on a regular basis until the present day. The Nd:YAG laser, which causes coagulation-necrosis resulting in good hemostasis, has proved highly valuable tool in the surgery of copiously vascularised pathological processes. Its deep thermal effects (up to 5 mm in depth) make it practically irreplaceable in surgeries where particularisation and extensive shrinkage of solid tumour is desirable at the highest possible radicality, and especially in pigmented and hemopigmented tissues, like for instance angioblastic meningiomas, hemangioma, glomus tumour, and a number of blood vessel malformations. At the same time, a relatively small absorption of electromagnetic waves in water enables the use of Nd:YAG laser in CSF spaces, for instance, in intraventricular tumours, cysts of septum pellucidum, etc.

Successful use of Nd:YAG laser has encouraged us to purchase the Carbon Dioxide (CO<sub>2</sub>) laser instrument in 1991 for its wide application in almost all types of neurosurgical procedures, but first of all in the extirpation of solid tumours in vital brain areas and base of the skull in order to avoid damages to differential neural and vascular formations. Thermal effect by vaporisation of pathologically altered tissues in small volumes has proved appropriate in ablation of tumours located in hardly accessible cranial regions, e.g. in meningioma of the base of the skull, Schwannoma of vestibulocochlear nerve, and other tumours in ponto-cerebellar angle, and in trans-sphenoidal surgeries of tumours of the hypophysis and clivus (chordoma). For its very small penetration range (up to one-tenth of a millimeter), the CO<sub>2</sub> laser is particularly useful in precise excisions of tumour tissue in dif-

ferential nerve and vascular structures. Although the CO<sub>2</sub> laser is not characterised by coagulation property, it adequately seals superficial capillary vessels in small tissue surfaces and enables almost bloodless removal of many tumours and avascular tumour capsules. The advantage of such a surgery lies in the possibility of direct removal of tumour tissue through small space and minimal contact with the surrounding tissues and retraction of blood vessels and nerve structures; it is the so-called non-manipulative or no touch technique that significantly decreases the risk of additional neurological disorders.

Eventually, the purchase of new Sharplan micromanipulator attached to surgical microscope made it possible to precisely direct the laser beams and to integrate the valuable properties of both laser instruments, i.e. the devascularisation of tumour by Nd:YAG laser and its evaporation and ablation by CO<sub>2</sub> laser.

The use of laser at our Clinic was significantly improved in 1987 through procurement of Cavitron Ultrasonic Surgical Aspirator (CUSA), the instrument that by longitudinal vibrations crushes the tumour tissue at simultaneous irrigation and suction of particles through the tip of its probe. The tumour is destroyed without moving and producing damaging effects on the surrounding tissues, while the studies have shown that no changes occur in neural conductivity 1 mm outside the US aspirator operating field. In this way it is possible to operate quickly even the tumours of solid consistency - meningiomas, craniopharyngeomas, Schwannomas, gliomas, after which follows laser dissection of tumour capsule and eventual establishment of hemostasis.

We would like to add here that in the past ten years in preventing thermal injuries to differential regions, the electrophysiological monitoring, i.e. registration of evoked potentials, regularly included in everyday surgical activities has been of great help.

The reference literature reports and our experience indicate that laser power can be efficiently used first of all in the surgery of intracranial tumours. However, the technique of choice depends on tumour histology and location. The advantage of CO<sub>2</sub> laser is in its vaporisation of tissue in thin superficial layer only, enabling thus precise control over its action and preservation of the surrounding structures. Opposite to that, the Nd:YAG beam penetrates deep into tissues leading to coagulation or cutting effect followed by extraction of tumour tissue, depending on its structure, by CUSA or standard neurosurgical techniques. Of course, great caution is needed here, particularly when dealing with the base of the skull or the brain stem, for there is great risk of damaging the vascular and neural structures deep inside. Hence the Nd:YAG laser beam must always be directed vertically against the tumour surface in order for its power to be absorbed within the tumour, while special attention should be paid to intense cooling of the operation area.

The use of laser in tumour surgery has advantages often in terms of mere approaching the tumours through a relatively limited craniotomy centred above the accessible tumour area, although, unfortunately, it is not always possible. Also, the approach through arachnoidal spaces is made easier with the sparing of extra-tumour blood vessels and the surrounding structures. Laser enables opening of tumour capsule in the area without nerve or vascular structures, and intracapsular removal of tumour tissue by evaporation and/or morcellation, where the Nd:YAG laser should also be used. During this procedure, by evaporation and/or coagulation of vascular pedicles and attachments, first the tumour is devitalised, then defocused power is applied to shrink the tumour capsule, protecting the surrounding structures by cotton pledgets.

Devascularisation of tumour pedicle often significantly contributes to shrinkage and decrease in blood supply reducing thus the liquid content in the tumour and making evaporation more efficient. Upon opening of tumour capsule the decreased and defocused laser power gradual-

ly cylindrically, or completely, evaporates the tumour tissue intracapsularly. The modification of laser beam depends on the type and biophysical tumour reactivity, often significantly influenced by collagen concentration in tumour capsule.

The mainstay of tumour surgery has remained CO<sub>2</sub> laser because of its immediate absorption in water and minimal scatter, while other wavelengths have been used adjunctively. The more sensitive the area, the more fibrous the attachment; the more firm the consistency, the better the CO<sub>2</sub> laser will function. Fatty tumours are particularly well vaporized because of the differential heat of melting of fat as opposed to neural tissue. In addition, the melted fat assumes a very low temperature because of energy absorption and will not cause further damage.

The neodymium Nd:YAG laser is most valuable in the devascularization of extra-axial tumours before their vaporization or morcellation with CO<sub>2</sub>. The maximal thermal conversion occurs beneath the surface. This has been used in denaturing tissue beyond an intact structure, such as the dura of the sella or the superior sagittal and transverse sinuses. Because of this gradient in temperature elevation, however, an intratumour explosion the "pop corn effect" can occur.

The primary use of the Nd:YAG laser is in the devascularization of the particularly bloody (richly vascularised) neoplasms, both in their centre and at their vascular pedicle. This assumes that the vascular pedicle is not adherent to, or immediately adjacent to, sensitive and functioning neural structures.

This zone of reversibly altered metabolism, was demonstrated by histology, the extension of damage, presumably thermal, to tissue beyond the margins of change, widens the effective zone for YAG damage. This must be considered when using the laser anywhere near the interface between tumour and normal structures. It is contraindicated to employ the YAG wavelength near the mid-brain, the floor of the fourth ventricle, and the cranial nerves. The heat sink effect of tissue is compromised when Nd:YAG is used. The elevated temperature dissipates more slowly and temperature build-up is common. The applications of energy must therefore be of relatively short duration and moderate power. This becomes more critical in dealing with tumours located in more sensitive areas.

## Meningeomas

The majority of meningeomas that are well circumscribed with regard to the surrounding structures can be successfully removed by laser. However, the surgical technique and use of laser greatly depend on the site of the tumour. Here follows description of the most common examples.

Meningeomas in the convexities of brain hemispheres are most commonly attached to the dura mater by wide base and usually reach significant size prior to their being manifested and diagnosed. By circumferential incision in the dura mater and the arachnoid one near the very attachment of the tumour it gets isolated from the surrounding structures. The defocused CO<sub>2</sub> high energy laser beam (80 Watts) is applied to the isolated part of the dura resulting in the shrinkage of underlying tumour segment and initial dislocation from its site. Small cortical blood vessels are identified, coagulated, and ligated. The surrounding cortex is carefully protected by humid cotton pledgets, the defocused laser is used to prepare the tumour surface in depth, and the tumour tissue is gradually evaporated. In this way the surgical entry space is free so that the focused laser power enables morcellation of tumour without retraction of the surrounding brain tissues and small risk of bleeding from the damaged blood vessels deep in the tumour. The use of laser is particularly valuable in surgical treatment of tumours extensively adhering to the brain cortex.

**Parasagittal meningeomas** always affect part of the falx of cerebrum, and sometimes also the

sagittal sinus and bony roof.

In parasagittal meningiomas the defocused high energy laser beam makes it possible to reduce the tumour tissue laterally from the sagittal sinus. However, the vicinity of sagittal sinus requires maximum caution for the risk of damaging greater blood vessels, which would lead to profuse bleeding, while retraction of the ends of the severed blood vessel produces additional difficulty in providing for hemostasis. Hence at this stage of the operation it is appropriate to use the Nd:YAG laser for coagulation of tumour, either by tangential application of laser beam, or by direct contact. Sometimes it is even possible to completely fulgurate the tumour tissue without damaging the walls of sagittal sinus.

Meningiomas of the falx cerebri can be removed by focused laser beam following the same procedure as in parasagittal meningiomas, but without causing greater trauma to the surrounding tissues. Finally, the CO<sub>2</sub> laser vaporisation is used to remove small residues of the tumour adhering to brain tissue.

**Meningiomas of the orbital roof and in the olfactory region** of the anterior cranial fossa are abundantly supplied with blood vessels that reach the tumour from the region of the cranial base. A high power focused laser beam (80 Watts) can significantly debulk the tumour and evaporate the attachment of the tumour up to the healthy bone. The laser beam may further be used as precise dissector of great arterial branches in the region.

**Meningiomas in the lateral region of the wing of the sphenoid bone** are removed in the way similar to that described for meningiomas in the convexities of brain hemispheres, but extreme caution is needed in terms of identifying blood vessels that reach the base of the tumour through the openings of sphenoid wings. Therefore Nd:YAG laser is recommended for use in the base region, so that CO<sub>2</sub> or Nd:YAG laser may be used in combination to remove the tumour masses and to "sterilise" the tumour attachment to bone.

**Meningiomas in the medial sphenoid region** (tuberculum sellae, jugum sphenoidale<sup>1</sup>, medial part of the wing of sphenoid bone) are highly demanding tumours from a surgical point of view, since the region contains very important vascular (internal carotid arteries with branches, cavernous sinus) and nerve structures (optic nerve and optic chiasma, bulbomotor nerves). As these tumours are profusely vascularised by arterial branches of the anterior Willis' ring segment, they often affect greater branches of anterior cerebral artery, or are in contact with the interior carotid and ophthalmic arteries, with the optic nerve and the optic chiasma.

These are the reasons why the tumour should be approached with extreme caution, during which laser is helpful, particularly when passing through arachnoidal spaces. The opening of the optic and chiasmatic cisterns loosens the cerebrospinal fluid with decompression and provides for appropriate operational space. During this procedure the arachnoid should present and be gradually separated from the tumour tissue by humid cotton pledgets or Surgicel, while the olfactory and optic nerve should be protected medially and inferomedially respectively. Special attention should then be given to lateral base of the temporal lobe and blood vessels in the lateral Sylvius' sulcus (sulcus lateralis cerebri - lateral cerebral sulcus), and medial cavernous sinus. During initial evaporation and devascularisation of the tumour the defocused CO<sub>2</sub> laser beam is used to enter deep into the tumour, which simultaneously contributes to its detachment from the surrounding structures. The beam

---

<sup>1</sup> The new Anatomical International Terminology (1998) gives the term jugum sphenoidale (sphenoid yoke) in exchange for the old term planum sphenoidale (1935)

should be directed from the bottom laterally, and care should be taken not to protrude into the cavernous sinus, while mediosuperiorly the damages of the interior carotid artery and/or optic nerve should be avoided.

The defocused CO<sub>2</sub> small energy laser beam may evaporate the tumour up to the lateral wall of cavernous sinus, whereas the possibility of its shrinkage and (or complete removal depends on the degree to which the carotid artery is surrounded by tumour tissue and on the patient's clinical status and age. The experience also shows that, for instance in meningiomas in the tuberculum sellae, laser can be successfully used in the region of optic chiasma, and even the dural attachment at the entry into the optic canal may be evaporated without damaging the optic nerve when constant cooling is applied as prevention.

Blood vessels approaching the tumour from the base of the skull and sphenoid wing, supplying it anteriorly and inferiorly, may be severed by Nd:YAG laser, although a number of authors warn about great risk of Nd:YAG laser application in suprasellar region for the danger of thermal energy spreading into the optic canal. Here only the tumour attachment and the dura mater may be evaporated by the use of laser up the healthy bone without retraction and hazard to the surrounding tissues, and only when careful protection against thermal effect is being applied.

**Meningiomas in the posterior cranial fossa** most commonly develop in the highly differential regions because of the surrounding vital structures which they may coalesce with, which sometimes makes their eradication impossible.

Meningiomas of the tentorium of cerebellum mostly tend to spread supratentorially, while in the incisure of the tentorium they may coalesce with the major blood vessels (basilar artery, posterior cerebral artery, cerebellar superior artery, Labbé's superficial cerebral vein, transverse sinus), and even with parts of the mesencephalon and pons.

Meningiomas in the clivus and foramen magnum regions are rare tumour sites and the possibilities of their removal depend on the specificity of anatomical relations. A small power defocused CO<sub>2</sub> laser is used to achieve shrinkage of the tumour capsule and initial internal decompression by layers enabling the dissection of the tumour from the surrounding tissues, vascular and nerve structures, and its maximal reduction. In this procedure it is of utmost importance to carefully protect and cool the operation site at constant monitoring of evoked potentials.

In the transtentorial approach to clival meningioma the CO<sub>2</sub> laser is an appropriate tool for incision into the dura mater without damaging the dorsal temporal cortex and the cerebellum. In clival meningiomas the use of defocused CO<sub>2</sub> laser enables successful "sterilisation" of tumour attachment to bone. Unfortunately, in radical extirpation of the tumour it is sometimes necessary to "sacrifice" the nerves in jugular foramen (e.g. the accessory nerve).

Meningiomas in the convexity of cerebellar hemispheres are successfully surgically treated by laser and the techniques are similar to those used for meningiomas in the convexity of cerebral hemispheres.

In the course of ten years 841 patients with meningiomas in different locations were operated by CO<sub>2</sub> and Nd:YAG lasers at our Clinic. A number of most interesting cases are presented in the paper.

A female patient aged 67 was admitted to regional hospital following epileptic seizure (grand mal) and with left-sided hemiparesis. CT scan of the neurocranium showed two intracranial tumours: the greater one was located FP to the right, and the smaller one parasagittally occipitally to the left (Fig 1). In the first act the greater meningioma was removed. Following circular incision of

the dura above the tumour origin in the dura convexity, the 60 Watt power CO<sub>2</sub> laser was used to shrink the dura, enabling slow dislocation of the tumour from its site. The application of defocused laser on the tumour enabled its further shrinkage and slow detachment from the surrounding brain structures wedged in with individual tumour lobules. Some parts of the tumour did not have distinct arachnoidal layer and they were detached from the brain by radiation energy reduced to 15 Watts in combination with bipolar coagulation. Eventually the tumour was completely removed. Subsequently, in the second act the parasagittal meningeoma was removed; it was detached by CO<sub>2</sub> laser with coagulation of its attachment to the falx and sinus of the sagittal wall by defocused laser beam. The histopathological diagnosis of convexity tumour was atypical meningeoma, and classical meningeoma for the parasagittal tumour (WHO - grade I).

1. A female patient aged 67 was admitted to regional hospital following epileptic seizure (grand mal) and with left-sided hemiparesis. CT scan of the neurocranium showed two intracranial tumours: the greater one was located FP to the right, and the smaller one parasagittally occipitally to the left (Fig 1). In the first act the greater meningeoma was removed. Following circular incision of the dura above the tumour origin in the dura convexity, the 60 Watt power CO<sub>2</sub> laser was used to shrink the dura, enabling slow dislocation of the tumour from its site. The application of defocused laser on the tumour enabled its further shrinkage and slow detachment from the surrounding brain structures wedged in with individual tumour lobules. Some parts of the tumour did not have distinct arachnoidal layer and they were detached from the brain by radiation energy reduced to 15 Watts in combination with bipolar coagulation. Eventually the tumour was completely removed. Subsequently, in the second act the parasagittal meningeoma was removed; it was detached by CO<sub>2</sub> laser with coagulation of its attachment to the falx and sinus of the sagittal wall by defocused laser beam. The histopathological diagnosis of convexity tumour was atypical meningeoma, and classical meningeoma for the parasagittal tumour (WHO - grade I).

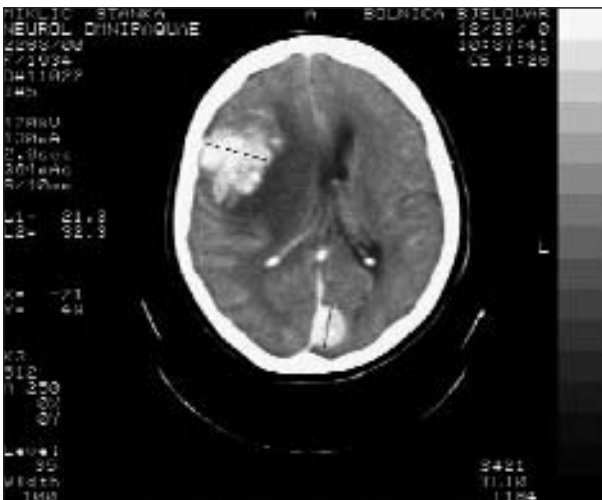

Fig. 1: CT scan of the patient with convexity and parasagittal tumours.

2. A female patient aged 62 three months prior to admission to hospital noticed headaches, diplopia with paresis of the oculomotor nerve, and neuralgic pain in the region of the 2<sup>nd</sup> branch of trigeminus nerve in the right side (Fig2). The surgical approach was through the pterion on the right side. The intracranial whitish scarcely vascularised meningeoma was found. The 30 Watt defocused CO<sub>2</sub> laser beam was used to remove the entire intracranial part of the tumour with "sterilisation" of its origin in the lateral wall and roof of the cavernous sinus. Histopathological finding proved clas-

sical meningioma. Upon surgical reduction of the tumour the patient was referred to radiation therapy.

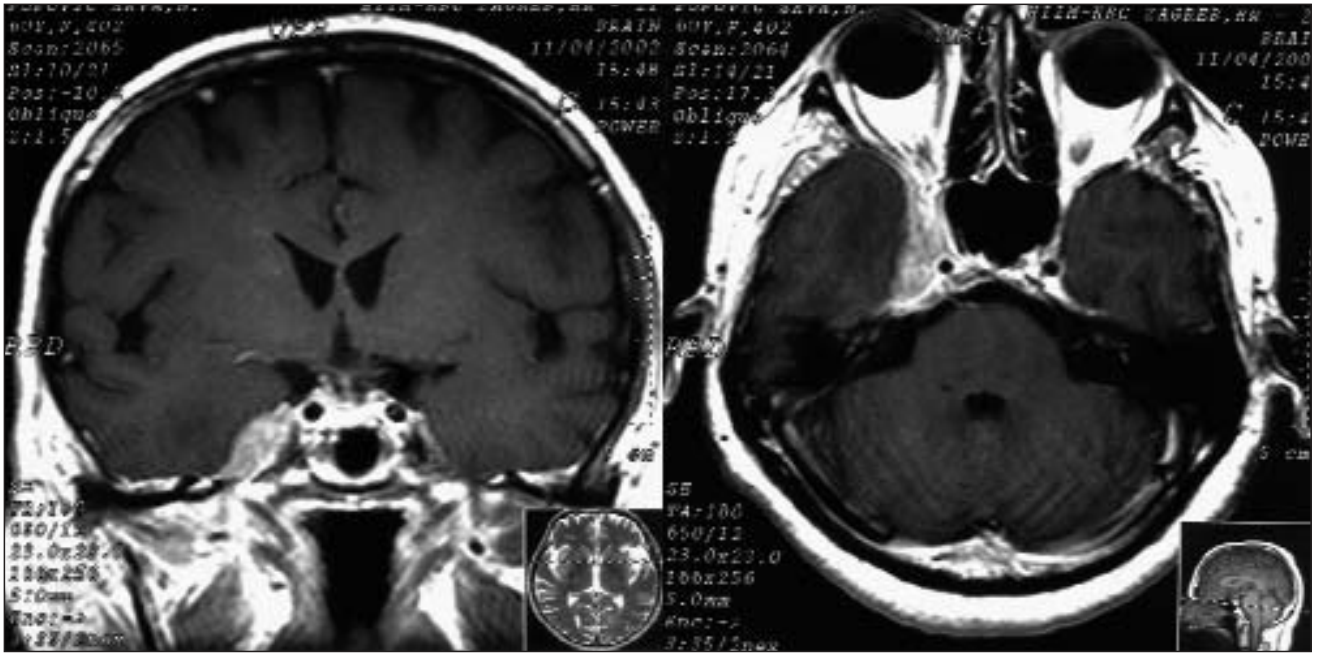


Fig. 2: The patient with meningioma of the right cavernous sinus.

3. A female patient aged 41 years and 6 months noticed gradual and progressive deterioration of vision in the left eye and sporadic headaches prior to hospitalisation. After MRI scan the patient was submitted to surgery (Fig3). Through supraorbital and subfrontal approach meningioma was found in the tuberculum sellae region; it was protruding into the right optic canal, extending and pushing the optic nerve upward and sidewise. Due to its soft consistency the greater segment of the tumour was removed by CUSA. The optic nerve was also exposed through intradural approach and since the tumour had its origin also in the dura of the optic canal, the "sterilisation" of its attachment was made by low energy (5 Watts) CO<sub>2</sub> laser focused beam. After the surgery no deterioration of neurological status was observed, while the check-ups during two following years showed no recurrence of the tumour growth.

4. A 36-year-old female patient several months ago noticed tinnitus in the left ear, while some time afterwards vertigo, ataxia and paresthesia in the left side of the face developed (Fig 4). Retromastoid craniotomy was performed in lateral position and relatively scarcely vascularised but solid meningioma was found with its origin in the junction between tentorium and the pyramid. The focused 20 Watt CO<sub>2</sub> laser beam was used to gradually devascularise the tumour in its attachment. With regard to its size, the intra-tumour shrinkage of its softer parts was performed by CUSA, while the solid parts were removed by defocused 50 Watt CO<sub>2</sub> laser. In this way the tumour was caved in and its detachment in the arachnoidal layer enabled. Eventually, additional "sterilisation" of the tumour origin was performed in the tentorium and the pyramid. No complications were observed in the post-operative course.

## Glial tumours

Modern neurosurgical approach to gliomas depends first of all on histopathological diagnosis, biological properties, and site of the tumour. It is regular practice at our Clinic first to obtain histopathological diagnosis by stereotactic biopsy and, whenever possible, to completely remove superficial tumours. When tumours are located in frontal, temporal or occipital pole of the hemispheres they are removed by lobectomy, whereas tumours located more deeply are treated by microsurgical techniques. The use of laser in the treatment of gliomas reduces contacts with and damages to the surrounding tissues and structures, so that it is sometimes possible to fully respect the neurosurgical rule of "maximal reduction of tumour without progression of neurological deficit".

Evaporation of tumour tissues causes gradual caving in and debulking of tumours resulting in greater space for surgical approach, often even without retraction and mechanical action upon the surrounding structures. Simultaneous protection of the operation site by humid cotton pledgets and its cooling with physiological saline prevent thermal injuries to the surrounding structures. Therefore, the use of laser micromanipulator under operation microscope and monitoring of evoked potentials make it possible to operate on deeply located gliomas in the hypothalamic and base of the brain regions almost atraumatically.

Thermal effect of CO<sub>2</sub> laser in the newly vascularised zone is useful to detachment of tumour tissue from infiltrated but intact brain tissues since it enables shrinking of newly vascularised tissue, which often opens the plane of cleavage toward the infiltrated brain parenchyma. The experience of the surgeon, careful preoperative preparation and critical selection of the technique together with precise operating procedure are of utmost importance here. Further advantage of laser use in glioma

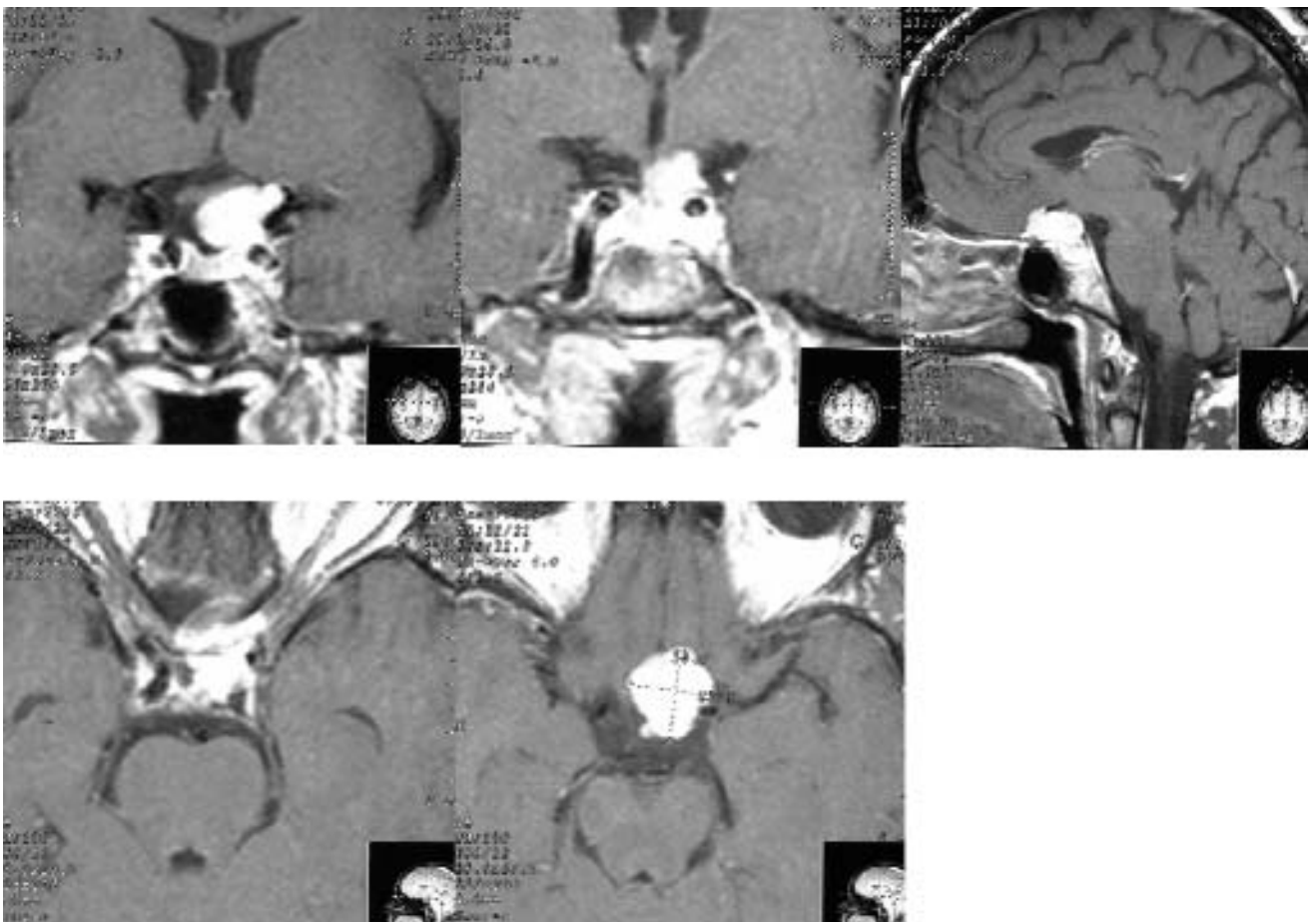


Fig. 3: The patient with meningeoma in the region of tuberculum sellae and optic canal.



surgery, in spite of relatively small improvement of hemostasis, lies in good final hemostasis at minimal use of hemostatic material (Surgicel), that may otherwise cause ambiguity in the interpretation of neuroradiological test results.

**Astrocytomas** of the first and second group are regularly soft in consistency and scarcely vascularised so that evaporation of tumour tissue by CO<sub>2</sub> laser in single stages of the operation enables precision at work and relatively rapid hemostasis. Gradual removal of tumour by layers provides for the plane of cleavage practically without touching the surrounding structures. Upon the procedure, there remains a small cavity lined inside by a layer of coagulated cells within which in two or three weeks there occurs minimal glial reaction. Hence the control CT scans regularly show clearly circumscribed cavity filled with cerebrospinal fluid that collapses with time and is sometimes almost unnoticeable although always retained, so that glial changes in the cavity borders may be helpful in later differential diagnosis of the possible recurrences.

**Oligodendrogliomas** are of more solid consistency than astrocytomas, although the use of CO<sub>2</sub> laser is often appropriate in their treatment. Because of their light and sound effects, the use of laser for calcifications that oligodendrogliomas are characterised by, may sometimes even prior to histopathological verification indicate the nature of the tumour.

**Malignant gliomas (glioblastomas)** usually need the use of CO<sub>2</sub> and Nd:YAG lasers in combination; solid tumour parts are evaporated by CO<sub>2</sub> laser and bipolar coagulation, while copiously vascularised tumour tissue can be removed by Nd:YAG laser at a more rapid and appropriate hemostasis at the end of the procedure. Sometimes the cavity occurring upon tumour removal need not be lined with hemostatic material (Surgicel).

**Medulloblastomas**, that are almost always soft in consistency, are suckable by CUSA. The tumour borders, however, should be removed by precise use of CO<sub>2</sub> laser together with tumour attachments in the base of the fourth ventricle (crura cerebri, aqueduct of mesencephalon). Complete removal of tumour tissue improves the prognosis of radiation treatment, while in children it enables the reduction of radiation doses applied to the entire brain.

**Ependymomas**, commonly occurring with cystic parts within the tumour mass, are quite suitable for laser application, especially ependymomas in the posterior cranial fossa. The cystic part of the tumour may be fenestrated and cystic content removed by suction, although already during tumour reduction procedure its "capsule" is gradually detached from the surrounding tissues. In the attachment area of ependymoma to the wall of the cerebral ventricle, where there is no clear border between the healthy and pathological tissue, the small power (5 Watts) CO<sub>2</sub> laser is used to evaporate the tumour tissue, that usually does reach deep into the brain tissue. It is particularly important

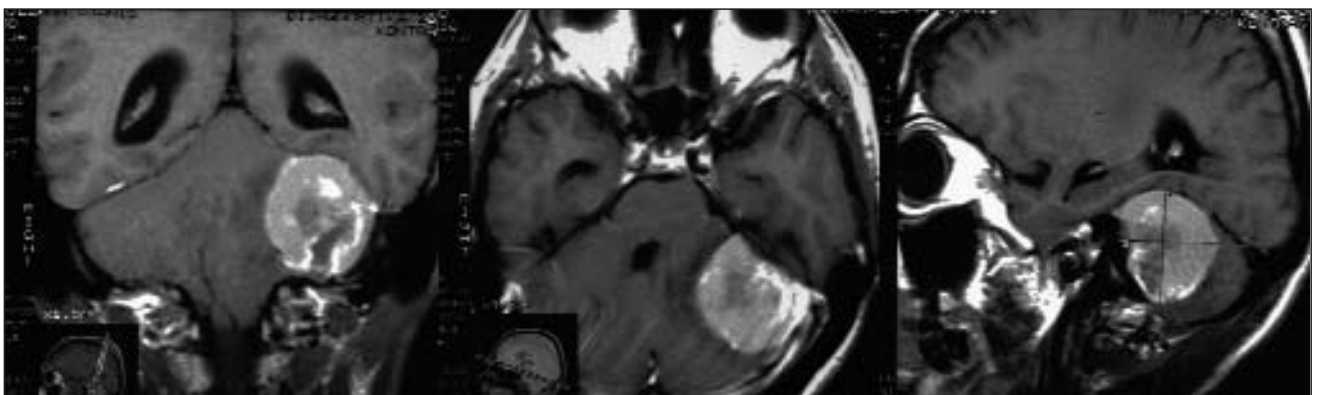


Fig. 4: The patient with meningeoma in the left pontocerebellar angle.

when operating on ependymomas in the base of the fourth brain ventricle, since highly differential and vital structures are located there. As these tumours are usually copiously vascularised and often attached to the base of the fourth ventricle, their attachments should be identified and "sterilised" by CO<sub>2</sub> laser. Ependymomas protruding through the Luschka's aperture and into the cerebello-pontine angle can also successfully be removed by laser, while their attachments to vascular structures and cranial nerves are evaporated. It should be emphasised that the use of Nd:YAG laser in these surgical procedures is a "vitium artis", for reasons of its deep penetration into tissues and risk of damaging vital structures in the brain stem.

During the past fifteen years a great number of gliomal tumours were treated at our Clinic by using the laser beam technology both in macro and microsurgical procedures. Owing to adequate equipment and proper manipulation there have occurred no intra-operative incidents so far, nor have there been recorded any significant damages to blood vessels and brain structures in the surrounding regions that might be attributed to the use of laser technique.

Here follows an instructive example:

1. In a female patient aged 16, accompanied by headaches and sporadic vomiting, disorders of consciousness ranging to somnolence began to appear. During infancy, she was diagnosed with tuberous sclerosis and symptomatic epilepsy. In the course of her later life the patient was followed-up neuroradiologically; the CT scans of endocranium showed subependymal periventricular calcifications combined with smaller tumour impressing into the left lateral ventricle. Following clinical deterioration MRI scans were made showing the increase of the previously visible tumour with the closing of inter-ventricular foramen and obstructive hydrocephalus (Fig 5). Frontal craniotomy was performed above the coronary suture, and, as the tumour was soft in consistency, upon opening of the lateral ventricle its major segment was removed by ultrasonic cavitron probe. The lateral and bottom tumour segments adhering to ventricular wall and inter-ventricular aperture were gradually removed by hand piece of Nd:YAG laser; complete hemostasis was achieved upon completion of tumour reduction and CSF communication established through inter-ventricular aperture. The post-operative CT showed satisfactory recovery; histopathological diagnosis was: astrocytoma subependymale and gigantocellulare (gigantic cell subependymal astrocytoma)(Fig 6).

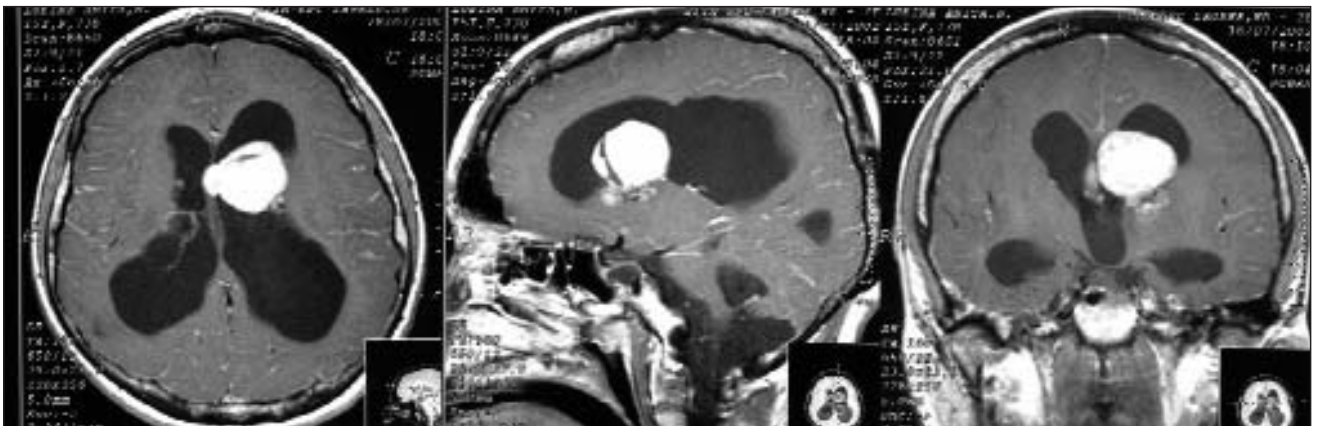

Fig. 5: The patient with astrocytoma subependymale and gigantocellulare

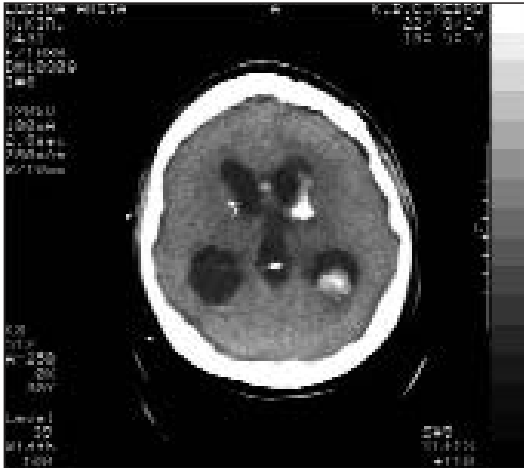

Fig. 6. Post-operative CT scan showing the extent of tumour resection.

### Tumours of the sellar and para sellar region

Sella turcica is the most common site of hypophyseal tumours, and the most appropriate surgical procedure for the removal of these deeply seated neoplasms is by laser technique. The use of CO<sub>2</sub> laser enables successful removal of richly vascularised and/or fibrous tumours at decreased bleeding and maintaining the operation field dry. Recurring tumours, especially if previously irradiated, are also difficult to remove by any other neurosurgical technique, whereas laser helps in differentiating the tissue layers and preparing the laser operation field. The scar tissue can be evaporated and/or coagulated by small power (1 to 5 Watts) laser without any risk. However, maximum caution is needed when operating with small power laser beam if the tumour has affected the diaphragm of sella, internal carotid artery and/or optic nerve and cavernous sinus.

**In trans-sphenoid approach** it is attempted to desiccate the sellar floor by 10 Watt defocused CO<sub>2</sub> laser prior to opening of the sella turcica, preventing thus profuse bone bleeding. In reference literature many authors report that the 40 Watt defocused CO<sub>2</sub> laser beam is used to perform the fenestration of anterior bony wall of sella turcica, or that 5 Watt defocused laser beam is used to evaporate the sellar floor without causing damaging thermal absorption into the surrounding tissues. Then the 1 Watt defocused laser beam is used to coagulate smaller blood vessels in sella turcica that provide copious blood supply to the periosteum. Coagulation of vascular structures in the periosteum of anterior sellar wall can sometimes be achieved by Nd:YAG laser supplied with additional piece for cooling by fluid. Then the periosteum is incised by focused laser beam and tumour approached.

Hypophyseal adenomas are always soft tumours and can be evaporated in layers, while alternating focus and laser beams can successfully remove by coagulation and evaporation fibrotically changed and even calcified tumour masses (eg. in repeated surgery or upon radiation treatment of the tumour) without endangering healthy tissue. Hence the use of laser today is a routine procedure in surgery of soft and necrotic adenomas and microadenomas of the hypophysis.

Craniopharyngiomas, chordomas, and intrasellar tumours, together with their adhering capsules, can be detached with great precision from the surrounding blood vessels, and sometimes even from optic nerve, by trans-sphenoidal approach using reduced laser power (2 to 5 Watts), but at constant cooling by irrigation,

**During transcranial procedures** a highly differential area is entered where tumours often adhere to the internal carotid artery, optic nerve and/or optic chiasma, or have even protruded into

the cavernous sinus. The use of small power defocused CO<sub>2</sub> laser beam often enables evaporation and coagulation of minute tumour residues that could not be removed microsurgically. An experienced surgeon may even use a small power laser in the optic chiasma region, but, of course, at constant cooling by irrigation. Moreover, a number of neurosurgeons recommend the use of Nd:YAG laser transmurally at constant irrigation by cold saline. Yet, one should bear in mind the risk of transmural damage to the internal carotid artery and cranial nerves.

All of the above stated concerning surgery of hypophyseal tumours reaching suprasellarly and/or into the parasellar region equally applies to meningiomas, particularly those adhering to the carotid artery and/or optic chiasma. In these procedures a special mirror is sometimes used by which the laser beams are reflected into tumour segments that are otherwise inaccessible directly.

At our Clinic the trans-sphenoidal surgeries of hypophyseal tumours are unimaginable without the use of laser, and 211 patients were surgically treated in a 10-year period. In trans-cranial surgeries of tumours in parasellar and sellar region laser was regularly used in 379 patients.

### **Tumors of the pontocerebellar angle**

Tumours occurring in the region of pontocerebellar angle are most often the Schwannomas of the cochlear nerve and meningiomas of the pyramid of petrous bone. Laser is used to equal extent in surgical treatment of all these tumours. The solid tumours with strongly developed stroma are treated by CO<sub>2</sub> laser, whereas the copiously vascularised tumours may, prior to being evaporated, also be treated by Nd:YAG laser for coagulation purposes. The modern equipment today enables combined use of both types of laser beams, while CUSA is of great assistance in these surgeries as well. Nevertheless, it should be pointed out that the use of Nd:YAG laser is contraindicated when operating in close proximity to the brain stem and cranial nerves.

Upon opening of the dura mater the arachnoid is dissected and the tumour capsule opened from the posterior side as there are no vascular and nerve structures there. Then follows gradual evaporation and/or morcellation of tumour tissue by CO<sub>2</sub> laser; when the majority of tumour tissue is removed, the tumour "capsule" is being treated in terms of its shrinkage. In this way the bulk of essential structures of the whole tumour is reduced at constant monitoring of arachnoidal layer and maximal protection by cotton pledgets and Sugicel. The Nd:YAG laser enables devascularisation in the centre of bloody tumours and in their vascular pedicle, if not adhering to functional nerve structures.

During the procedure special care should be taken of spaces in the medial tumour side toward the brain stem and cerebellum, the trigeminal nerve above the tumour, and other cranial nerves in the inferior side. Dissection of the lower medial tumour segment is very difficult because of close proximity of the facial and cochlear nerves together with vascular structures, for instance the choroidal plexus. Hence, complete, and not piecemeal (in fragments), reduction of tumour capsule should be attempted at.

Eventually, the CO<sub>2</sub> laser enables resolution of tumour adhesions with the surrounding structures and vaporisation of tumour attachment to the dura mater, even the bony layers up to the healthy bone, causing relatively minor damages to the surrounding structures.

### **Intraventricular tumours**

Intraventricular tumours are situated in deep regions of the brain, and the introduction of relatively bulky instruments, such as CUSA, into these regions is quite difficult. The use of laser is

therefore the most appropriate method in the treatment of intraventricular tumours since the tumour tissue can be successfully evaporated by CO<sub>2</sub> laser, while, whenever necessary, the Nd:YAG laser can be readily used for coagulation and even evaporation processes. Laser is also a valuable tool in partial dissection of corpus callosum when approaching the third brain ventricle, in the opening of cyst of the septum pellucidum, and also in dissection of the cerebellar vermis when approaching tumours in the fourth brain ventricle.

Great caution is needed, however, when using laser in lower portions of the third brain ventricle and in the rhomboid fossa in the fourth brain ventricle because of the surrounding neural and vascular structures. Yet, the use of micromanipulator and proper cooling of the operating site enables surgery in these areas to be atraumatic to the surrounding brain tissues. Constant electrophysiological monitoring, i.e. permanent follow-up of evoked potentials during surgery, is of great help in preventing damages to the surrounding structures in these highly differential regions.

Here follows an instructive example:

In a three-year-old girl the disease was marked by sudden onset of instability in standing position and in walking. MRI scan revealed intraventricular tumour (Fig 7). Upon PO craniotomy the choroid plexus papilloma was found. Considering its good vascularisation the Nd:YAG laser was used for gradual shrinkage of the tumour and simultaneous hemostasis. Eventually, by cutting off its vascular pedicle the tumour was completely removed (Fig 8).

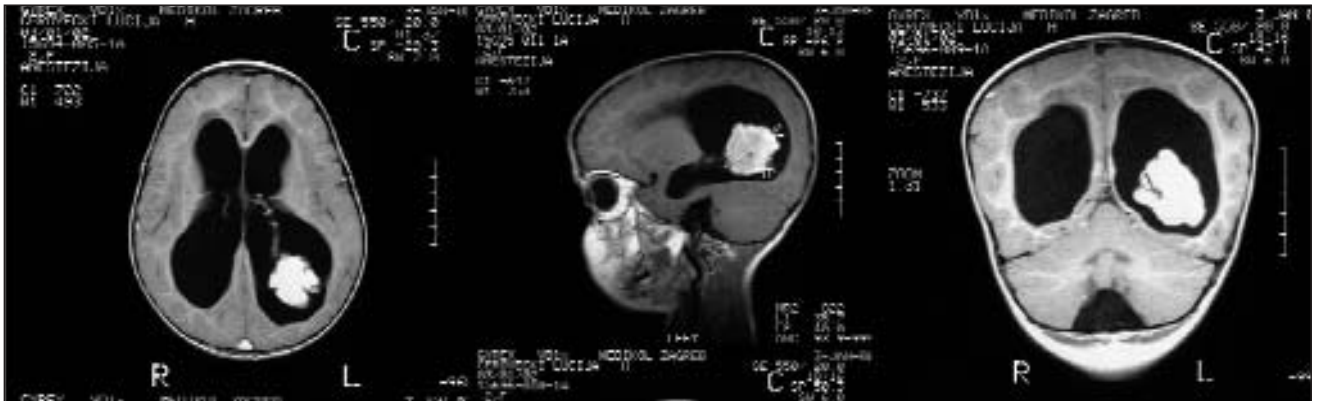

Fig. 7: Preoperative MRI: choroid plexus papilloma

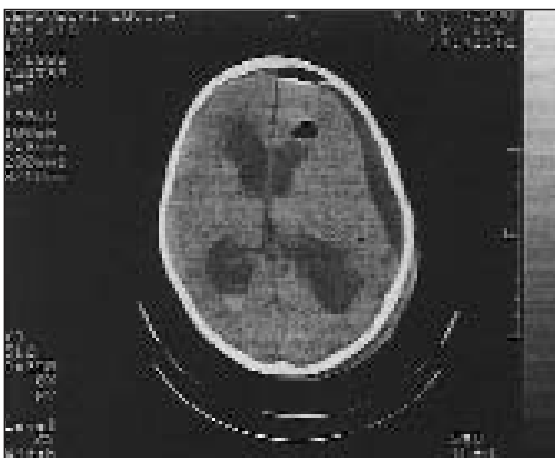

Fig. 8: Postoperative CT scan showing no signs of residual tumour.

## Conclusion

The CO<sub>2</sub> and Nd:YAG laser equipment have become standard part of our neurosurgical armamentarium, and their use is especially valuable in surgeries of deeply located tumours and tumours in skull base. The use of laser at careful protection of the surrounding structures enables direct approach and removal of tumour at minimal compromising of brain tissues, blood vessels and nerves by mechanical and thermal damaging. At the same time, the anatomical integrity of blood vessels and nerves in the tumour site and distally from it remains preserved to maximal extent. Beside debulking of tumour mass and complete removal of tumour by stratified evaporation, the CO<sub>2</sub> laser enables precise operation in small deep and hardly accessible regions of the skull base, while evaporation also enables "sterilisation" of tumour attachments in these regions. Simultaneous use of Nd:YAG laser facilitates particularisation of tumour and establishment of hemostasis.

However, laser as well as other surgical methods cannot guarantee complete reduction of tumour masses that have, for example, protruded into the cavernous sinus, foramen magnum or have pervaded the skull base. Moreover, when using laser there is always the risk of damaging vascular structures, the greater blood vessels surrounded by meningeoma in particular, and also the risk of damaging cranial nerves or the very brain stem. When operating in differential regions the neurophysiological monitoring with registration of evoked potentials is of great help, although it cannot provide complete protection against thermal injuries.

It is for sure that correct use of laser (programming of its operation, power and exposition time) in great number of carefully selected surgeries significantly increases operative abilities of a skilled neurosurgeon and well-trained team, and it is of utmost importance to carefully assess the benefits and risks of laser use for each individual patient.

## References:

1. Beck OJ. Use of the Nd-Yag laser in neurosurgery. *Neurosurg Rev* 1984;7(2-3):151-7.
2. Black PM, Guttmann C, Jolesz F. Present and future applications of lasers in neurosurgery. *Keio J Med* 1993;42(4):169-70.
3. Buki A, Doczi T, Veto F. Initial clinical experience with combined pulsed homium-neodymium YAG laser in minimally invasive neurosurgery. *Minim Invasive Neurosurg* 1999;42(1):35-40.
4. Cerullo LJ. Application of lassers in neurosurgery. Chicago, London: Year book Medical 1992.
5. Devaux BC, Roux FX. Experimental and clinical standards and evolution in laser in neurosurgery. *Acta Neurochir* 1996;138(10):1135-47.
6. Eiras J, Alberdi J, Carcavilla LI, Gomez J, Cantero J. Sterotactic open craniotomy and laser resection of brain tumours. A five years experience. *Acta Neurochir Suppl (Wien)* 1991;52:15-8.
7. Gardner G, Robertson JH, Clark WC, Bellott AL Jr, Hamm CW. Acoustic tumor menagement- combined approach surgery with CO2 laser. *Am J Otol* 1983;5(2):87-108.
8. Handa H, Takeuchi, Yamagami T. Nd-YAG laser as a surgical tool. *Neurosurg Rev* 1984;7(2-3):159-62.
9. Hudorovic N, Paladino J. Ugljicnodioksidni laser u neurokirurgiji. *Libri oncol* 1982;11(1):61-9.
10. Lovric D, Negovetic L, Lupret V, Vidovic D, Gnjidic Z. Evaluation of the use of the CO2 laser in 134 patients with expansive processes in the central nervous system. *Acta Iug* 1989;36(1):27-43.
11. Negovetic L, Lupret V, Skala K. Laser u kirurgiji glave i vrata. Zagreb: Tehnicka knjiga 1990.
12. Paladino J, Pirker N, Vidovic M. Application of Nd:YAG laser in operations of cerebral AV malformations. Book of abstracts, 11 th International congress of neurologic surgery, New Delhi 1989;168.
13. Pirker N, Paladino J. Primjena lasera u neurokirurgiji. *Medix* 2002; 8(suppl I):20-1.
14. Powers SK. Current status of lasers in neurosurgical oncology. *Semin Surg Oncol* 1992;8(4):226-32.
15. Roux FX, Cioloca C, Constans JP. Physical and technical bases of tumor hemostasis with a CO2 laser in neurosurgery. *Neurochirurgie* 1985;31(5):412-4.
16. Roux FX, Leriche B, Cioloca C, Devaux B, Turak B, Nohra G. Combined CO2 and Nd-YAG laser in neurosurgical practice. A 1st experience apropos of 40 intracranial procedures. *Neurochirurgie* 1992;38(4):235-7.
17. Roux FX, Merienne L, Devaux B, Leriche B, Cioloca C. YAG laser in neurosurgery. *Neurochirurgie* 1992;38(4):229-34.
18. Sawoga R, Tew JMB. Laser applications in neurosurgery. Philadelphia: Hanley, Belfus 1987.
19. Stellar S, Polany TG. Lasers in neurosurgery: a historical overview. *J Clin Laser Med Surg* 1992;10(6):399-411.
20. Simunovic Z. Lasers in Surgery and Dentistry. Rijeka: Vitagraf 2001.
21. Vandertop WP, Verdaasdonk RM, van Swol CF. Laser-assisted neuroendoscopy using a Neodymium-Yttrium-Alluminium Garnet or diode contact laser with pretreated fiber tips. *J Neurosurg* 1998;88(1):82-92.

## Curriculum Vitae



*J. Paladino*

Josip Paladino

Neurosurgical Department

School of Medicine

University of Zagreb

Clinical Hospital Center

Ki\_pati\_eva 12, 10 000 Zagreb

CROATIA

Permanent Phone and Fax. No.: (++385)-1-2363 530; (++385)-1-2363 531

E-mail: nrk-kbc@zg.tel.hr

Date and Place of Birth: September 15, 1950. Split, Croatia

Title and Present Position: M.D., Ph. D.

Head of Neurosurgical Department

Education: 1972.-1974. Anatomy demonstrator, Department of Anatomy, School of Medicine, University of Zagreb

1974. M.D. degree, School of Medicine, University of Zagreb

1975. Teacher assistant, Department of Anatomy, School of Medicine, University of Zagreb

1981. Postgraduate degree (Magister Scientiae) in Neurobiology, University of Zagreb

1978.-1984. Neurosurgical residency at Department of Neurosurgery, School of Medicine, University of Zagreb, Clinical Hospital Center Zagreb

1984. Licensed neurosurgeon

1985. Assistant at Department of Surgery, Military surgery and Neurosurgery, School of Medicine, University of Zagreb, Clinical Hospital Center Zagreb

1988. Ph. D. degree, University of Zagreb

1988. Assistant professor at Department of Neurosurgery, School of Medicine, University of Zagreb, Clinical Hospital Center Zagreb

1988. Head of Division of Vascular neurosurgery, School of Medicine, University of Zagreb, Clinical Hospital Center Zagreb

1995. Head of Department of Neurosurgery, School of Medicine, University of Zagreb, Clinical Hospital Center Zagreb

1998. Professor of Neurosurgery, School of Medicine, University of Zagreb

1998. President of Croatian Neurosurgical Society

### Scientific Projects

Functional neurosurgery

Craniocerebral injuries

Refereed Journal Publications (Citations in SCI)

1. Raveh J, Turk I, Lädach K, Seiler R, Goday N, Chen J, Paladino J, Virag M, Leibinger K.

Extended anterior subcranial approach for skull base tumors: long-term results.

J Neurosurg 1995;82:1002-10

2. Paladino J, Heinrich Z, Ivekovic V. Investigation of the physiological proportions of the human brain ventricles by the method of computerized tomography. Coll antropol

1996;20/2:403-12



3. Rotim K, Miklic P, Paladino J, Melada A, Marcikic M, \_\_ap M. Reducing the Incidence of infection in pediatric cerebrospinal fluid shunt operations. Child`s Nerv Syst 1997;13:584-7.
  4. Paladino J, Rotim K, Heinrich Z, Neuroendoscopic fenestration of arachnoid cysts. Minim. Invas. Neurosurg. 1998;41(3):137-40
  5. Paladino J, Pirker N, Stimac D, Stern-Padovan R, Eyebrow keyhole approach in vascular neurosurgery. Min. Invas. Neurosurg. 1998;41(4):200-3
  6. Paladino J, Heinrich Z, Pirker N. Radical surgery of a giant Galen`s vein aneurysm using total circulatory arrest - case report. Surg. Neurol. 1999;51:153-7.
  7. Paladino J, Stimac D, Rotim K, Pirker N, Stimac A. Ultrasonic contact microprobe: Experimental results. Minim. Invas. Neurosurg 2000;43:72-4
  8. Paladino J, Pirker N, Glun\_ic V. Early bifurcation of the left A1 segment. Acta Neurochir (Wien) 2000;142:825-6
  9. Paladino J, Rotim K, Stimac D, Pirker N, Stimac A. Endoscopic third Ventriculostomy with ultrasonic contact microprobe. Minim. Invas. Neurosurg. 43(3):132-4
  10. Paladino J, Rotim K, Pirker N, Glun\_ic V, Juric G, Kalauz M. Minimally invasive Treatment of cavernous angioma of the optic chiasm: Care report. Minim. Invas. Neurosurg. 2001;44:121-3.
- Medical Awards  
 Rectors award (1973.).  
 Award for technical inovation - ultrasonic contact microprobe (2000.).
- Memberships - Professional Societies:  
 Croatian Neurosurgical Society, European Association of Neurosurgical Societies, World Federation of Neurosurgical Societies, Fellow of The Royal Society of Medicine, Member of The Congress of Neurological Surgeons, Croatian Anatomical Society, Croatian Anthropological Society.
- Languages: croatian, english, italian, french



G. Mrak

Name: Goran Mrak, M. D.

Adress: Department of Neurosurgery, School of Medicine, University of Zagreb, Clinical Hospital Center Zagreb, Ki\_pati\_eva 12, 10000 Zagreb, Croatia

Phone: ++385 1 23 88 524

Mobile: ++00385 91 5427397

Personal Data: born on July 27rd 1967 in Vara\_din, Croatia

Education:

1993 M.D. degree, School of Medicine, University of Zagreb

1994 employed in General Hospital Varazdin, Croatia at the Department of surgery

1994-2000 Residency at Department of Neurosurgery in Zagreb

2000 Licensed neurosurgeon

2001 employed at Department of Neurosurgery, School of Medicine Zagreb, Clinical Hospital Centre  
 2002 Postgraduate degree (M.Sc) in Neurobiology

Membership:

Croatian Neurosurgical Society, EANS, WFNS