

ONSET OF SCHIZOPHRENIA PRIOR TO THE END OF BRAIN MATURATION ALTERS GREY MATTER VOLUME LOSS

Antonija Ružić Baršić¹, Lea Gudelj^{2,3}, Ronald Antulov⁴, Damir Miletić^{5,2},
Koraljka Knežević⁶ & Gordana Rubeša^{3,2}

¹Department of Radiology, Thalassotherapia Opatija, Opatija, Croatia

²Clinic of Psychiatry, Clinical Hospital Centre Rijeka, Rijeka, Croatia

³University of Rijeka, Faculty of Medicine, Rijeka, Croatia

⁴Department of Radiology and Nuclear Medicine, Hospital South West Jutland,
University Hospital of Southern Denmark, Odense, Denmark

⁵Department of Clinical Radiology, Clinical Hospital Centre Rijeka, Rijeka, Croatia

⁶Department of Cardiology, Thalassotherapia Opatija, Opatija, Croatia

SUMMARY

Background: Brain maturation is considered completed around the age of 25, when prefrontal cortex maturation has been achieved. The aim of our study was to investigate the alterations of grey matter (GM) in patients with the onset of schizophrenia before and after the completion of brain maturation.

Subjects and methods: The study group included 100 schizophrenia patients, while the control group comprised 50 healthy individuals. Brain magnetic resonance imaging was acquired on a 1.5 T scanner. Voxel-based morphometry (VBM) analyses were performed between groups.

Results: GM of the schizophrenic patients is reduced in many regions ($p < 0.005$ FDR corrected). Most widespread reduction is detected in frontal cortex and cerebellum, the other regions being limbic cortex, insula, cuneus, precuneus, superior temporal gyrus and motor cortex. The decrease of grey matter volume (GMV) increases with the increase in number of psychotic episodes and is more pronounced in the patients with earlier onset of the disease.

Conclusions: The age of the onset of the disease is important for both total and relative loss of GMV. Earlier onset of schizophrenia, prior to full brain maturation results in significant reduction of GM in comparison with healthy subjects and patients with later, post full brain maturation onset of the disease.

Key words: schizophrenia - brain maturation - voxel-based morphometry

* * * * *

INTRODUCTION

Brain maturation is influenced by heredity and environment, and in adolescence, sex hormones have important role in myelination (Arain et al. 2013). In adolescence glutamatergic neurotransmission predominates, particularly in prefrontal cortex (Li & Xu 2008), where immature brain is highly vulnerable. Vulnerability is also significant in limbic system (Peper et al. 2011). Neurotransmission and synaptic plasticity in adolescence can be influenced also by nutrition, substance abuse and neurochemical stressors that can be produced during diseases, particularly psychiatric diseases (Giedd 2004). Abnormal neurotransmission can trigger an excess in pruning of synaptic contacts in adolescence, which can lead to reduction in GM (Uhlhaas 2011, Gogtay et al. 2011), while the late manifestation of schizophrenia can be the consequence of excessive synaptic elimination during adolescence (Peter 1979).

Leading theories regarding etiology of schizophrenia for several decades were neurodevelopmental and neurodegenerative hypothesis. Neurodevelopmental hypothesis includes prenatal, perinatal and/or peri-

adolescent brain damages that had occurred much before the onset of first symptom of the disease. The damages appear to be consequential to the combination of genetic and environmental agents, as well as neurochemical alterations (Murray & Lewis 1987, Fatemi & Folsom 2009). There is a distinctive form of rare and extremely severe type of schizophrenia that occurs in early childhood. It has been a subject of extensive research. There are two distinctive entities – early childhood schizophrenia, and a variety of schizophrenia with the onset during adolescence, prior to the age of 17. Both entities are characterized by various degrees of motor abnormalities, deteriorated social and intellectual capacities and speech impairment, as well as structural brain alterations – i.e. reduced GMV and white matter (WM) volume (Kinross et al. 2010, Honea et al. 2005). However, schizophrenia occurs most frequently in young adult age, by the time brain maturation is nearly or fully accomplished (Uhlhaas 2011).

A number of genes and proteins responsible for abnormal neural development, migration and synaptic plasticity, impaired development of certain brain structures and abnormal neurotransmission were identified.

Consequently, early onset schizophrenic patients often exhibit poor social functioning prior to the onset of the disease (Kinross et al. 2010, Addington et al. 2005). This theory is considered to be “static” (Weinberger 1987), since there is a number of studies that underline dynamic and progressive brain alteration in both early onset and chronic schizophrenic patients. Therefore, brain damages that occur in schizophrenia should not be linked exclusively to the prenatal or postnatal period (Rapoport et al. 2012). Some of the genes involved in the development of schizophrenia show numerous variations in activity and expression during developmental stages and in different regions of the brain (Rapoport et al. 2012). Consequently, neurodevelopmental theory is not entirely adequate in explaining the complexity of the etiology of schizophrenia.

The starting point for neurodegenerative theory of schizophrenia is Kraepelin’s “*dementia praecox*” that places the focus on chronic and progressive mental and physical deterioration that eventually becomes irreversible. In most patients the course of schizophrenia is progressive. Deterioration is linked to the number of relapses and the duration of positive symptoms of the disease (Wyatt 1991). Merely 14% of patients reach recovery within 5 years following the onset of the disease (Robinson et al. 2004).

Some *postmortem* studies failed to demonstrate gliosis (Falkai et al. 1999), while others did show areas of gliosis in schizophrenic patient’s brains. Glutamate-induced toxicity is thought to be responsible for neuronal apoptosis (Harrison 1999). The process is generally initiated in oligodendrocytes (Schnieder & Dwork 2011). Reduced formation of inhibitory synapses and excessive reduction of excitatory synapses during the disease is thought to be responsible for reduction of GM, primarily in frontal cortex. The result is excitatory-inhibitory imbalance in prefrontal cortex (Tuominen et al. 2005). Yet another mechanism that is considered to be causing neurodegeneration is abnormal synaptic activity that leads to depletion of *neuropilin* (Pillet et al. 2016), reduced number of pyramidal cells in thalamo-cortical and cortico-cortical pathways. The consequence is reduction of WM and ventricular enlargement, most likely due to the atrophy of axons, genetically caused myelin alterations or unrecognised infections. All those findings are more prominent in patients with more severe cognitive deterioration and are the indicators of poor prognosis and unfavourable therapeutic response (Viallon et al. 2015). Chemical alterations of numerous neurotransmitters are also found in schizophrenia, leading eventually to neurodegeneration (Empereur-Mot et al. 2015). Neurodegeneration of the brain has been demonstrated in a number of morphological, functional and longitudinal neuroimaging studies (Shenton et al. 2001, Keshavan et al. 1998).

There are several common points in the neurodevelopmental and neurodegenerative theories giving rise to the integration concept. The theories were re-defined and a common theory has been proposed – namely progressive neurodevelopmental disorder (Gupta & Kulhara 2010). The supposition is the conception of the disease during prenatal development, its progression up to the threshold, followed by gradual reduction of brain volume – the overall result being cognitive and functional malfunction (Richard et al. 2015, Moulin et al. 2016).

Brain maturation is thought to be accomplished by the age of 25, when the maturation of prefrontal cortex is achieved (Casey et al. 2008). The aim of our study was to investigate GM alterations in patients having pre-full brain maturation onset (PFBMO) and after-full brain maturation onset (AFBMO) of the disease.

SUBJECTS AND METHODS

Subjects

50 healthy volunteers (healthy control group - HCG) and 100 patients with schizophrenia were included in the study. The patients were recruited from the hospitalized or outpatient cohort of the Psychiatric Clinic, Clinical Hospital Centre Rijeka. The diagnosis of schizophrenia was defined following the International Classification of the Diseases (ICD-10), 10th revision (MKB-10, 1994) and DSM-5 (Association, 2013). Patients were divided in similar groups according to the age of the onset of the disease: before age of 25 (PFBMO) and after age 26 (AFBMO), shown in Table 1.

Control group was composed from the employees at Clinical Radiology Department, Psychiatric Clinic employees, their friends and relatives. None of them had any previous psychiatric symptoms and treatments. Either patients or control group volunteers with brain injury or brain surgery, neurological diseases, permanent cardiac pace-maker carriers, metal object carriers and pregnant women were excluded from the study.

The study registered the intensity of schizophrenia, as well as the intensity of distinct clusters of symptoms using *Positive and Negative Syndrome Scale* - PANSS (Kay 1987) and *Clinical Global Impression* – CGI (Busner & Targum 2007). The scales were administered by a psychiatrist licensed for the aforementioned scales. Brain imaging was performed at the Clinical Radiology Department using 1.5 T MR scanner, *MAGNETOM Avanto Siemens* (made in Erlangen, Germany). The images were processed by a personal computer.

The study was approved by Ethical Committee of the Clinical Hospital Centre Rijeka. Demographic and clinical features of the groups are shown in Table 1 and 2.

Table 1. Descriptive statistics (quantitative variables) for the age of the onset of the disease (PFBMO, prior to the age of 25; AFBMO, after the age of 26, HCG- healthy control_group)

	Group														
	AFBMO (n=57)				PFBMO (n=43)				HCG (n=50)						
	Av.	SD	Min.	Max.	Med.	Av.	SD	Min.	Max.	Med.	Av.	SD	Min.	Max.	Med.
Age	44.58	10.69	26.00	71.00	43.00	29.42	10.68	14.00	59.00	30.00	35.84	8.91	21.00	61.00	33.00
Number of episodes	5.28	4.65	1.00	18.00	4.00	3.93	3.84	1.00	17.00	2.00					
Age of onset of disease	31.02	4.76	26.00	44.00	30.00	19.65	4.02	7.00	25.00	20.00					
Disease duration	13.79	9.60	0.00	36.00	15.00	9.72	9.28	0.00	42.00	9.00					
CGI	5.51	0.70	4.00	7.00	6.00	5.28	0.70	4.00	7.00	5.00					
PANSS positive	26.14	4.99	17.00	34.00	26.00	27.61	4.99	18.00	38.00	27.00					
PANSS negative	28.60	6.54	16.00	41.00	29.00	27.54	5.72	16.00	41.00	27.00					
PANSS general	50.67	8.07	32.00	70.00	51.00	50.96	8.27	28.00	73.00	49.00					
PANSS total	106.00	13.59	74.00	140.00	105.00	105.81	14.31	49.00	135.00	104.00					
CSF volume in cm ³	327.02	86.81	105.00	618.00	333.00	305.35	65.92	189.00	475.00	310.00	282.26	52.74	147.00	427.00	271.50
Relative CSF volume in %	22.31	4.77	7.61	34.35	21.92	20.07	3.67	11.69	28.09	20.13	18.71	3.18	10.74	27.80	18.18
GM volume in cm ³	586.12	76.88	320.00	759.00	586.00	653.89	89.92	321.00	812.00	675.00	665.46	69.40	541.00	840.00	664.00
Relative GM volume in %	40.27	3.77	23.19	45.40	40.76	43.08	4.70	19.99	50.26	43.36	44.10	2.56	36.13	49.77	44.12
WM volume in cm ³	533.19	74.65	347.00	702.00	528.00	553.77	62.25	397.00	656.00	551.00	561.02	63.41	418.00	726.00	548.00
Relative WM volume in %	36.49	2.19	31.85	40.86	36.92	36.41	1.76	32.84	39.97	36.62	37.13	1.70	31.79	40.59	37.23
TIV	1459.23	171.18	1022.00	1838.00	1424.00	1520.02	148.18	1117.00	1828.00	1532.00	1509.64	140.38	1298.00	1897.00	1500.50

Av. = Average; SD = Standard Deviation; Min. = Minimal; Max. = Maximal; M = Mean

Table 2. Total number and percentage of healthy and diseased subjects divided by quantitative variables for the onset of the disease

Group		Gender		R	Hand		Ambi
		M	F		L		
AFBMO	N	26	17	40	2	1	
	%	60.47	39.53	93.02	4.65	2.33	
PFBMO	N	36	21	52	5		
	%	63.16	36.84	91.23	8.77		
HCG	N	25	25	49	1		
	%	50.00	50.00	98.00	2.00		
<i>Total</i>	N	87	63	141	8	1	

M = Male; F = Female; R = Right; L = Left; Ambi = Ambidexter

Table 3. Variance analysis table: GM volume in relation to the onset of the disease (PFBMO and AFBMO patients) (including interactions) with co-variables total volume and age

	Degrees of freedom	Sum of squares	Average sum of squares	F stat.	p-value
Model	5	589867.0699	117973.4140	49.56	<0.0001
Error	94	223759.6801	2380.4221		
Correction total	99	813626.7500			

MRI acquisition and VBM analysis

Brain imaging was acquired on a single 1.5 T Magnetom Avanto Siemens (Erlangen, Germany) using a 32-channel head coil and a tilted T1-weighted coronal 3D magnetization prepared rapid acquisition gradient echo sequence (MPRAGE: TR 2400 ms; TE 3.61 ms; flip angle 8°; FoV 240 x 240 mm; matrix 192x192; two acquisitions). This sequence produces 160 contiguous images (slice thickness 1.2 mm), sagittal orientation.

The whole-brain images pre-processing and data voxel-based morphometry (VBM) analysis was done with the CAT12 toolbox (<http://www.neuro.uni-jena.de/cat/>) integrated in the SPM12 software package (<https://www.fil.ion.ucl.ac.uk/spm/software/spm12/>), running on MATLAB R2020 (<https://www.mathworks.com/>). It makes use of the DARTEL algorithm for high-resolution spatial transformation processes and T1-weighted images were segmented into GM, WM and CSF. Total intracranial volume (TIV) for all the subjects was also calculated. The GM and WM segments of all subjects were normalized to create an average anatomical template. The modulated normalized nonlinear GM segments were smoothed by an 8-mm full-width at half-maximum Gaussian kernel.

The images were statistically analysed by general linear model implemented into SPM12. Groups and variables were defined. Variables comprised of age and TIV. Co-variance analysis (ANCOVA) was also used. For comparison of distinct groups of patients further co-variables used were the duration of disease and the number of psychotic episodes. Cluster's threshold was 20 voxels, $p < 0.05$, plus FDR correction for multiple comparisons.

The images of the results and the detection of coordinates for affected regions of GM in MNI space was performed using xjView 9.7 programme (<https://www.alivelearn.net/xjview/>).

Statistical analysis

The data were statistically analysed with SAS© statistical software (Cary, NC.). Descriptive statistics and data visualisation, as well as inferential statistics and modelling were employed, namely: multiple regression, variance analysis and co-variance analysis (SAS© procedures, reg). Within the selected models, the significance of difference in median values (GMV) and the significance of distinctive factors of the model were tested. The results of distinctive effects tested within the model, the sums of square type III were used (Goodnight 1978, 1980). The level of significance $\alpha = 0.05$ was set for all the statistical tests.

To test the specific goals, i.e. the differences in average GMV between distinct categories of predictive variable, t test was used.

RESULTS

Distribution of GMV is shown graphically, clustered in categories of key variables in rectangle diagram (Figure 1). Table 3. shows the results of variance and co-variance analysis for GMV in correlation with the age of the onset of the disease (PFBMO and AFBMO), as well as in correlation with the number of psychotic episodes, including interactions and co-variable for the total volume and the age. This model is statistically significant ($p < 0.0001$).

The trend of increased GMV reduction in patients with higher number of psychotic episodes differs between PFBMO and AFBMO. The results are shown as the dispersion diagram in Figures 2.a and 2.b. Figures 3.a and 3.b show the relative GMV. The differences in GMV between PFBMO and AFBMO subjects are shown, as well as statistically significant ($p = 0.0079$) interaction of the number of episodes and the age of the

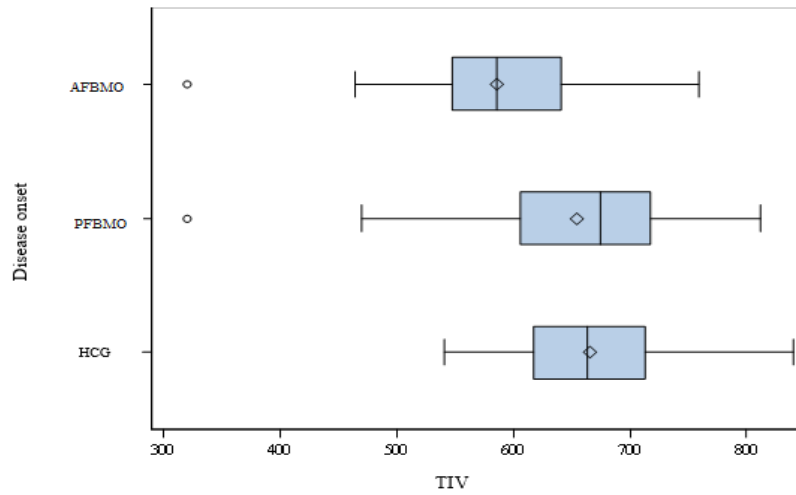


Figure 1. GMV for categories HCG, PFBMO and AFBMO

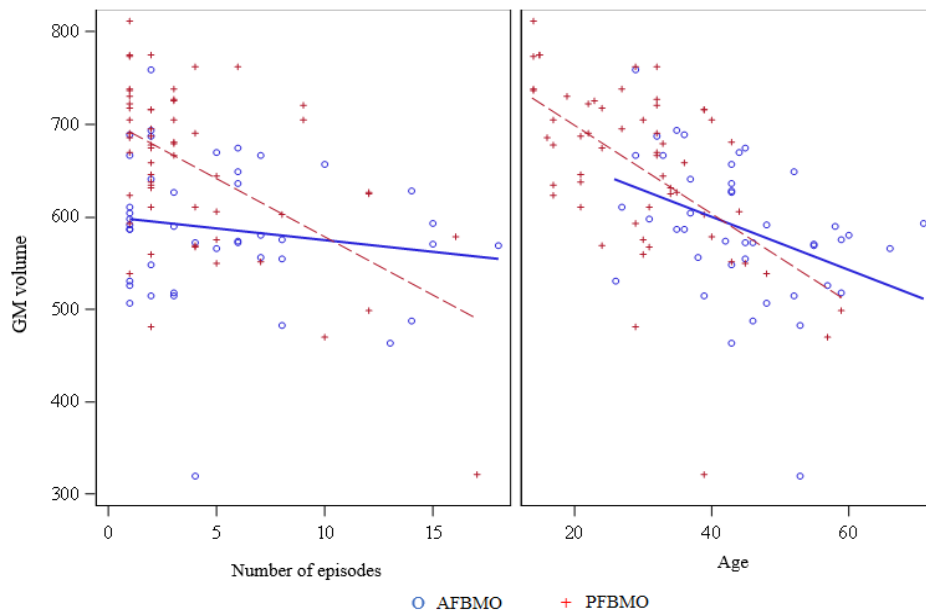


Figure 2. GMV according to the number of episodes for categories PFBMO and AFBMO

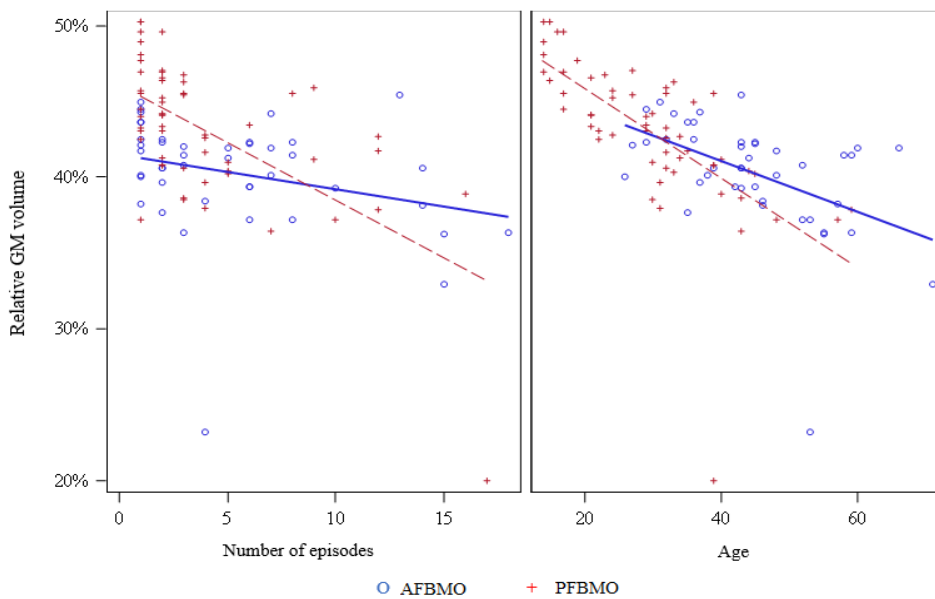


Figure 3. Relative GMV according to the number of episodes for categories PFBMO and AFBMO

onset of the disease (Figure 2.a, 2.b, 3.a, 3.b and table 4). The greater the number of psychotic episodes, the greater is the reduction of GMV in both groups, but more so in PFBMO group. Also, greater number of psychotic episodes causes greater GMV reduction in PFBMO than in AFBMO group. In general, the GMV reduction caused by multiple psychotic episodes is much less pronounced in AFBMO group.

Table 4. Significance of individual effects in the model (sum of type III squares): GMV in correlation to the onset of the disease (PFBMO and AFBMO) and number of episodes (with interactions) with co-variables TIV and age

Variable	p-value
Disease onset	0.0838
Number of episodes	0.0056
Number of episodes* Disease onset	0.0079
Age	<0.0001
TIV	<0.0001

Since the age is a statistically significant factor in this model ($p < 0.0001$), Figure 2.b also shows the impact of the age on GMV in PFBMO and in AFBMO groups of patients. Total GMV is another statistically significant factor ($p < 0.0001$). Figure 3.a shows relative GMV and the differences due to the onset of the disease and the age of the subjects (Figure 3.b). Further tests that target specific hypothesis (ANOVA model) on the differences in median GMV in correlation with the age

of onset (early: prior to the age of 25, late: after the age of 26) and with the number of psychotic episodes: 1, 5, 10 and 20, together with co-variables of total GMV and age, statistically significant differences in GMV were found between PFBMO and AFBMO with 10 and 20 episodes, but in patients with lesser number of episodes (1 and 5) the differences were not statistically significant (Table 5).

Table 5. Specific hypothesis test (from ANOVA model) on the differences of average GM in relation to the onset of the disease (PFBMO and AFBMO) and the number of episodes 1, 5, 10 and 20, with co-variables TIV and age

Number of episodes	Group	Average estimation	p-value
	AFBMO	621.990863	0.9298
	PFBMO	623.092695	-
1	AFBMO	624.510090	0.1343
	PFBMO	648.231024	-
5	AFBMO	621.639176	0.8688
	PFBMO	619.583355	-
10	AFBMO	618.050532	0.0478
	PFBMO	583.773768	-
20	AFBMO	610.873245	0.0101
	PFBMO	512.154595	-

Comparison of PFBMO, AFBMO and control group by VBM is shown in Tables 6, 7 and 8 and Figures 4, 5, and 6.

Table 6. Significant GM clusters in VBM analysis – HCG and PFBMO ($p < 0.05$, FDR corrected, clusters $k \geq 20$ voxels are shown)

Coordinates with maximal number of voxels	K (number of voxels)	T	Anatomical region
13.5, -70.5, -30	3535	4.51	Right cerebellum; declive, tonsil, uvula, pyramis, nodule, nucleus dentatus, vermis
-25.5, -85.5, -40	379	3.10	Left cerebellum; inferior semilunar lobule, crus, pyramis
-25.5, -63, -39	78	2.91	Left cerebellum; posterior lobus, pyramis
22.5, -79.5, -39	126	2.97	Right cerebellum; posterior lobus, pyramis
31.5, -6, -31.5	87	3.05	Right cuneus
51, -39, -4.5	51	3.07	Right middle temporal gyrus
51, -36, 15	1020	4.04	Right superior temporal gyrus, Rolandic operculum, Brodmann region 41, transversal tempora gyrus, postcentral gyrus, Heschlov gyrus, insula, precentral gyrus, Brodman regions 43 and 13
16.5, 88.5, 12	20	3.08	Right cuneus, Brodmann region 18
15, 36, 15	67	3.24	Right anterior gyrus cinguli
34.5, -28.5, 24	41	2.90	Right insula
-51, 31.5, 30	33	3.28	Left inferior parietal lobule
48, -33, 37.5	267	3.86	Right postcentral gyrus, supramarginal gyrus, inferior parietal lobule
-31.5, 19.5, 42	188	3.78	Left precentral and postcentral gyrus
-36, 15, 34.5	75	3.69	Left middle frontal gyrus, Brodmann region 9
-42, -49.5, 40.5	125	3.60	Left inferior parietal lobule, Brodmann region 40
-28.5, -40.5, 46.5	20	3.08	Left postcentral gyrus
-43.5, -25.5, 51	145	3.50	Left postcentral gyrus

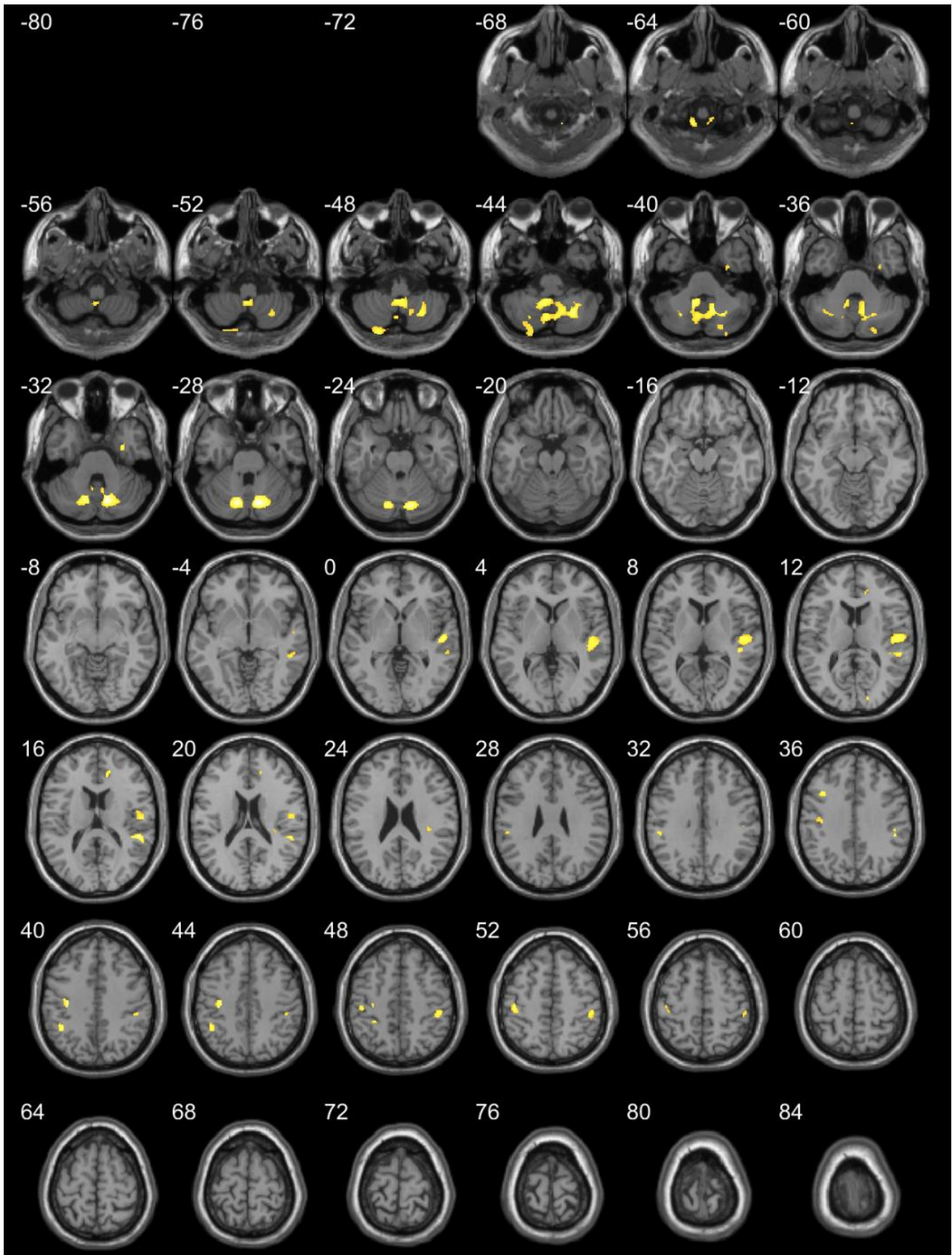


Figure 4. Significant GM clusters in VBM analysis – HCG and PFBMO ($p < 0.05$, FDR corrected, clusters $k \geq 20$ voxels are shown)

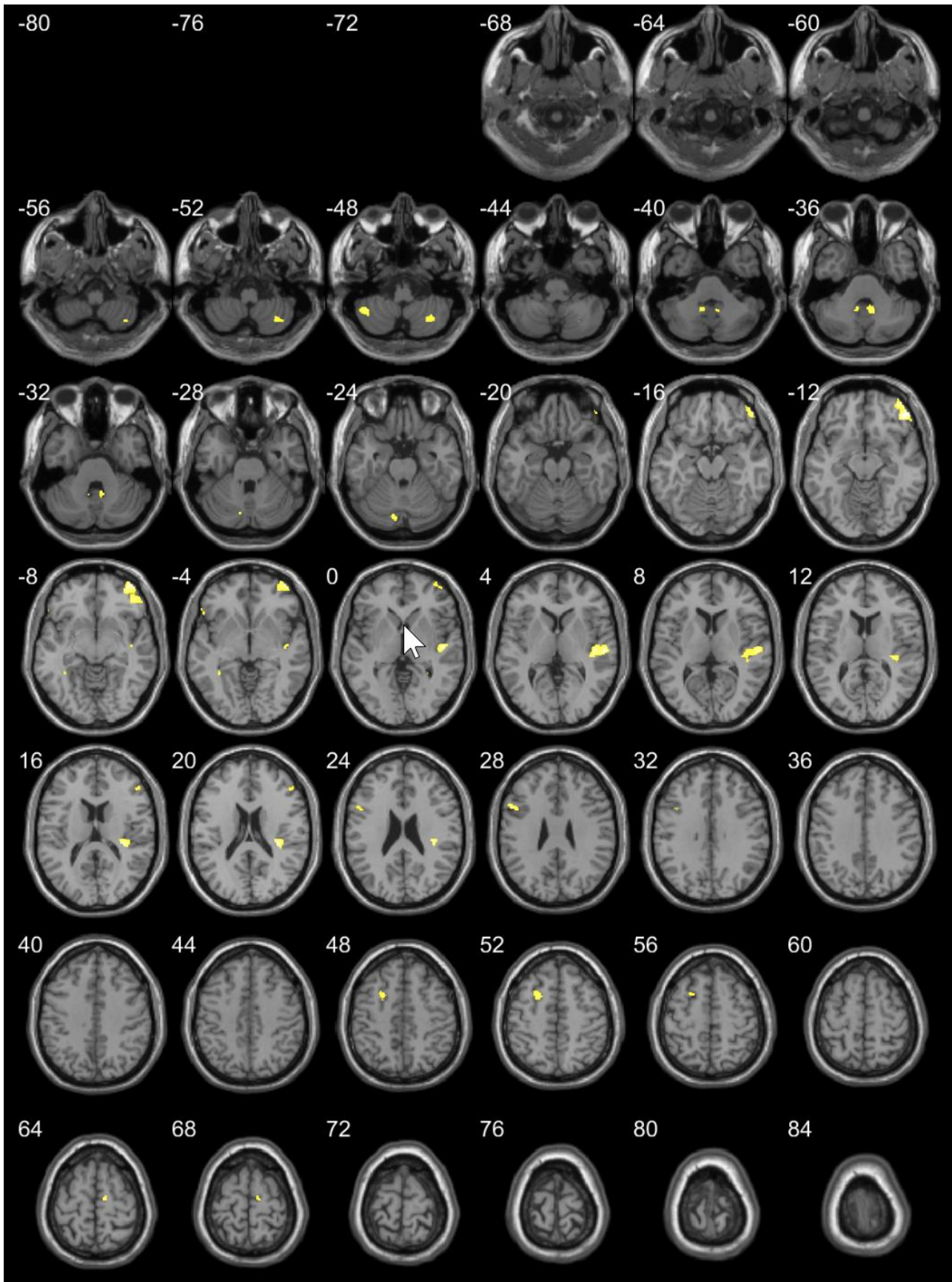


Figure 5. Significant GM clusters in VBM analysis – HCG and AFBMO ($p < 0.05$, FDR corrected, clusters $k \geq 20$ voxels are shown)

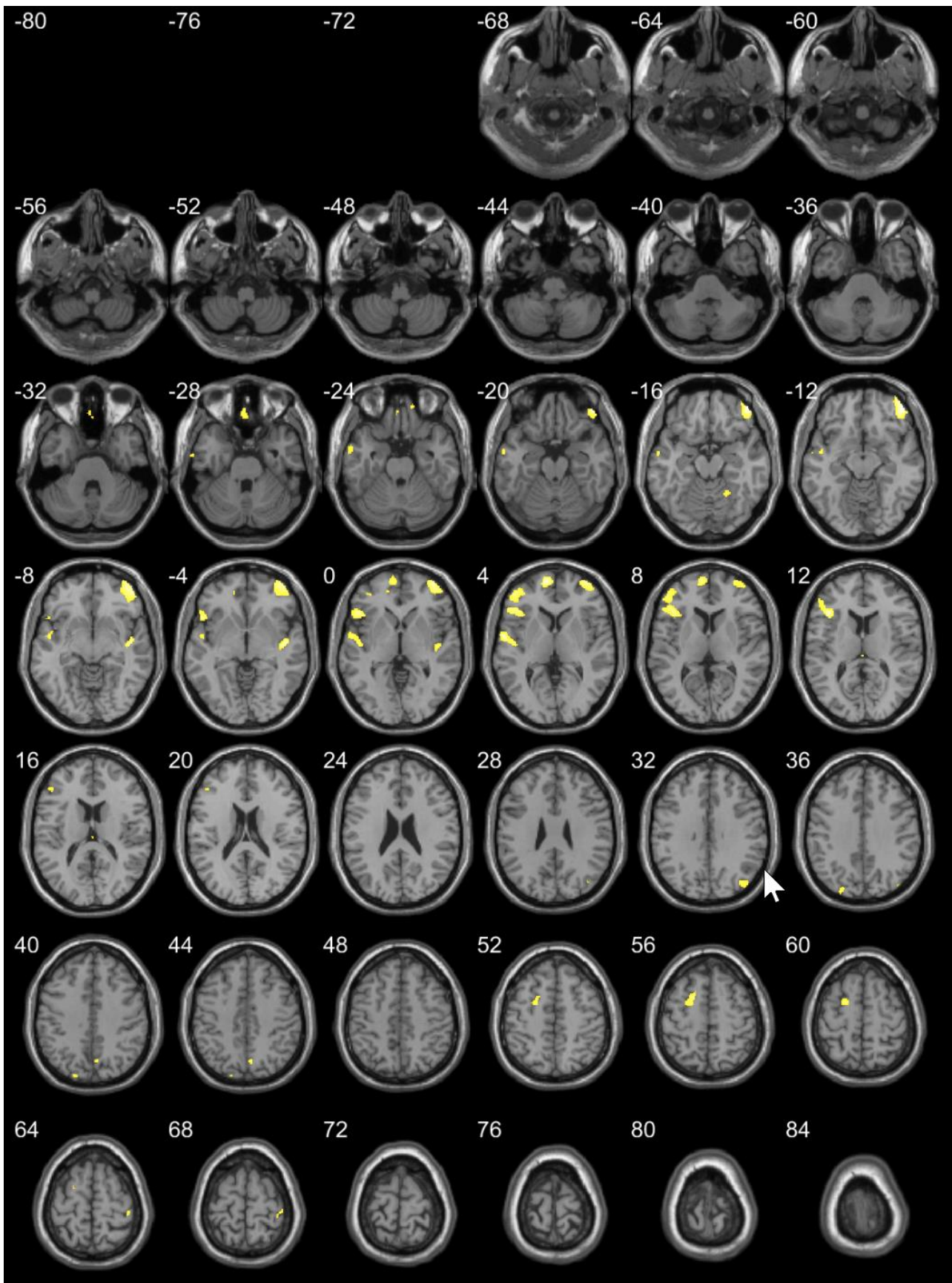


Figure 6. Significant GM clusters in VBM analysis – PFBMO and AFBMO ($p < 0.05$, FDR corrected, clusters $k \geq 20$ voxels are shown)

Table 7. Significant GM clusters in VBM analysis – HCG and AFBMO ($p < 0.05$, FDR corrected, clusters $k \geq 20$ voxels are shown)

Coordinates with maximal number of voxels	K (number of voxels)	T	Anatomical region
31.5, -63, -48	186	2.98	Right inferior semilunar lobule
-43.5, -51, -46.5	121	3.08	Left cerebellar tonsil
-10.5, -51, -37.5	71	2.91	Left cerebellum; nodule, tonsil, nucleus dentatus
7.5, -49.5, -34.5	149	3.00	Left cerebellum; nodule, tonsil, nucleus dentatus
-9, -78, -25.5	78	3.05	Left cerebellum; declive
48, 40.5, -10.5	929	4.01	Right middle frontal gyrus, inferior and middle orbital gyrus
48, -16.5, 1.5	905	3.84	Right superior temporal gyrus, Brodmann regions 22, 13 and 41, superior temporal gyrus, insula
-36, -45, -6	24	2.89	Left parahippocampal gyrus
-55.5, 30, -6	24	2.83	Left inferior frontal gyrus
28.5, -45, -1.5	23	3.06	Right lingual gyrus
52.5, 36, 18	41	2.90	Right middle frontal gyrus
-51, 13.5, 28.5	103	3.16	Left inferior frontal gyrus
-37.5, 13.5, 33	26	2.93	Left middle frontal gyrus
-19.5, 6, 49.5	179	3.16	Left gyrus cinguli, Brodmann region 32
12, -12, 64.5	46	3.34	Right middle frontal gyrus

Table 8. Significant GM clusters in VBM analysis – PFBMO and AFBMO ($p < 0.05$, FDR corrected, clusters $k \geq 20$ voxels are shown)

Coordinates with maximal number of voxels	K (number of voxels)	T	Anatomical region
-1.5, 43.5, -28.5	150	3.02	Left gyrus rectus, Brodmann region 11
-57, 0, -24	165	2.83	Left middle temporal gyrus, Brodmann region 21
13.5, 49.5, -22.5	25	2.79	Right superior orbital gyrus
48, 46.5, -16.5	1701	3.99	Right middle, inferior and superior gyrus, medial orbital gyrus, Brodmann region 10, 11 and 47
22.5, -52.5, -15	63	3.05	Right culmen
-57, -3, 3	521	3.81	Left superior temporal gyrus, precentral gyrus, Heschl gyrus, insula, Rolandic operculum, Brodmann region 22
48, -10.5, -4.5	250	3.63	Right superior temporal gyrus, insula
-39, 24, 12	1352	3.96	Left middle and inferior frontal gyrus, inferior orbital gyrus Brodmann regions 10, 13, 45, 46 and 47
-15, 49.5, -1.5	27	3.06	Left middle frontal gyrus
-9, 61.5, 3	335	3.92	Left middle frontal gyrus
42, -76.5, 33	111	3.00	Right precuneus
-25.5, -85.5, 36	97	2.93	Left cuneus
7.5, -67.5, 42	35	2.90	Right precuneus
-16.5, 7.5, 54	286	3.39	Left middle frontal gyrus, Brodmann region 6
42, -30, 67.5	46	2.96	Right postcentral gyrus

DISCUSSION

To the best of our knowledge this is the first study that compares the GMV in patient's brains relative to the onset of schizophrenia before or after full brain maturation. Existing studies showed alterations in brain structure during adolescence (Sowell et al. 1999). The alterations are documented by neuroimaging. Majority of studies were focused on frontal lobes' maturation (Lenroot & Giedd 2006). Frontal lobes are the last to reach full maturity, and the process continues further

with the establishment and additional maturation of connections within the brain (Giedd 2008) as well as environmentally stimulated modulation (Spear 2000). The net result is high specificity of each of the brain structures. Frontal lobes are key structures for executive brain pathways, such as planning, operative memory, impulse control. Final maturation of frontal lobes (happening habitually around mid-twenties) represents the final stage of brain maturation (Sowell et al. 1999). Therefore, in our study the patients were divided into groups according to the age of the onset of the disease –

before the age of 25 and after the age of 26. The alterations we found, when compared to healthy subject's brains, affected the frontal cortex. Our results show the greatest inter-group differences in the frontal lobes.

Alterations of cerebellum were also found, particularly between AFBMO and PFBMO groups versus HCG. Reduced GMV in cerebellum is related to the decrease of dynamic functional connections between cerebellum and frontoparietal functional network (He et al. 2019). In previous studies reduced GMV in cerebellum was found in patients affected by cognitive impairment in the first schizophrenic episode (Wang et al. 2017). Cerebellum abnormalities impact sensorial, motor and cognitive functions. Reduction of GMV in cerebellum may be related to cerebellum – thalamus modulation and may contribute to dysfunctional cerebello-cortical communication in schizophrenia (He et al. 2019). The cognitive dysmetria theory is based upon the dysfunction of cerebello-thalamo-cortical circuit. It represents an important neurobiological alteration that consequently causes clinical symptoms of schizophrenia (Andreasen et al. 1998, Wiser et al. 1998).

Alterations of limbic cortex and motor cortex were also established. They are the consequence of abnormal transmission of a series of neurotransmitters, particularly long-lasting hyper-secretion of dopamine and glutamate. It has the direct impact upon limbic and thalamo-cortical pathways, a phenomenon that leads to psychosis (Carlsson et al. 2000, et al. 2001).

GMV reduction is observed in the insula as well. Insular alterations may contribute to many sensory deficiencies in schizophrenia (Wylie & Tregellas 2010). Alterations of insular cortex were observed in chronic schizophrenic patients (Nesvag et al. 2008).

The observation of patient groups reveals the alterations in gyrus rectus. Gyrus rectus is thought to be responsible for the cognition (Joo et al. 2016). GMV is also reduced in olfactory gyri due to impaired integration with all the other sensory modalities in schizophrenia (Kiparizoska & Ikuta 2017).

Early onset of schizophrenia disrupts brain maturation, including GM and WM (Douaud et al. 2009) and supports the neurodevelopmental etiology (Crow et al. 1995). Early onset of the disease usually means severe form of the disease (Kumra & Schulz 2008, Kyriakopoulos & Frangou 2007). Brain structure's alterations in early onset schizophrenia show wider distribution (Rapoport et al. 2001), particularly throughout initial three years of the disease (Brent et al. 2013).

In our study, GMV alterations in patients with onset of the disease prior to the age of 25 were more prominent both in number and volume when compared to the patients with the onset of the disease after the age of 26. Comparison of the two groups of patients shows numerous and prominent alterations (Tables 6, 7 and 8, Figures 4, 5 and 6), also related to the number of

episodes. Considering the psychotic episode as neurochemical stressor (Viallon et al. 2015b) and its impact on GMV reduction (Ruzic Barsic 2020), unmaturation of brain is more sensitive to repetitive stress which is shown in our study.

All the comparisons show GMV changes in superior temporal gyrus, a region responsible for lateralisation and pathological language and speech development, which is found regularly in schizophrenia. GMV reduction in superior temporal gyrus is likely to be representative for early impairment of neuro-development (Matsumoto et al. 2001). The difference between PFBMO and AFBMO lays in the absence of lateralisation in PFBMO, whereas it is present in AFBMO (Matsumoto et al. 2001).

The remaining affected regions are motor regions, parietal and occipital cortex, limbic cortex. In early onset schizophrenic patients there are also widespread alterations in cerebellum. Focal abnormalities in limbic regions were observed in early onset schizophrenia. It is likely that the limbic abnormalities are the culprit for schizophrenia, since there is a body of evidence for the existence of very early limbic abnormalities that progress with time and can be traced in adulthood as well (White et al. 2007).

The comparison of patients showed the differences in precuneus and cuneus. The differences in precuneus volume, namely enlarged volume, were found in patients with late onset schizophrenia, but the reasons for the increase are unclear (Egashira et al. 2014). Precuneus has widespread connections with cortical structures and is involved in consciousness, self-processing, empathy, memory retrieval and visuo-spatial imagery (Cavanna & Trimble 2006).

Previous studies showed that early onset schizophrenia during adolescence (prior to the age of 18) causes severe clinical presentation of the disease. The observation is reflected in more prominent and widespread alterations in GMV, since they occur in critical period, at the time the brain is still in the process of maturation (Douaud et al. 2009). Our study showed similar results.

CONCLUSIONS

GMV in schizophrenic patient's brain is reduced in many regions of the brain. The altered regions are numerous and are found in: prefrontal, temporal, parietal and occipital cortex, in limbic structures, basal ganglia and cerebellum. The age of the onset of the disease is important regarding total and relative loss of GMV. Early onset of schizophrenia, prior to the full brain maturation, causes more pronounced reduction of GMV in comparison to healthy individuals as well as in comparison to the patients with the onset of the disease after full brain maturation.

Acknowledgements:

The authors kindly thank all participants for their contribution and to radiographers at Department of Clinical Radiology, Clinical Hospital Centre Rijeka, Croatia for their technical expertise and support in data acquisition.

Conflict of interest: None to declare.

Contribution of individual authors:

Antonija Ružić Baršić: idea, concept and design of the article, writing manuscript, software implementation, methodology.

Lea Gudelj: writing manuscript, review, editing.

Ronald Antulov: methodology.

Damir Miletić: supervision.

Koraljka Knežević: literature searches.

Gordana Rubeša: resources, evaluated and sampled patients, approval of the final version.

References

1. Addington AM, Gornick M, Duckworth J, Sporn A, Gogtay N, Bobb A et al.: *GAD1 (2q31.1), which encodes glutamic acid decarboxylase (GAD67), is associated with childhood-onset schizophrenia and cortical gray matter volume loss* *Mol Psychiatry* 2005; 10:581-588
2. Andreasen NC, Paradiso S & O'Leary DS. "Cognitive dysmetria" as an integrative theory of schizophrenia: a dysfunction in cortical-subcortical-cerebellar circuitry? *Schizophr Bull* 1998; 24:203-218
3. Arain M, Haque M, Johal L, Mathur P, Nel W, Rais A et al.: *Maturation of the adolescent brain. Neuropsychiatric disease and treatment* 2013; 449-461.
4. Association AP. *Diagnostic and Statistical Manual of Mental Disorders (5th ed.)*. Washington DC: American Psychiatric Publishing 2013.
5. Brent BK, Thermenos HW, Keshavan MS & Seidman LJ: *Gray matter alterations in schizophrenia high-risk youth and early-onset schizophrenia: a review of structural MRI findings. Child Adolesc Psychiatr Clin N Am* 2013; 22:689-714
6. Busner J & Targum SD: *The clinical global impressions scale: applying a research tool in clinical practice. Psychiatry (Edgmont)* 2013; 4:28-37
7. Carlsson A, Waters N, Waters S & Carlsson ML: *Network interactions in schizophrenia - therapeutic implications. Brain Res Brain Res Rev* 2000; 31:342-349
8. Casey BJ, Jones RM & Hare TA: *The adolescent brain. Annals of the New York Academy of Sciences*, 2008; 1124:111-126.
9. Cavanna AE & Trimble MR: *The precuneus: a review of its functional anatomy and behavioural correlates. Brain* 2006; 129:564-583
10. Crow TJ, Done DJ & Sacker A: *Childhood precursors of psychosis as clues to its evolutionary origins. Eur Arch Psychiatry Clin Neurosci* 1995; 245:61-69
11. Douaud G, Mackay C, Andersson J, James S, Quedest D, Ray MK et al.: *Schizophrenia delays and alters maturation of the brain in adolescence. Brain* 2009; 132(Pt 9):2437-2448
12. Egashira K, Matsuo K, Mihara T, Nakano M, Nakashima M, Watanuki T et al.: *Different and Shared Brain Volume Abnormalities in Late- and Early-Onset Schizophrenia. Neuropsychobiology* 2013; 70:142-151
13. Empeur-Mot C, Guillemain H, Latouche A, Zagury JF, Viallon V & Montes M: *Predictiveness curves in virtual screening. J Cheminform* 2015; 7:52
14. Falkai P, Honer WG, David S, Bogerts B, Majtenyi C & Bayer TA: *No evidence for astrogliosis in brains of schizophrenic patients. A post-mortem study. Neuropathol Appl Neurobiol* 1999; 25:48-53
15. Fatemi SH & Folsom TD: *The neurodevelopmental hypothesis of schizophrenia, revisited. Schizophr Bull* 2009; 35:528-548
16. Giedd JN: *Structural magnetic resonance imaging of the adolescent brain. Ann N Y Acad Sci* 2004; 1021:77-85.
17. Giedd JN: *The teen brain: insights from neuroimaging. J Adolesc Health* 2008; 42:335-343
18. Gogtay N, Vyas NS, Testa R, Wood SJ & Pantelis C: *Age of onset of schizophrenia: perspectives from structural neuroimaging studies. Schizophr Bull* 2011; 37:504-513
19. Goodnight JH: *Least-Squares Means in the Fixed-Effects General Linear Models*, SAS Institute, Incorporated, 1978
20. Goodnight JH: *Tests of hypotheses in fixed effects linear models. Communications in Statistics - Theory and Methods* 1980; 9:167-180
21. Gupta S & Kulhara P: *What is schizophrenia: A neurodevelopmental or neurodegenerative disorder or a combination of both? A critical analysis. Indian J Psychiatry* 2010; 52:21-27
22. Harrison PJ: *The neuropathology of schizophrenia. A critical review of the data and their interpretation. Brain* 1999; 122(Pt 4):593-624
23. He H, Luo C, Luo Y, Duan M, Yi Q, Biswal BB & Yao D: *Reduction in gray matter of cerebellum in schizophrenia and its influence on static and dynamic connectivity. Hum Brain Mapp* 2019; 40(2):517-528.
24. Honea R, Crow TJ, Passingham D & Mackay CE: *Regional deficits in brain volume in schizophrenia: a meta-analysis of voxel-based morphometry studies. Am J Psychiatry* 2005; 162(12):2233-2245.
25. Joo MS, Park DS, Moon CT, Chun YI., Song SW & Roh HG: *Relationship between Gyrus Rectus Resection and Cognitive Impairment after Surgery for Ruptured Anterior Communicating Artery Aneurysms. Journal of cerebrovascular and endovascular neurosurgery* 2016; 18:223-228
26. Kay SR, Fiszbein A, Opler LA: *The Positive and Negative Syndrome Scale (PANSS) for Schizophrenia. Schizophr Bull* 1987; 13:261-276.
27. Keshavan MS, Haas GL, Kahn CE, Aguilar E, Dick EL, Schooler NR et al.: *Superior temporal gyrus and the course of early schizophrenia: progressive, static, or reversible? J Psychiatr Res* 1998; 32:161-167
28. Kinross J, Reichenberg A & Frangou S: *The neurodevelopmental theory of schizophrenia: evidence from studies of early onset cases. Isr J Psychiatry Relat Sci* 2010; 47:110-117
29. Kiparizoska S & Ikuta T: *Disrupted Olfactory Integration in Schizophrenia: Functional Connectivity Study. The international journal of neuropsychopharmacology* 2017; 20:740-746
30. Kumra S & Charles Schulz S: *Editorial: research progress in early-onset schizophrenia. Schizophr Bull* 2008; 34:15-17
31. Kyriakopoulos M & Frangou S: *Pathophysiology of early onset schizophrenia. Int Rev Psychiatry* 2007; 19:315-324

32. Lenroot RK & Giedd JN: Brain development in children and adolescents: insights from anatomical magnetic resonance imaging. *Neurosci Biobehav Rev* 2006; 30:718-729
33. Li K & Xu E: The role and the mechanism of gamma-aminobutyric acid during central nervous system development. *Neurosci Bull* 2008; 24:195-200
34. Matsumoto H, Simmons A, Williams S, Hadjulis M, Pipe R, Murray R & Frangou S: Superior temporal gyrus abnormalities in early-onset schizophrenia: similarities and differences with adult-onset schizophrenia. *Am J Psychiatry* 2001; 158:1299-1304
35. Međunarodna klasifikacija bolesti i srodnih zdravstvenih problema : MKB-10 - deseta revizija (deseta revizija ed.). Zagreb: Medicinska naklada, 1994
36. Moulin K, Croisille P, Feiweier T, Delattre BM, Wei H, Robert B et al: In vivo free-breathing DTI and IVIM of the whole human heart using a real-time slice-followed SE-EPI navigator-based sequence: A reproducibility study in healthy volunteers. *Magn Reson Med* 2016; 76(1):70-82.
37. Murray RM & Lewis SW: Is schizophrenia a neurodevelopmental disorder? *Br Med J (Clin Res Ed)* 1987; 295:681-682
38. Nesvag R, Lawyer G, Varnas K, Fjell AM, Walhovd KB, Frigessi A et al.: Regional thinning of the cerebral cortex in schizophrenia: effects of diagnosis, age and anti-psychotic medication. *Schizophr Res* 2008; 98:16-28
39. Peper JS, van den Heuvel MP, Mandl RCW, Pol HEH & van Honk J: Sex steroids and connectivity in the human brain: A review of neuroimaging studies. *Psychoneuroendocrinology* 2011; 36:1101-1113
40. Peter RH: Synaptic density in human frontal cortex — Developmental changes and effects of aging. *Brain Research* 1979; 163:195-205
41. Pillet S, Berthelot P, Gagneux-Brunon A, Mory O, Gay C, Viallon A et al.: Contamination of healthcare workers' mobile phones by epidemic viruses. *Clin Microbiol Infect* 2016; 22:456 e451-456
42. Rapoport JL, Castellanos FX, Gogate N, Janson K, Kohler S & Nelson P: Imaging normal and abnormal brain development: new perspectives for child psychiatry. *Aust N Z J Psychiatry* 2001; 35:272-281
43. Rapoport JL, Giedd JN & Gogtay N: Neurodevelopmental model of schizophrenia: update 2012. *Mol Psychiatry* 2012; 17:1228-1238
44. Richard V, Viallon J & Cao-Lormeau VM: Use of Centrifugal Filter Devices to Concentrate Dengue Virus in Mosquito per os Infection Experiments. *PLoS One* 2015; 10:e0138161
45. Robinson DG, Woerner MG, McMeniman M, Mendelowitz A & Bilder RM: Symptomatic and functional recovery from a first episode of schizophrenia or schizoaffective disorder. *Am J Psychiatry* 2004; 161:473-479
46. Ruzic Barsic AR, Rubesa G, Mance D, Miletic D, Gudelj L, Antulov R: Influence Of Psychotic Episodes On Grey Matter Volume Changes In Patients With Schizophrenia. *Psychiatr Danub* 2020; Article in Press
47. Schnieder TP & Dwork AJ: Searching for neuropathology: gliosis in schizophrenia. *Biol Psychiatry* 2011; 69:134-139
48. Sharp FR, Tomitaka M, Bernaudin M & Tomitaka S: Psychosis: pathological activation of limbic thalamocortical circuits by psychomimetics and schizophrenia? *Trends Neurosci* 2001; 24:330-334
49. Shenton ME, Dickey CC, Frumin M & McCarley RW: A review of MRI findings in schizophrenia. *Schizophr Res* 2001; 49:1-52
50. Sowell ER, Thompson PM, Holmes CJ, Batth R, Jernigan TL & Toga AW: Localizing Age-Related Changes in Brain Structure between Childhood and Adolescence Using Statistical Parametric Mapping. *NeuroImage* 1999; 9:587-597.
51. Sowell ER, Thompson PM, Holmes CJ, Jernigan TL & Toga AW: In vivo evidence for post-adolescent brain maturation in frontal and striatal regions. *Nat Neurosci* 1999; 2:859-861
52. Spear LP: The adolescent brain and age-related behavioral manifestations. *Neurosci Biobehav Rev* 2000; 24:417-463
53. Tuominen HJ, Tiihonen J & Wahlbeck K: Glutamatergic drugs for schizophrenia: a systematic review and meta-analysis. *Schizophr Res* 2005; 72:225-234
54. Uhlhaas PJ: The adolescent brain: implications for the understanding, pathophysiology, and treatment of schizophrenia. *Schizophrenia bulletin* 2011; 37:480-483
55. Viallon M, Cuvinciuc V, Delattre B, Merlini L, Barnaure-Nachbar I, Toso-Patel S et al.: Erratum to: State-of-the-art MRI techniques in neuroradiology: principles, pitfalls, and clinical applications. *Neuroradiology* 2015; 57:1075
56. Wang J, Zhou L, Cui C, Liu Z & Lu J: Gray matter morphological anomalies in the cerebellar vermis in first-episode schizophrenia patients with cognitive deficits. *BMC Psychiatry* 2017; 17:374
57. Weinberger DR: Implications of normal brain development for the pathogenesis of schizophrenia. *Arch Gen Psychiatry* 1987; 44:660-669
58. White T, Cullen K, Rohrer LM, Karatekin C, Luciana M, Schmidt M et al.: Limbic Structures and Networks in Children and Adolescents With Schizophrenia. *Schizophrenia Bulletin* 2007; 34:18-29
59. Wiser AK, Andreasen NC, O'Leary DS, Watkins GL, Boles Ponto LL & Hichwa RD: Dysfunctional cortico-cerebellar circuits cause 'cognitive dysmetria' in schizophrenia. *Neuroreport* 1998; 9:1895-1899
60. Wyatt RJ: Neuroleptics and the natural course of schizophrenia. *Schizophr Bull* 1991; 17:325-351
61. Wylie KP & Tregellas JR: The role of the insula in schizophrenia. *Schizophr Res* 2010; 123:93-104

Correspondence:

Antonija Ružić Baršić, MD
Department of Radiology, Thalassotherapia Opatija
Maršala Tita 188/1, 51 410 Opatija, Croatia
E-mail: antonija.ruzic.b@gmail.com