

The first Croatian pediatric patient with *Geotrichum capitatum* respiratory infection

Prvi hrvatski pedijatrijski bolesnik s *Geotrichum capitatum* respiratornom infekcijom

Joško MARKIĆ^{1, 3)}
Branka POLIĆ¹⁾
Tanja KOVAČEVIĆ¹⁾
Daniela VELJAČIĆ¹⁾
Ivana GOIĆ-BARIŠIĆ^{2, 3)}
Marija TONKIĆ^{2, 3)}

¹⁾University Hospital of Split, Department of Pediatrics, Spinciceva 1, 21000 Split, Croatia

²⁾University Hospital of Split, Department of Clinical Microbiology, Spinciceva 1, 21000 Split, Croatia

³⁾University of Split, School of Medicine, Soltanska 2, 21000 Split, Croatia

Key words

Geotrichum capitatum
pneumonia
treatment
invasive fungal infection

Key words

Geotrichum capitatum
pneumonija
liječenje
invazivna gljivična infekcija

Primljeno: 2016–04–07

Received: 2016–04–07

Prihvaćeno: 2016–05–15

Accepted: 2016–05–15

Introduction

Geotrichum capitatum is a filamentous yeast-like fungus formerly known as *Trichosporon capitatum* or *Blastoschizomyces capitatus*. Although it can be a part of the normal microbiota it can also cause both superficial and invasive infections in humans [1, 2]. It forms creamy, wrinkled colonies that grow on conventional media such as Sabouraud dextrose agar [1]. It is occasionally encountered in clinical laboratories and its importance as systemic pathogen has recently been recognized in patients with immunosuppressive conditions [3]. Studies have

Case report

Geotrichum capitatum can cause infections in humans and its importance has recently been recognized in patients with immunosuppressive conditions. In this report we present the first Croatian pediatric patient with pneumonia in whom *G. capitatum* was isolated in three sequential bronchoalveolar lavage and tracheal aspiration specimens.

Prikaz bolesnika

Geotrichum capitatum može uzrokovati infekcije u ljudi i njegov značaj je nedavno prepoznat u imunosuprimiranih bolesnika. U ovom radu prikazujemo prvog hrvatskog pedijatrijskog bolesnika s pneumonijom u kojeg je *G. capitatum* izoliran u tri uzastopna bronhoalveolarna lavata i aspirata traheje.

shown that there is a significantly higher frequency of infections caused by *G. capitatum* in Europe, with majority of them occurring in Italy, Spain, and France [4]. Since most cases were located in central and southern Europe, it seems that the epidemiology of *G. capitatum* infections could be influenced by climatic factors. The mortality in patients with *G. capitatum* infections is high (60 %) [5].

In this report we present, to our knowledge, the first pediatric patient from Croatia in whom the *Geotrichum capitatum* was isolated in three sequential bronchoalveolar lavage (BAL) and tracheal aspiration specimens.

Case report

A 6-year-old boy was referred to the University Hospital of Split with a two and a half week intermittent fever duration. He was born after an uneventful pregnancy and soon after the birth was diagnosed with multiformation syndrome (frontal bossing, low posterior hairline, dysplastic ears, flat nasal bridge, gingival hyperplasia, irregular dentition, high-arched palate) and early epileptic encephalopathy (seizures with delayed psychomotor development – unable to walk, minimal visual contact, severe speech impairment). His previous hospitalization in our Department was a year before due to pneumonia and respiratory insufficiency. During that hospitalization he was mechanically ventilated for 9 days. He was discharged home with his regular anticonvulsive therapy and the parents were educated to administer noninvasive ventilatory support. His present illness started 17 days prior to hospitalization with fever and upper respiratory tract infection symptoms. The boy was examined by his primary care physician who prescribed amoxicillin oral suspension. After eight days of antimicrobial treatment his condition improved. However, three days before the hospital admission he became febrile up to 40.0 °C with increased respiratory effort. He was clinically reexamined by his primary care physician the day later. Laboratory blood tests were done (L 14.5 G/L, CRP 67.0 mg/L) and ce-

fixime oral suspension was administered. Despite the antimicrobial therapy he continued to be febrile, drank poor and became less responsive to stimuli. He was brought to our pediatric emergency room and subsequently admitted to the pediatric intensive care unit (PICU) with signs of shock requiring appropriate fluid resuscitation therapy and inotropic support. Laboratory tests showed mild leukocytosis ($12.8 \times 10^9/L$), anemia (hemoglobin 90 g/L; hematocrit 0.32) and moderately increased CRP (89.7 mg/L). Chest X-ray (Figure 1.) confirmed rightsided bronchopneumonia with complete atelectasis of the left lung. His regular chronic therapy was continued and parenteral antimicrobial therapy with ceftriaxone was initiated.

Despite the intense inhalational and other symptomatic therapy, his respiratory condition worsened. Therefore, he was sedated, intubated and mechanical ventilation was initiated. Because of the atelectasis and thick and abundant secretion in his lower airways, in addition to regular physical respiratory therapy and frequent tracheal aspiration, an aspiration of lower airways with fiberoptic bronchoscope was also done and the first BAL specimen was sent for microbiology analysis. He was fed by parenteral nutrition. The following day, due to further increase of inflammatory biomarkers (procalcitonin >100 ng/mL), parenteral meropenem was administered. He was also given a blood transfusion. Three days later, *Geotrichum capitatum*

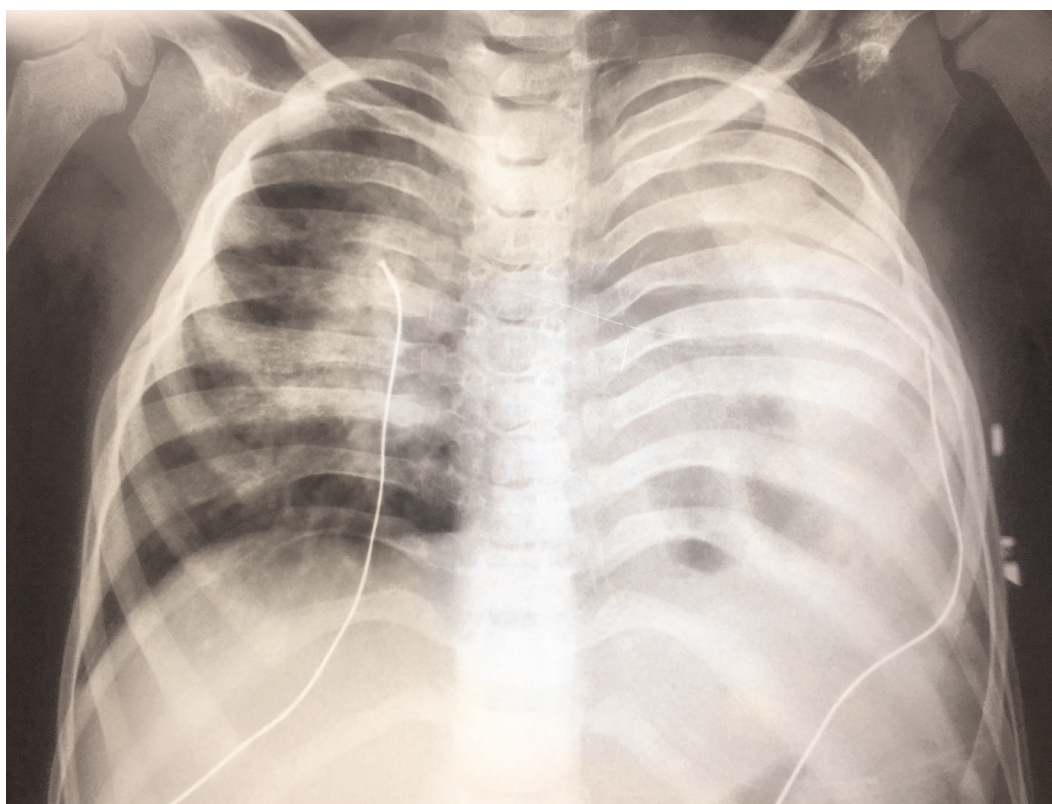


Figure 1. Chest x-ray at the time of hospital admission

Slika 1. Radiogram pluća u vrijeme prijema u bolnicu

and *Candida albicans* were confirmed in BAL and fluconazole was administered. BAL specimens were cultured on blood agar, Sabouraud agar (Merck KGaA, Darmstadt, Germany) and CHROMagar Candida (CHROMagar Orientation, Paris, France). After 24 hours of incubation on two temperature conditions (25 °C and 36 °C) two types of colonies were revealed. The total number of growing colonies was $> 10^5$ colony forming units (CFU)/ml of BAL. On the CHROMagar Candida media green colonies of *Candida albicans* were positive in germ tube formation, confirming *Candida albicans* identification. On the Sabouraud agar different type of cream coloured dry and wrinkled colonies were observed. These colonies showed no germ tube formation. Microscopic view and microcultivations on cornmeal agar (25 °C and 35 °C) revealed abundant thin, septate filaments with multiple rectangular arthroconidia and the absence of blastoconidia and chlamydospores. The isolate was identified as *G. capitatum* according to the biochemical patterns obtained by the VITEK 2 System (bioMérieux, Marcy-l'Etoile, France) using YST card. Gradually, his condition improved and inotropic support was discontinued. *Candida albicans* and *Geotrichum capitatum* were again isolated in the second BAL taken two days later. Therefore, fluconazole was replaced with intravenous amphotericin B and voriconazole. At the same time, coagulase negative *Staphylococcus* sp. was isolated from the blood culture and teicoplanin was administered as well. The patient's condition continued to improve but we were not able to wean him of the mechanical ventilation. By the end of the second week of treatment he again became hemodynamically unstable with symptoms and laboratory signs (L $15.7 \times 10^9/L$; CRP 299.4 mg/L; procalcitonin 3.95 ng/mL) of sepsis requiring inotropic support. Eight days after initiation of amphotericin B and voriconazole treatment, *G. capitatum* was isolated again, this time from tracheal aspirate specimen. Blood culture was sterile. Amikacin and micafungin were added to the treatment regime. However, his condition continued to deteriorate with further increase of inflammatory biomarkers (CRP 377.1 mg/L, procalcitonin 81.65 ng/mL). Despite all intensive treatment and therapy, on the 18th day, he developed bradycardia leading to asystole and death.

Discussion

In this report we describe the first Croatian pediatric non-hematologic patient with pulmonary infection caused by *Geotrichum capitatum*. Prior to hospitalization the patient was treated with oral antibiotics and admitted to PICU requiring mechanical ventilation and intensive treatment.

Fungi are part of normal microbiota and some of them are considered nonpathogenic. However, they can cause systemic infections in patients that are severely immuno-

compromised due to illness or therapy with immunosuppressive drugs [6]. Most fungal infections are caused by *Candida* spp., but the frequency of other rare molds and unusual yeasts is increasing. Risk factors for fungal infections include hospitalization in ICU, prolonged therapy with broad-spectrum antibiotics and steroids, central venous catheter, total parenteral nutrition, neutropenia and previous colonisation [6, 7, 8].

Geotrichum capitatum has emerged as a fungal pathogen in recent years. Invasive fungal infections caused by this agent are often characterized by a multiorgan involvement with a fatal course despite antifungal therapy. Numerous studies have shown increased occurrence of *Geotrichum capitatum* infection in patients with impaired immune response to infection [3, 4, 9]. In a study that involved 353 immunocompromised patients over a 37 months period, colonisation and infection by *G. capitatum* was found in 3.7% of them [3]. Most of the studies published so far have described the infection caused by *G. capitatum* in adult patients, but some of them also described infection with this pathogen in immunocompromised children [9, 10]. Infection is also possible in immunocompetent patients. Usually it will affect middle to older-aged males with underlying lung pathology (chronic obstructive pulmonary disease, tuberculosis) or with risk factors like smoking or previous transplantation [11].

The pulmonary localization is commonly reported in *G. capitatum* septicemia and the radiological signs resemble those found in invasive pulmonary aspergillosis [4].

In our patient, laboratory and clinical signs strongly suggest that *G. capitatum* and *C. albicans* were cause of respiratory tract infection. They were not isolated from blood cultures. Since the susceptibility testing of *G. capitatum* has not yet been established due to the absence of breakpoints, the treatment of these infections is based on empirical therapy according to limited available literature data.

Currently, there are no official guidelines concerning the most effective antifungal therapy for *G. capitatum* infection. The therapy with azoles is widely used as effective in the treatment of yeast infections. It is also suggested that azoles should be used as first-line agents in patients like ours [11]. However, our initial antimicrobial therapy with fluconazole seemed to be inefficient. This may be due to resistance or decreased susceptibility of *G. capitatum* to fluconazole. Therefore, fluconazole was replaced with voriconazole and amphotericin B combination therapy. Based on limited clinical data available, amphotericin B and voriconazole are also recommended to be used, alone or in combination. Some authors reported poor susceptibility of some strains to flucytosine, fluconazole and itraconazole [4]. However, in our patient, this combination therapy eradicated *C. albicans*, but *G. capitatum* remained positive in tracheal aspiration specimen. There-

fore, further studies evaluating optimal treatment, dosage and duration of therapy are warranted. It may be possible that failure of antimycotic treatment, combined with other factors, such as underlying diseases, hospitalization in PICU and concomitant bacterial sepsis, could be the reasons for undiserable outcome.

A retrospective study and review published in 2005 has shown that the majority of infections caused by *G. capitatum* occurred in Europe, mostly in the Mediterranean area to which Croatia belongs [4]. Therefore, physicians practicing in this area have to consider *G. capitatum* as a possible cause of infection if an immunocompromised or even immunocompetent patient shows signs of persistent infection despite the broad spectrum antibacterial therapy.

Although this is, to our knowledge, the first described case of *G. capitatum* infection in a pediatric patient from Croatia, pediatricians should take into consideration this filamentous yeast-like fungus as a possible cause of infection as well.

Conflict of interest

The authors declare no conflict of interest.

References

- [1] D'Antonio D, Mazzoni A, Iacone A et al. Emergence of fluconazole-resistant strains of *Blastoschizomyces capitatus* causing nosocomial infections in cancer patients. *J Clin Microbiol* 1996; 34: 753–755.
- [2] Radić M, Goić-Barišić I, Kušćević D, Novak A, Tonkić M, Rubić Ž. *Geotrichum capitatum* respiratory tract infection in a patient with polytrauma. *Infez Med* 2015; 3: 270–274.
- [3] Haupt HM, Merz WG, Beschoner WE, Vaughan WP, Saral R. Colonization and infection with *Trichosporon* species in the immunosuppressed host. *J Infect Dis* 1983; 147: 199–203.
- [4] Girmenia C, Pagano L, Martino B et al. Invasive Infections Caused by *Trichosporon* Species and *Geotrichum capitatum* in Patients with Hematological Malignancies: a Retrospective Multicenter Study from Italy and Review of the Literature. *J Clin Microbiol Infect* 2005; 43: 1818–1828.
- [5] Darles C, Pons S, Gaillard T, Roméo E, Brisou P. Infection disseminée a *Geotrichum capitatum*. *Med Mal Infect* 2012; 42: 574–575.
- [6] Fridkin SK, Jarvis WR. Epidemiology of nosocomial fungal infections. *Clin Microbiol Rev*, 1996; 9: 499–511.
- [7] Nedel WL, Moraes VD, Falci DR, Pasqualotto AC. *Geotrichum capitatum* fungaemia: an unusual pathogen in critically-ill-related infections. *Anaesth Intensive Care* 2013; 41: 685–687.
- [8] Ersoz G, Otag F, Erturan Z et al. An outbreak of *Dipodascus capitatus* infection in the ICU: Three case reports and review of the literature. *Jpn J Infect Dis* 2004; 57: 248–252.
- [9] Yilmaz Karapınara D, Karadaş N, Önder Siviş Z et al. Case report: Rare severe mycotic infections in children receiving empirical caspofungin treatment for febrile neutropenia. *Braz J Infect Dis* 2015; 19(5): 549–552.
- [10] Saghrouni F, Abdeljelil JB, Youssef YB et al. *Geotrichum capitatum* septicemia in patients with acute myeloid leukemia. Report of three cases. *Med Mycol Case Re*, 2012; 1: 88–90.
- [11] Tanabe MB, Patel SA. *Blastoschizomyces capitatus* pulmonary infections in immunocompetent patients: case report, case series and literature review. *Epidemiol Infect* 2018; 146: 58–64.