

Preoperative Mapping of Primary Motor and Broca's Area with Transcranial Magnetic Stimulation (TMS) – Case Report

Maja Rogić Vidaković^{1*} and Igor Vujović²

¹Laboratory for Human and Experimental Neurophysiology (LAHEN), Department of Neuroscience, School of Medicine, University of Split, Šoltanska 2, 21000 Split, Croatia

²Signal Processing, Analysis and Advanced Diagnostics Research and Education Laboratory (SPAADREL), Faculty of Maritime Studies, University of Split, Ruđera Boškovića 37, 21 000 Split, Croatia

*Correspondence to:

Maja Rogić Vidaković, PhD
Laboratory for Human and Experimental
Neurophysiology (LAHEN)
Department of Neuroscience
School of Medicine University of Split
Šoltanska 2, 21000 Split, Croatia
Tel: +385(0)21 557 871, +385(0)98 508210
Fax: +385 (0)21 557 955
E-mail: maja.rogic@mefst.hr

Received: February 27, 2017

Accepted: May 05, 2017

Published: May 09, 2017

Citation: Rogić Vidaković M, Vujović I. 2017. Preoperative Mapping of Primary Motor and Broca's Area with Transcranial Magnetic Stimulation (TMS) – Case Report. *J Neurol Exp Neurosci* 3(1): 25-28.

Copyright: © 2017 Rogić Vidaković and Vujović. This is an Open Access article distributed under the terms of the Creative Commons Attribution 4.0 International License (CC-BY) (<http://creativecommons.org/licenses/by/4.0/>) which permits commercial use, including reproduction, adaptation, and distribution of the article provided the original author and source are credited.

Published by United Scientific Group

Abstract

The transcranial magnetic stimulation (TMS) methodology for mapping the primary motor cortex (M1) for laryngeal muscles and Broca's area was recently established on group of healthy subjects. Here we present the first patient with tumor in the frontal cortex of the left hemisphere that underwent mapping of M1 and Broca's area as a part of preoperative neurosurgical planning. The TMS findings greatly facilitated awake brain surgery of these crucial motor speech cortical areas. Future studies are needed on group of patients undergoing TMS mappings of the (M1) for laryngeal muscles and Broca's area with intraoperative testing with electrical cortical stimulation.

Keywords

TMS, Primary motor cortex, Speech, Laryngeal muscles, Evoked responses

Introduction

Navigated transcranial magnetic stimulation (nTMS) is a non-invasive technique increasingly used for pre-surgical motor and language/speech mapping in patients with brain lesions [1, 2]. Repetitive navigated transcranial magnetic stimulation (rTMS) is increasingly used for language mapping in combination with functional magnetic resonance imaging (fMRI) for preoperative mapping of patients undergoing neurosurgical operation [3]. The results of rTMS language mapping were correlated to direct cortical stimulation (DCS) during awake brain surgery [2], which is currently the most accurate, gold-standard method for the localization of language related cortical areas. The majority of the studies used rTMS as a virtual lesion model to investigate the contribution of specific cortical areas to language processing by inducing various types of language errors [4, 5]. Recently our group developed the nTMS methodology along with the intraoperative methodology for mapping motor speech related cortical areas (primary motor cortex (M1) for laryngeal muscles and caudal opercular part of inferior frontal gyrus (corresponding to Broca's area) by recording evoked potentials from laryngeal muscle [6-8]. The modified patterned rTMS protocol was used to map the M1 for laryngeal muscles while recording corticobulbar motor evoked potentials (CoMEPs) from cricothyroid muscle. Stimulation over the M1 for the cricothyroid muscle elicited CoMEPs in contralateral cricothyroid muscle with a latency of 11.89 ± 1.26 ms. Stimulation over the opercular part of Broca's area elicited long latency response (LLR) in contralateral cricothyroid muscle with a latency of 58.5 ± 5.9 ms. Magnetic stimulation of these motor speech related cortical areas, which generated responses in laryngeal muscles, also elicited transient speech impairments. The CoMEP can be regarded as a

neurophysiologic marker of M1 for laryngeal muscles, while LLR the most likely neurophysiologic marker of premotor speech cortex, according to the following evidence:

- The CoMEPs are elicited from the vocal and cricothyroid muscles during electrical and magnetic stimulation of the M1 for laryngeal muscles in a group of patients and healthy subjects [6, 9-11].

- The nTMS and DCS of cortical spot, which elicited CoMEP, clinically produced dysarthric speech.

- The M1 for laryngeal muscles is anatomically represented at the most lateral part of M1. The distance between the cortical representation of M1 for hand muscle representation and M1 for cricothyroid muscle was 25.19 ± 6.51 mm, with cricothyroid muscle lateral to hand muscle representation [6].

- DCS and nTMS of the stimulated cortical spot, which elicited LLR, clinically produced speech arrest in all patients and speech arrest and/or language disturbances in healthy subjects. Anatomically, this cortical spot corresponds to a small region of the caudal opercular inferior frontal gyrus detectable on an MRI of healthy subjects and in the patients by intraoperative inspection.

- After electrical stimulation of Broca's area, postsynaptic potentials of high amplitude can be recorded in the lateral part of the M1 [12]. These data can be regarded as indirect evidence of an anatomical connection between the premotor cortex in the caudal opercular part of inferior frontal gyrus and M1 for laryngeal muscle. There are also possible contributions of other pathways to LLR origin, other than through M1. Therefore, the differences in the latencies indicate functional anatomy of the M1 for laryngeal muscles (CoMEP), and the premotor cortex in the caudal opercular part of inferior frontal gyrus (LLR) [7]. This nTMS methodology for mapping motor speech areas was developed on a group of healthy subjects, while intraoperative methodology with DCS was developed on patients operated in Bellvitge Hospital in Barcelona, Spain [7]. Our patient, aged 44, is the first patient in whom motor speech areas were preoperatively mapped with nTMS by applying developed preoperative methodology.

Case Report

We report on the case of a 44-year old right handed woman in whom a tumor (glioblastoma) was diagnosed on December 24, year 2015 at the Department of Neurosurgery at the Clinical Medical Centre "Sisters of Mercy" in Zagreb, Croatia. The patient had an epileptic seizure ten days before the administration to the hospital. After the first epileptic seizure, the patient had two more seizures. The seizures were preceded by expressive (motor) dysphasia. The medication was introduced (methylphenobarbital and carbamazepine). Magnetic resonance imaging (MRI) of the patient's head was performed with Simenes Avanto 1.5 T. The MRI images were obtained to suit the nTMS requirements, integrated in the nTMS system and used for the 3-D reconstruction of individual's brain [13]. The tumor size was 4 x 4 cm (Figure 1). Speech and language functions were tested by qualified speech and language pathologist (one of the authors of the study).

Receptive language functions were mainly preserved, with slight difficulties in speech fluency and word retrieval during spontaneous speech.

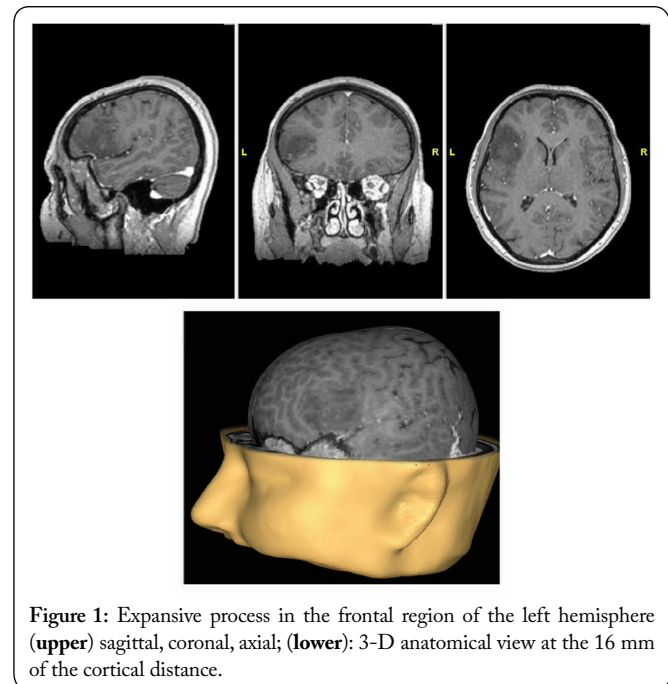


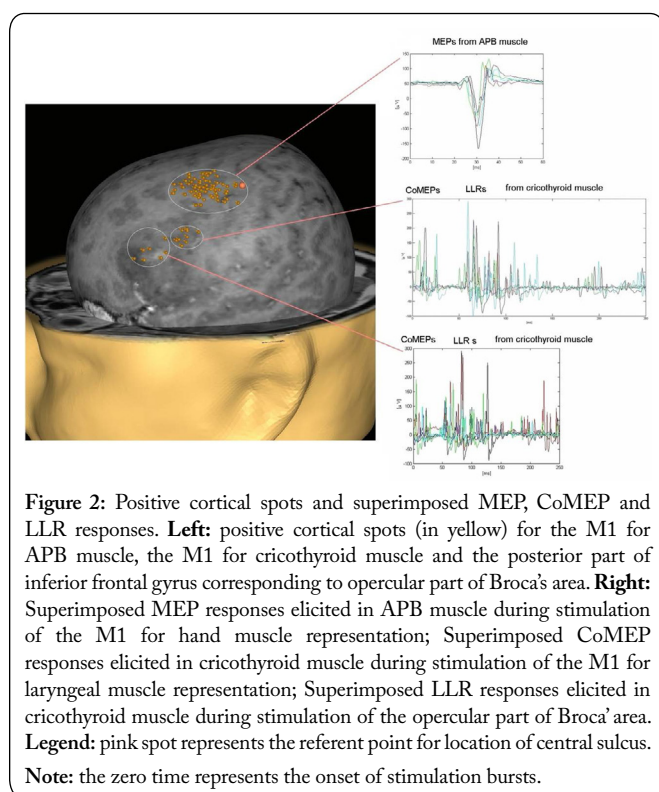
Figure 1: Expansive process in the frontal region of the left hemisphere (**upper**) sagittal, coronal, axial; (**lower**): 3-D anatomical view at the 16 mm of the cortical distance.

The nTMS mapping was performed by using the eXimia NBS 4.1. (Nexstim Ltd., Helsinki, Finland) system. The patient wore an optical head tracker and by using a pointer, twelve scalp points were registered to the 3D rendering. The nTMS system used a stereotactic navigation camera (3D optical tracking unit; Polaris® Vicra) to track the coil position with respect to the patient's head. The stimulation was delivered through a Nexstim Cooled coil cooling system (height 25 cm, width 22 cm, depth 47 cm). The figure-of-eight coil of a winding diameter of 50 mm, and outer winding diameter of 70 mm was used.

The surface electromyography electrodes (Ambu® Blue Sensor BR, BR-50-K/12) were attached in a belly tendon fashion over the right hand muscle (abductor pollicis brevis (APB) and the hook wire electrodes (SGM d.o.o Croatia) were introduced into the right laryngeal, cricothyroid muscle according to published methodology [6]. Single magnetic pulse was used for mapping the left M1 for hand muscles, while modified patterned rTMS protocol consisting of 4 bursts of 4 stimuli each, with an interstimulus interval of 6 ms, and a burst repetition rate of 4 Hz [8] was used for mapping motor speech areas: the left M1 for laryngeal muscles and the posterior part of the inferior frontal gyrus corresponding to the opercular part of the Broca's area. The patient performed a visual object naming task during mapping of the M1 for laryngeal muscles and the Broca's area, which was synchronized with the stimulation onset and controlled via presentation software Presentation® (©Neurobehavioural Systems, Inc., version 14.7 11.10.10), running a custom made script.

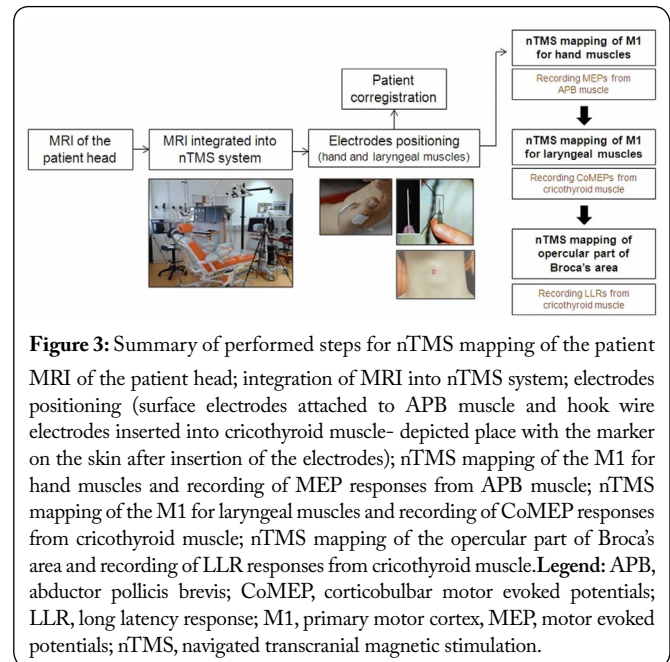
The surface electromyography electrodes were attached over the right APB with the ground electrode over the dorsal surface of the right APB muscle. The resting motor

threshold (RMT) was determined by mapping the M1 of the left hemisphere for the representation of APB muscle, as a standard referent measure in TMS studies [14]. The RMT of the patient was defined as the minimal intensity of the stimulator output that elicited a MEP response > 50 µV peak-to-peak amplitude in at least 5 of 10 consecutive trails and was at 34 % of the maximum stimulator output. The latency of the MEP was 22.7 ms and the amplitude of 220.06 µV. The CoMEP responses were recorded in the cricothyroid muscle with the latency of 9.14 ms by using the intensity of 35 % of the maximum stimulator output applied to the M1 for laryngeal muscles, while LLR responses were recorded from the cricothyroid muscle with the latency of 54.94 ms with the intensity of 34% of maximum stimulator output applied to the posterior part of inferior frontal gyrus. The positive cortical spots and repeatability of MEP, CoMEP and LLR responses are shown on Figure 2 as superimposed responses. Figure 3 represents the summary timeline of performed steps for nTMS mapping of the patient.



Two weeks after the nTMS mapping the patient was operated at the Department of Neurosurgery, Clinical Medical Centre "Sisters of Mercy" in Zagreb, while being awake with intraoperative DCS methodology for mapping the M1 for laryngeal muscles and Broca's area [7]. The CoMEPs and LLR were preserved during the course of operation. The DCS of the opercular part of the inferior frontal gyrus toward the precentral gyrus and over the rostral part of the tumor (Broca's area) elicited LLR responses (corresponding to nTMS mapping), while stimulation of the M1 for laryngeal muscles (lateral part of the M1) elicited CoMEPs from laryngeal muscle. The same LLR cortical spots elicited speech arrest. Maximal tumour resection was performed while avoiding CoMEP and LLR spots. According to the final histological

result the tumour was classified as oligodendrolioma (WHO gr. II, Ki-67=7%). The patient's motor/expressive speech was preserved and one month postoperatively the patient retained slight difficulties in speech fluency and word retrieval during spontaneous speech, similar as in preoperative difficulties.



Discussion

We reported the mapping results of the M1 for laryngeal muscles and Broca's area with nTMS methodology performed on the first patient undergoing awake brain surgery. We have successfully applied recently developed methodology in healthy subjects [6-8] for mapping the M1 for laryngeal muscles and opercular part of Broca's area in the first patient with tumor in the frontal cortex of the left hemisphere invading the Broca's area and the lateral part of the M1 cortex. The findings of preoperative nTMS served the neurosurgeon as the guide for planning the operation. The positive CoMEP and LLR spots detected by nTMS mapping are placed on the patient MRI and transferred to the neurosurgical unit in the operating room.

The mapping of the M1 for hand muscles and MEP recording is already the standard methodology for testing the integrity of the corticospinal tract, especially in neurological and neurosurgical departments. The clarification of the mechanisms of CoMEP and LLR generation was previously given [7] and a short explanation is provided further in the text. The coded signal is transmitted from the posterior part of the inferior frontal gyrus to the M1 motoneurons involved in the motor speech execution, and from there the signal gets transmitted via corticobulbar pathways to the motoneurons in the brainstem (vagal nuclei), and from there, via cranial nerves (recurrent laryngeal nerve and superior laryngeal nerve), to speech target muscles (laryngeal muscles). The excitability of the M1 for laryngeal muscles and Broca's can be facilitated while the patient is participating in speech task and we can

induce synchronized activity of their neurons and record this activity in the laryngeal muscles as CoMEP and LLR, depending on the neural structure being stimulated. Most probably, more synapses are implicated when stimulating the Broca's area compared to the M1 for laryngeal muscles, therefore the latency and the jittering of the LLR is more pronounced compared to CoMEP. Even though we did not test the right hemisphere in this patient since the pathology was located in the left hemisphere, it is possible to elicit LLR by stimulation of the non-dominant hemisphere according to intraoperative data of Deletis et al. [11]. Furthermore, due to the close vicinity of the M1 for laryngeal muscles and the Broca's area [8], it is possible to elicit both responses (CoMEPs and LLRs) from laryngeal muscles while stimulating these areas (Figure 2).

At the moment there are no studies with group of patients undergoing the nTMS and awake brain surgery for testing the M1 for laryngeal muscles and Broca's area. Therefore, we believe future studies will report on the benefits of mapping of these motor speech cortical areas in patients with different brain pathologies (i.e. tumor process, arteriovascular malformations). Furthermore, future studies might correlate preoperative, intraoperative and postoperative speech status in patients operated on during awake brain surgery (with application of intraoperative methodology for eliciting CoMEPs and LLRs from laryngeal muscles while mapping M1 for laryngeal muscles and Broca's area) [7, 9-11] with and without preoperative nTMS mappings. Ultimately, future studies may correlate findings of fMRI protocols with this recent nTMS methodology for preoperative mapping of the M1 and Broca's area.

Disclosure Statement

The authors declare no conflict of interest

References

1. Tarapore PE, Picht T, Bulbas L, Shin Y, Kulchytska N, et al. 2016. Safety and tolerability of navigated TMS for preoperative mapping in neurosurgical patients. *Clin Neurophysiol* 127(3): 1895-1900. <https://doi.org/10.1016/j.clinph.2015.11.042>
2. Picht T, Krieg SM, Sollmann N, Rosler J, Niraula B, et al. 2013. A comparison of language mapping by preoperative navigated transcranial magnetic stimulation and direct cortical stimulation during awake surgery. *Neurosurgery* 72(5): 808-819. <https://doi.org/10.1227/NEU.0b013e3182889e01>
3. Ille S, Sollmann N, Hauck T, Maurer S, Tanigawa N, et al. 2015. Impairment of preoperative language mapping by lesion location: a functional magnetic resonance imaging, navigated transcranial magnetic stimulation, and direct cortical stimulation study. *J Neurosurg* 123: 314-324. <https://doi.org/10.3171/2014.10.JNS141582>
4. Pascual-Leone A, Gates JR, Dhuna A. 1991. Induction of speech arrest and counting errors with rapid-rate transcranial magnetic stimulation. *Neurology* 41(5): 697-702. <https://doi.org/10.1212/WNL.41.5.697>
5. Sollmann N, Hauck T, Hapfelmeier A, Meyer B, Ringel F, et al. 2013. Intra- and interobserver variability of language mapping by navigated transcranial magnetic brain stimulation. *BMC Neurosci* 14: 150. <https://doi.org/10.1186/1471-2202-14-150>
6. Espadaler J, Rogić M, Deletis V, Leon A, Quijada C, et al. 2012. Representation of cricothyroid muscles at the primary motor cortex (M1) in healthy subjects, mapped by navigated transcranial magnetic stimulation (nTMS). *Clin Neurophysiol* 123(11): 2205-2211. <https://doi.org/10.1016/j.clinph.2012.04.008>
7. Deletis V, Rogić M, Fernández-Conejero I, Gabarrós A, Jerončić A. 2014. Neurophysiologic markers in laryngeal muscles indicate functional anatomy of laryngeal primary motor cortex and premotor cortex in the caudal opercular part of inferior frontal gyrus. *Clin Neurophysiol* 125(9): 1912-1922. <https://doi.org/10.1016/j.clinph.2014.01.023>
8. Rogić M, Deletis V, Fernández-Conejero I. 2014. Inducing transient language disruptions by mapping of Broca's area with modified patterned repetitive transcranial magnetic stimulation protocol. *J Neurosurg* 120(5): 1033-1041. <https://doi.org/10.3171/2013.11.JNS13952>
9. Deletis V, Ulkatan S, Cioni B, Meglio M, Colicchio G, et al. 2008. Responses elicited in the vocalis muscles after electrical stimulation of motor speech areas. *Rivista Medica* 14(2): 159-165.
10. Deletis V, Fernandez-Conejero I, Ulkatan S, Costantino P. 2009. Methodology for intraoperatively eliciting motor evoked potentials in the vocal muscles by electrical stimulation of the corticobulbar tract. *Clin Neurophysiol* 120(2): 336-341. <https://doi.org/10.1016/j.clinph.2008.11.013>
11. Deletis V, Fernández-Conejero I, Ulkatan S, Rogić M, Carbó EL, et al. 2011. Methodology for intraoperative recording of the corticobulbar motor evoked potentials from cricothyroid muscles. *Clin Neurophysiol* 122(9): 1883-1889. <https://doi.org/10.1016/j.clinph.2011.02.018>
12. Greenlee JD, Oxa H, Kawasaki H, Volkov IO, Kaufman OP et al. 2004. A functional connection between inferior frontal gyrus and orofacial motor cortex in human. *J Neurophysiol* 92(2): 1153-1164. <https://doi.org/10.1152/jn.00609.2003>
13. Ruohonen J, Karhu J. 2010. Navigated transcranial magnetic stimulation. *Neurophysiol Clin* 40(1): 7-17. <https://doi.org/10.1016/j.neucli.2010.01.006>
14. Schmidt S, Cichy RM, Kraft A, Brocke J, Irlbacher K, et al. 2009. An initial transient state and reliable measures of corticospinal excitability in TMS studies. *Clin Neurophysiol* 120(5): 987-993. <https://doi.org/10.1016/j.clinph.2009.02.164>