

# Failure of bulk bone grafts after total hip arthroplasty for hip dysplasia

Domagoj Delimar · Ana Aljinovic · Goran Bicanic

Received: 22 January 2014  
© Springer-Verlag Berlin Heidelberg 2014

## Abstract

**Introduction** Bulk bone grafts are used in total hip arthroplasty (THA) when adequate acetabular cup coverage cannot be achieved. Data from literature show mainly good short-term and mid-term results with contradictory long-term results. The aim of this study was to investigate acetabular cup stability and graft integrity after dysplastic adult hip reconstruction with total hip endoprosthesis and bulk bone graft for acetabular deficiency.

**Methods** Seventy-two hips in 64 patients that underwent THA with bone autograft or allograft were assessed immediately after operation, 6 months and 1, 2, 3 and 10 years after operation. Acetabular angle, acetabular cup coverage, bone graft width, and bone graft height were measured and questionnaire was designed to determine acetabular cup stability and grade graft integrity. Four investigators graded grafts and inter-rater and intra-rater reliability of the questionnaire was tested.

**Results** All measured parameters in all patients and in patients with autograft and those with allograft separately showed significant changes consistent with graft failure and acetabular cup instability when level of significance was set at  $p < 0.05$ .

**Conclusions** Results of this study show significant decrease in acetabular cup stability when either autograft or allograft is used for cemented acetabular reconstruction

of dysplastic hip. Further, allografts showed twice as rapid failure as autografts. Although these results contradict both good short-term and long-term results in published literature, they present warning for future use of free bulk bone grafts in reconstructive hip surgery.

**Keywords** Hip · Arthroplasty · Bone graft · Dysplasia

## Introduction

Reconstructive hip surgery in patients with secondary osteoarthritis due to hip dysplasia is a challenging orthopedic procedure. Dysplastic acetabulum is usually small and shallow with superolateral defect [1] that makes proper placement of acetabular component difficult and challenges primary and secondary endoprosthesis stability. Several techniques have been described to achieve adequate superolateral coverage and  $<45^\circ$  of acetabular cup inclination, such as placement of the cup cranial to the true acetabulum [2], medialisation [3], cotyloplasty [1], placement of a small acetabular component [4]. If bone stock in the level of the true acetabulum is inadequate autograft [5–7], allograft [6, 8] or vascularized grafts [9, 10] are used. Here, we have to mention that there is still no consensus on graft survival after total hip arthroplasty (THA) in dysplastic hips. Short-term graft survival is generally described as good [11, 12] although some histological data did not support these findings [13]. Mid-term results are also mainly good [7, 14–16], however, papers with long-term results are not consistent; ranging from sporadic endoprosthesis loosening [17–24] to ones that required revision surgery in high percentage of cases [13, 25].

Therefore, the aim of this study was to analyze acetabular cup stability after autograft or allograft was used for acetabular reconstruction in patients with hip dysplasia.

D. Delimar · G. Bicanic  
Department of Orthopaedic Surgery, University of Zagreb School of Medicine and Clinical Hospital Center Zagreb, Salata 7, 10000 Zagreb, Croatia

A. Aljinovic (✉)  
Department of Orthopaedic Surgery, Clinical Hospital Center Zagreb, Salata 7, 10000 Zagreb, Croatia  
e-mail: ana.aljinovic@gmail.com

## Materials and methods

Seventy-two adult dysplastic hips in 64 patients were consecutively operated between 1985 and 2000 using cemented total hip endoprosthesis by three senior orthopaedic surgeons using direct lateral approach. Dysplastic hips were classified using Crowe [12] classification. Autograft was used in 49 hips and allograft in 23 hips when proper autograft could not be obtained. The aim was to place endoprosthesis as close to ideal center of rotation as possible and to obtain adequate coverage of the acetabular cup with bone graft coverage being maximally 30 %. The size of the graft was determined intraoperatively depending on the achieved acetabular cup coverage. The bone graft was fixed with two fully threaded cancellous bone screws with washers. Placing acetabular cup in position of ideal acetabulum leg length equalization was achieved without femoral shortening. If needed leg length was additionally corrected with different offset and femoral neck length. To evaluate acetabular cup stability and bone graft integrity, three different analysis were performed.

First, to determine radiological stability of the acetabular cup, following parameters were measured: (1) acetabular angle (inclination angle between acetabular cup and horizontal line), (2) cup coverage (angle between line connecting femoral component head center and lateral part of acetabular cup and perpendicular line passing through femoral component head center), and (3) the largest craniocaudal and mediolateral graft diameter (Fig. 1). These measurements were done by single investigator in all patients. All measurements were performed on X-rays immediately after surgery, 6 months after surgery, 1 year after surgery, 2 years after surgery, and 3 years after surgery. All X-rays were performed on a single unit, and all were adjusted for magnification. The magnification was calculated regarding known diameter of the femoral head and all measured parameters were expressed in actual values.

Second, a questionnaire was designed to grade graft integrity (Table 1). Following parameters were assessed; screw loosening, heterotopic ossification as described by Brooker [26], graft porosity compared to iliac bone, bone graft union with iliac bone, graft union with acetabular cup,

**Table 1** Questionnaire designed to grade graft integrity

1.	General graft integrity (VAS)	0–10		
2.	Screw	Broken 1 Broken 2 Does not hold Holds good	6.	Graft union with acetabular cup Sclerotic <1 cm Sclerotic >1 cm Sclerotic in all length Lucent <1 cm Lucent >1 cm Lucent in all length Adequate union
3.	Heterotopic ossification (Brooker)	None Islands Distance great trochanter acetabulum >1 cm Distance great trochanter acetabulum <1 cm	7.	Graft resorption proximally Unchanged Resorbed <0.5 cm Resorbed <1 cm Resorbed >1 cm Resorbed >2 cm Almost entirely resorbed
4.	Graft porosity compared to iliac bone	As normal bone Porotic Sclerotic	8.	Graft resorption laterally Unchanged Resorbed <0.5 cm Resorbed <1 cm Resorbed >1 cm Resorbed >2 cm Almost entirely resorbed
5.	Graft union with iliac bone	Sclerotic <1 cm Sclerotic >1 cm Sclerotic in all length Lucent <1 cm Lucent >1 cm Lucent in all length Adequate union		

graft resorption proximally and laterally. After answering and completing following questions (questions 2–8) from the questionnaire, investigators gave general impression of the graft integrity on VAS scale (question 1). The questionnaire was used by four investigators simultaneously and inter-rater reliability and intra-rater reliability was tested.

The third analysis was performed to assess overall acetabular cup stability and graft survival 10 years after surgery. We declared two or more millimeters of acetabular component cranial migration to be definitive sign of instability. Patients scheduled for revision surgery because of endoprosthesis instability at any point during this study were excluded from further evaluation.

### Statistical methods

Descriptive statistic was used to determine proportional frequency of graft, sex and age in time of surgery and to determine arithmetic mean and standard deviation of age, age related to graft, acetabular angle, proportion of the cup covered by bone graft, graft height and width and investigators' assessment. Students' *t* test for dependent samples was used for significance testing between acetabular angles, proportion of the cup covered by bulk bone graft, graft height and width considering all testing intervals. Level of significance was set at  $p < 0.05$ . Multiple analysis of variance was used for significance testing of differences between investigators. Reliability of results of different investigators was determined by Pearson's linear correlation coefficient, internal consistency measurement (Cronbach's  $\alpha$ ), and assessment of inter-rater correlation. Four patients were not eligible for long-term follow-up. All available data concerning overall graft survival assessment 10 years after operation were analyzed using the Kaplan–Meier estimator.

### Results

Patients were on average 46.2 years old (20–76 years, SD 13.2), 33 % being younger than 40 years. Forty-one patients had one side hip reconstruction with autograft and four had bilateral operations with autograft. Allografts were used in 19 patients, in 15 patients unilaterally and in four patients bilaterally. Patients in autograft group were on average 47.1 years old and in allograft group 44.1 years. Severity of hip dysplasia was determined using Crowe classification [12]. Sixteen patients in autograft group were Crowe II type (33 %) and 33 were Crowe III (67 %). In allograft group, six patients were classified as Crowe II (26 %) and 17 were Crowe III (74 %). Acetabular angle (on average  $45.5^\circ \pm 10.3^\circ$  immediately after operation) showed significant increase over time after each measurement (Table 2) in all patients.

The same tendency was noted analyzing acetabular angle values in both autograft and allograft group. Proportion of the cup covered by bulk bone graft showed significant decrease from  $53.6^\circ \pm 15.6^\circ$  immediately after operation (Table 2) in all patients. Significant decrease was found in both groups. Accordingly, the largest width of the bone grafts decreased from average  $3.5 \pm 1.4$  cm significantly in both groups when measured together and separately (Table 2).

Values of bone graft height were in concordance with prior measurements. There was significant decrease in graft height in all patients, in autograft and allograft group compared to baseline (Table 2; Fig. 2).

Analyzing questionnaire results significant inter-rater difference (Wilks' Lambda 0.835, Rao  $R(12,420) = 2.47$ ;  $p = 0.0039$ , Pillai–Bartlett Trace 0.168,  $V(12,483) = 2.382$ ;  $p = 0.0054$ ) was found. However, all four investigators rated graft integrity with lower grades at every tested time point than immediately after operation. When tested with Pearson's linear correlation, there was significant positive correlation between raters' grades with level of significance at  $p < 0.05$ . Inter-rater reliability was significant, but weak ( $=0.49$ ), as well as internal consistency reliability (Cronbach  $\alpha = 0.75$ ). This is not surprising since evaluation questionnaire was used for the first time without previous training. Despite the differences, deterioration of graft integrity was noted by all four raters through entire time line (Fig. 3).

Analysis of overall acetabular cup stability and graft integrity showed that 25 % were unstable after 3 years, 50 % after 8 years, and only 25 % had adequate bone graft integrity after 10 years. In autograft group, acetabular cup instability was 25 % after 4 years, 50 % after 8 years, and 75 % after 9.3 years. Allografts were failing causing acetabular cup instability in 25 % after only 2 years, 50 % after 5 years, and 85 % after 10 years (Fig. 4).

### Discussion

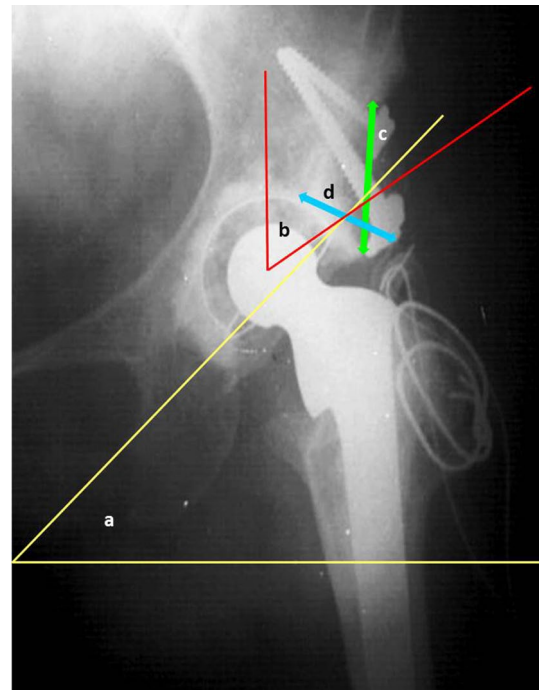
Key factors for acetabular cup stability in dysplastic hips are restoration of optimal anatomical and biomechanical relations [12, 27, 28]; placing the acetabular component in proper center of rotation with acetabular angle between  $40^\circ$  and  $45^\circ$  and  $20^\circ$ – $30^\circ$  of anteversion, and optimal coverage of the cup. Therefore, several operative techniques were developed and published [1–3, 5–10, 29]. For techniques which use bone grafts to compensate inadequate acetabular cup coverage, first and early encouraging results [11, 12] were later disputed by the original authors [13] and signs of loosening were reported after 7 years on average. Further, postmortem histological findings in "radiologically" healed grafts have showed sparse union [8]. When reviewing results of cemented endoprostheses with structural bone grafts, Gerber and Harris [7]

**Table 2** Statistically significant changes in chosen parameters of graft survival over time in all patients (Group 1 + 2) and in autograft (Group 1) and allograft (Group 2) group separately

Time (after surgery)	Group	Acetabular angle (°)			Cup coverage (°)			Graft width (cm)			Graft height (cm)		
		Average ± SD	Difference	<i>t</i>	Average ± SD	Difference	<i>t</i>	Average ± SD	Difference	<i>t</i>	Average ± SD	Difference	<i>t</i>
6 months	Group 1 + 2	43.8 ± 10.6	3.7	7.14	49.5 ± 14.3	6.4	9.07	2.9 ± 1.2	0.9	9.71	2.5 ± 1	0.8	8.17
	Group 1	46.5 ± 10.2	3.4	7.51	53.5 ± 13.7	6.7	7.76	2.8 ± 1.1	0.8	9.82	2.6 ± 1.1	0.7	6.66
1 year	Group 2	52.1 ± 7*	2.9	3.16	40.8 ± 11.8	5.9	4.59	3.2 ± 1.6	1.3	5.09	2.3 ± 1	1	4.87
	Group 1 + 2	47.5 ± 11.5	5	6.56	42.5 ± 12.2	10	10.04	2.4 ± 1.3	1.1	10.34	1.8 ± 1	1	8.93
2 years	Group 1	49.8 ± 10.7	5.1	8.23	45.4 ± 12.4	10.9	7.51	2.2 ± 1.2	1	8.38	1.9 ± 1	0.9	7.27
	Group 2	53.8 ± 8.1	5.4	4.88	37.8 ± 10.5	8.5	7.99	3 ± 2.3	1.3	6.39	1.5 ± 1.1	1.4	5.69
3 years	Group 1 + 2	50.1 ± 10.7	6.5	7.25	40 ± 11.8	13.2	12.54	2 ± 1.4	1.9	11.32	1.3 ± 1	1.2	6.83
	Group 1	53.5 ± 10.8	8.3	9.99	42.6 ± 12.5	13.5	9.2	1.8 ± 1.2	1.5	9.51	1.4 ± 1.2	0.9	5.71
3 years	Group 2	58.8 ± 8.8	11.2	7.95	36 ± 9.6	12.6	8.76	2.5 ± 1.6	2.6	5.56	1.1 ± 0.7	1.6	4.84
	Group 1 + 2	51.3 ± 11.2	9.3	9.6	35.3 ± 10.8	18.4	14.18	1.8 ± 1.1	1.9	12.49	0.9 ± 0.9	1.8	11.64
3 years	Group 1	55.1 ± 11.3	11	13.6	38.1 ± 11	18.9	10.29	1.8 ± 1.2	1.3	10.39	0.9 ± 0.9	1.6	9.9
	Group 2	61.9 ± 7.8	13.9	11.43	30.3 ± 8.5	17.4	11.31	1.9 ± 1.7	2.8	7.31	0.9 ± 0.7	2.1	6.58

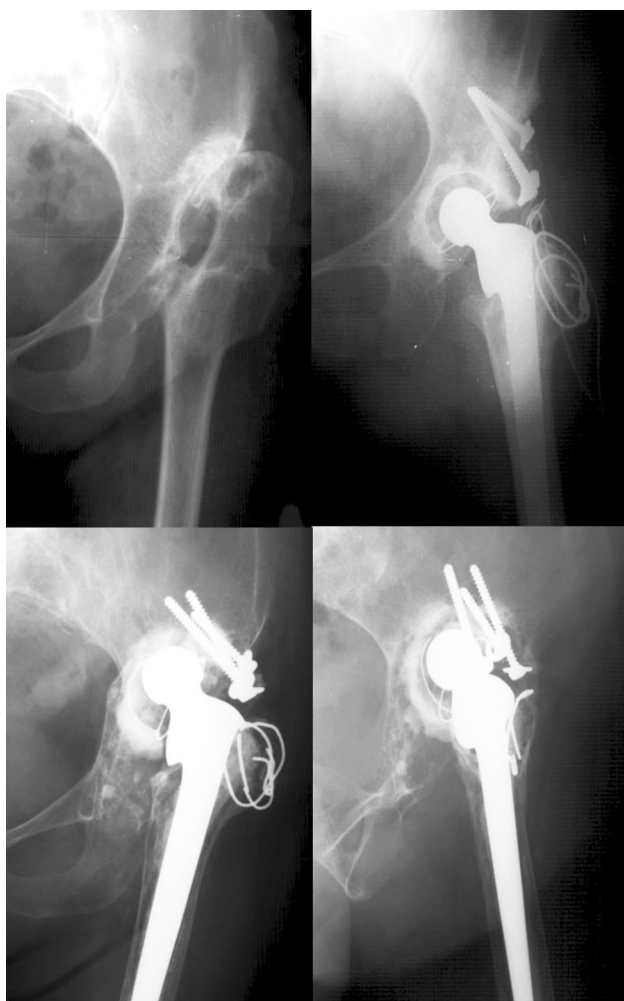
There is significant increase in acetabular angle, decrease of cup coverage, graft width, and height in both groups at every period of evaluation

\*  $p = 0.0064$ , in all cases  $p < 0.0001$

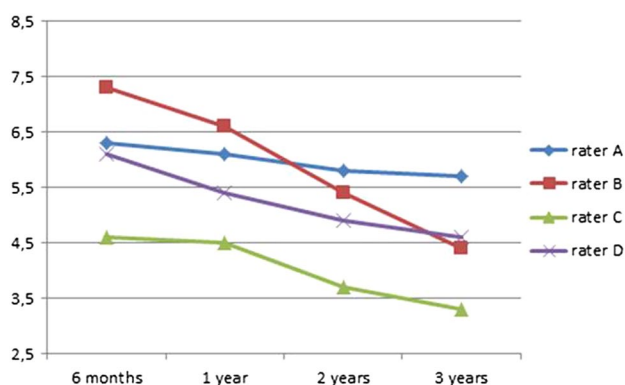


**Fig. 1** Measured parameters for assessing graft integrity and acetabular cup stability; acetabular angle *a*, cup coverage *b*, largest cranio-caudal diameter *c* and largest mediolateral graft diameter *d*

reported 21 % of failed bone grafts and Mulroy showed high (46 %) percentage of failure of acetabular fixation [13], similar as Kwong [30] and Lee [25]. Shinar [6] also emphasized that greater coverage of the acetabular component by the graft (more than 40 %) will result in greater rate of late failure. On the other hand, de Jong [18] reported good long-term results with smaller autografts but the limitation of this study was that most patients had minor dysplasia (Crowe [12] type 1) similar as Masui [21] who reported only three cases of radiological loosening after on average 12 years of follow-up with most of the patients classified as Crowe I or II and mean proportion of graft acetabular coverage 23.1 percent smaller grafts were also used by Bobak [31], Inao [19] and Rodriguez [20] with good long-term outcome. Busch [23] claims all-cause survivorship of 98 % at 10 years follow-up and Akiyama [24] 96 % at 15 years advocating usage of bone grafts with emphasis on improved surgical techniques. When cementless hip reconstruction with structural bone grafts is concerned, Hasegawa [32] and Yamaguchi [33] published good short-term results and Spangehl [34] described good mid-term results showing 91 % of 10-year rate of survival without acetabular revision because of aseptic loosening. Schofer [16] published promising short- to mid-term results with failure rate of 6.7 %. Morsi [35] states good long-term results being 94 % success rate after on average 6.6 years similar as Shetty [36]. Results of 10-year survival rate without acetabular revision for any reason are shown by Kim [17] being 94 % and Tsukada [15] with

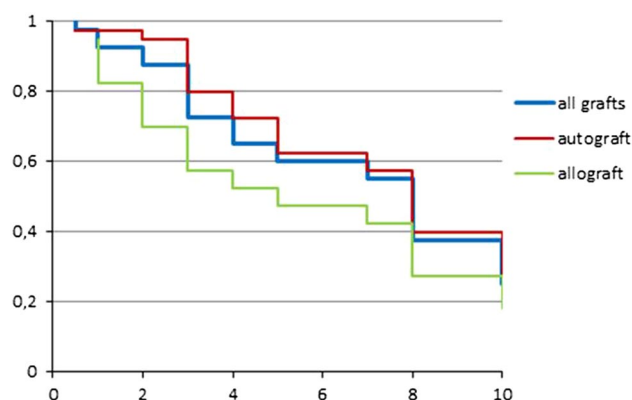


**Fig. 2** Radiograph showing failure of bone allograft



**Fig. 3** Average grades of graft integrity for four raters during 3 years after THA

100 % survival rate with mean follow-up time of 8.3 years. Even longer follow-up (18.5 years) in Saito [22] paper is connected with 94.5 % survival rate. However, Hendrich [5]



**Fig. 4** Kaplan–Meier estimator of bone graft survival in percentage during 10 years

reported 36 % loosening after THA with grafting and Zahar [37] stated that using Kaplan–Meier survivorship analysis for all-cause revision, THA with a bulk allograft for acetabular reconstruction had a predicted 80 % survival at 14 years; but that survival appears to dramatically decrease after 15 years postoperatively. The results of our study contradict both short- and long-term good results and emphasize early failure of used grafts. We are aware that structural changes of the graft are possible up to 4 years after THA [31]; however, the constant deterioration recorded on every evaluation time point does not support the idea that adequate remodeling will occur later. These results are confirmed with overall acetabular cup stability analysis done 10 years after THA when high instability rate was shown. Possible reason for high failure rate could be in higher percent of younger individuals (33 % younger than 40 years), but also higher proportion of more severe types of dysplasia (~70 % of Crowe III in both groups). We agree that each type of dysplasia requires individual preoperative planning and adjustment of THA technique. And since THA due to hip dysplasia is performed in younger patients, careful treatment decision is to be made to avoid early need for revision arthroplasty. Taking into consideration the collected data while acknowledging the drawbacks of this study and the need for further research, we do not support the use of free bulk bone grafts raising concern of the long-term endoprosthesis stability.

**Conflict of interest** None.

## References

- Hartofilakidis G, Stamos K, Karachalios T, Ioannidis TT, Zacharakis N (1996) Congenital hip disease in adults. Classification of acetabular deficiencies and operative treatment with acetabuloplasty combined with total hip arthroplasty. *J Bone Joint Surg* 78(5):683–692

2. Kaneuji A, Sugimori T, Ichiseki T, Yamada K, Fukui K, Matsumoto T (2009) Minimum ten-year results of a porous acetabular component for Crowe I to III hip dysplasia using an elevated hip center. *J Arthroplasty* 24(2):187–194. doi:10.1016/j.arth.2007.08.004
3. Dorr LD, Tawakkol S, Moorthy M, Long W, Wan Z (1999) Medial protrusion technique for placement of a porous-coated, hemispherical acetabular component without cement in a total hip arthroplasty in patients who have acetabular dysplasia. *J Bone Joint Surg* 81(1):83–92
4. Pagnano W, Hanssen AD, Lewallen DG, Shaughnessy WJ (1996) The effect of superior placement of the acetabular component on the rate of loosening after total hip arthroplasty. *J Bone Joint Surg* 78(7):1004–1014
5. Hendrich C, Mehling I, Sauer U, Kirschner S, Martell JM (2006) Cementless acetabular reconstruction and structural bone-grafting in dysplastic hips. *J Bone Joint Surg* 88(2):387–394. doi:10.2106/JBJS.D.02373
6. Shinar AA, Harris WH (1997) Bulk structural autogenous grafts and allografts for reconstruction of the acetabulum in total hip arthroplasty. Sixteen-year-average follow-up. *J Bone Joint Surg* 79(2):159–168
7. Gerber SD, Harris WH (1986) Femoral head autografting to augment acetabular deficiency in patients requiring total hip replacement. A minimum five-year and an average seven-year follow-up study. *J Bone Joint Surg* 68(8):1241–1248
8. Hooten JP Jr, Engh CA, Heekin RD, Vinh TN (1996) Structural bulk allografts in acetabular reconstruction. Analysis of two grafts retrieved at post-mortem. *J Bone Joint Surg* 78(2):270–275
9. Delimar D, Cicak N, Klobucar H, Pecina M, Korzinek K (2002) Acetabular roof reconstruction with pedicled iliac graft. *Int Orthop* 26(6):344–348
10. Delimar D, Bicanic G, Pecina M, Korzinek K (2004) Acetabular roof reconstruction with pedicled iliac graft: early clinical experience. *Int Orthop* 28(5):319–320
11. Harris WH, Crothers O, Oh I (1977) Total hip replacement and femoral-head bone-grafting for severe acetabular deficiency in adults. *J Bone Joint Surg* 59(6):752–759
12. Crowe JF, Mani VJ, Ranawat CS (1979) Total hip replacement in congenital dislocation and dysplasia of the hip. *J Bone Joint Surg* 61(1):15–23
13. Mulroy RD Jr, Harris WH (1990) Failure of acetabular autogenous grafts in total hip arthroplasty. Increasing incidence: a follow-up note. *J Bone Joint Surg* 72(10):1536–1540
14. Marti RK, Schuller HM, van Steijn MJ (1994) Superolateral bone grafting for acetabular deficiency in primary total hip replacement and revision. *J Bone Joint Surg* 76(5):728–734
15. Tsukada S, Wakui M (2012) Bulk femoral head autograft without decortication in uncemented total hip arthroplasty: seven- to ten-year results. *J Arthroplasty* 27(3):437.e1–444.e1. doi:10.1016/j.arth.2011.06.003
16. Schofer MD, Pressel T, Schmitt J, Heyse TJ, Boudriot U (2011) Reconstruction of the acetabulum in THA using femoral head autografts in developmental dysplasia of the hip. *J Orthop Surg Res* 6:32. doi:10.1186/1749-799X-6-32
17. Kim M, Kadowaki T (2010) High long-term survival of bulk femoral head autograft for acetabular reconstruction in cementless THA for developmental hip dysplasia. *Clin Orthop Relat Res* 468(6):1611–1620. doi:10.1007/s11999-010-1288-6
18. de Jong PT, Haverkamp D, van der Vis HM, Marti RK (2006) Total hip replacement with a superolateral bone graft for osteoarthritis secondary to dysplasia: a long-term follow-up. *J Bone Joint Surg* 88(2):173–178. doi:10.1302/0301-620X.88B2.16769
19. Inao S, Matsuno T (2000) Cemented total hip arthroplasty with autogenous acetabular bone grafting for hips with developmental dysplasia in adults: the results at a minimum of ten years. *J Bone Joint Surg* 82(3):375–377
20. Rodriguez JA, Huk OL, Pellicci PM, Wilson PD Jr (1995) Autogenous bone grafts from the femoral head for the treatment of acetabular deficiency in primary total hip arthroplasty with cement. Long-term results. *J Bone Joint Surg* 77(8):1227–1233
21. Masui T, Iwase T, Kouyama A, Shidou T (2009) Autogenous bulk structural bone grafting for reconstruction of the acetabulum in primary total hip arthroplasty: average 12-year follow-up. *Nagoya J Med Sci* 71(3–4):145–150
22. Saito S, Ishii T, Mori S, Hosaka K, Nemoto N, Tokuhashi Y (2011) Long-term results of bulk femoral head autograft in cementless THA for developmental hip dysplasia. *Orthopedics* 34(2):88. doi:10.3928/01477447-20101221-15
23. Busch VJ, Clement ND, Mayer PF, Breusch SJ, Howie CR (2012) High survivorship of cemented sockets with roof graft for severe acetabular dysplasia. *Clin Orthop Relat Res* 470(11):3032–3040. doi:10.1007/s11999-012-2346-z
24. Akiyama H, Kawanabe K, Iida H, Haile P, Goto K, Nakamura T (2010) Long-term results of cemented total hip arthroplasty in developmental dysplasia with acetabular bulk bone grafts after improving operative techniques. *J Arthroplasty* 25(5):716–720. doi:10.1016/j.arth.2009.05.017
25. Lee BP, Cabanela ME, Wallrichs SL, Ilstrup DM (1997) Bone-graft augmentation for acetabular deficiencies in total hip arthroplasty. Results of long-term follow-up evaluation. *J Arthroplasty* 12(5):503–510
26. Brooker AF, Bowerman JW, Robinson RA, Riley LH Jr (1973) Ectopic ossification following total hip replacement. Incidence and a method of classification. *J Bone Joint Surg* 55(8):1629–1632
27. Bicanic G, Delimar D, Delimar M, Pecina M (2009) Influence of the acetabular cup position on hip load during arthroplasty in hip dysplasia. *Int Orthop* 33(2):397–402. doi:10.1007/s00264-008-0683-z
28. Traina F, De Fine M, Biondi F, Tassinari E, Galvani A, Toni A (2009) The influence of the centre of rotation on implant survival using a modular stem hip prosthesis. *Int Orthop* 33(6):1513–1518. doi:10.1007/s00264-008-0710-0
29. Delimar D, Bicanic G, Korzinek K (2008) Femoral shortening during hip arthroplasty through a modified lateral approach. *Clin Orthop Relat Res* 466(8):1954–1958. doi:10.1007/s11999-008-0292-6
30. Kwong LM, Jasty M, Harris WH (1993) High failure rate of bulk femoral head allografts in total hip acetabular reconstructions at 10 years. *J Arthroplasty* 8(4):341–346
31. Bobak P, Wroblewski BM, Siney PD, Fleming PA, Hall R (2000) Charnley low-friction arthroplasty with an autograft of the femoral head for developmental dysplasia of the hip. The 10- to 15-year results. *J Bone Joint Surg* 82(4):508–511
32. Hasegawa Y, Iwata H, Iwase T, Kawamoto K, Iwasada S (1996) Cementless total hip arthroplasty with autologous bone grafting for hip dysplasia. *Clin Orthop Relat Res* 324:179–186
33. Yamaguchi T, Naito M, Asayama I, Shiramizu K (2004) Cementless total hip arthroplasty using an autograft of the femoral head for marked acetabular dysplasia: case series. *J Orthop Surg (Hong Kong)* 12(1):14–18
34. Spanghel MJ, Berry DJ, Trousdale RT, Cabanela ME (2001) Uncemented acetabular components with bulk femoral head autograft for acetabular reconstruction in developmental dysplasia of the hip: results at five to twelve years. *J Bone Joint Surg* 83-A(10):1484–1489
35. Morsi E, Garbuz D, Gross AE (1996) Total hip arthroplasty with shelf grafts using uncemented cups. A long-term follow-up study. *J Arthroplasty* 11(1):81–85

36. Shetty AA, Sharma P, Singh S, Tindall A, Kumar SV, Rand C (2004) Bulk femoral-head autografting in uncemented total hip arthroplasty for acetabular dysplasia: results at 8 to 11 years follow-up. *J Arthroplasty* 19(6):706–713
37. Zahar A, Papik K, Lakatos J, Cross MB (2014) Total hip arthroplasty with acetabular reconstruction using a bulk autograft for patients with developmental dysplasia of the hip results in high loosening rates at mid-term follow-up. *Int Orthop* 38(5):947–951 doi:[10.1007/s00264-014-2280-7](https://doi.org/10.1007/s00264-014-2280-7)