

High-Pressure Injection Injuries of the Hand – Report of Two Cases

I. Utrobičić¹, Z. Pogorelić², N. Družjanić³

Department of Plastic, Reconstructive and Aesthetic Surgery¹, Department of Pediatric Surgery², Department of Surgery³, University Hospital Split, Spinčićeva 1, 21000 Split, Croatia.

Abstract. High-pressure injection injuries to the hand are work-related injuries that can take a devastating toll on the functionality of the affected extremity. We present two cases of high-pressure injection hand injuries due to paint and sand. The patients were managed operatively and switch to intensive physiotherapeutic training, with excellent outcome.

Introduction

High-pressure injection injuries are an unusual cause of morbidity in the emergency department. They most commonly occur due to work-related industrial accidents in which a high-pressure or hydraulic spray gun is being used. Due to relatively small initial insertion sites, and minor swelling of the adjacent peripheral tissue, they can be overlooked and under treated. On average 1/600 trauma of the hand include an injection injury under high-pressure. They occur predominantly in young men (1, 2). The average age of patients with an injection injury is around 36 years (1, 3). The majority of the injuries affect the non-dominant hand (1-4). The most commonly injected substances are paints, paint solvents, grease, fuel oil, but there has also been reported injection of water, air, cement, and animal vaccines (2, 4, 5). Acute injury is caused by introduction of a foreign material, under high pressure between 2,000 and 10,000 psi, into the poorly distensible digital or palmar tissues. The pathophysiology involves acute and chronic inflammation and foreign body granuloma formation. Damage results from the impact, ischemia due to vascular compression, chemical inflammation, and secondary infection. Highly viscous substances require higher injection pressures than paint or solvents (1). Fuel and paint injections lead to the most severe inflammatory response with a high incidence of subsequent amputation. Grease and oil-based compounds may lead to oleogranulomas with chronic fistula formation, scarring, and eventual loss of digit function (1, 3, 4). The amputation rate of these injuries is up to 30-48% without adequate treatment (3). Morbidity is dependent to a large degree upon the material injected. Paint solvents appear to cause the greatest damage and result in amputation in 60-80% of the cases. Grease, the more common injectant, causes a less severe inflammatory response. Amputation is necessary in about 25% of these patients (3).

Case reports

Case 1

A 41-year-old right-handed man presented to the surgical emergency department approximately one hour after a work-related injury to his right hand from a high-pressure paint gun. The patient complained of severe pain to the right hand and decreased range of motion in the right 3rd and 4th digits. There was no other associated trauma.

The patient had normal vital signs and on clinical examination was found to have a 1.0 × 0.5-cm entry port of the palm between third and fourth metacarpal bone (Fig. 1a). There was circumferential edema of the 3rd and 4th digits extending proximally to the thenar and hypothenar eminence of the palm.

The X-ray of the right hand showed a large amount of radio dense material between third and fourth metacarpal bones, without associated fractures (Fig. 1b). Surgery under tourniquet and general anesthesia was performed. A palmar incision was made from PIP joint along the skin fold of the thenar muscle. The paint was removed and a debridement of all the necrotic tissue was performed, followed by a complete synovectomy (Fig. 1c). An incision was made on the dorsal part of the third and fourth finger and the paint around the extensor tendons of digits III and IV was removed (Fig. 1d). The wound was closed secondary seven days after first exploration. A suction drain was placed before secondary wound closure. Patient received tetanus immunization, low molecular heparin, painkillers and intravenous antibiotic (3rd generation cephalosporins). Postoperative the hand was placed on a palmar splint in intrinsic plus position. There was a good wound healing. Immediately the patient had to start with passive physiotherapy of the hand and three weeks postoperatively he could switch to an intensive physiotherapeutic training for about

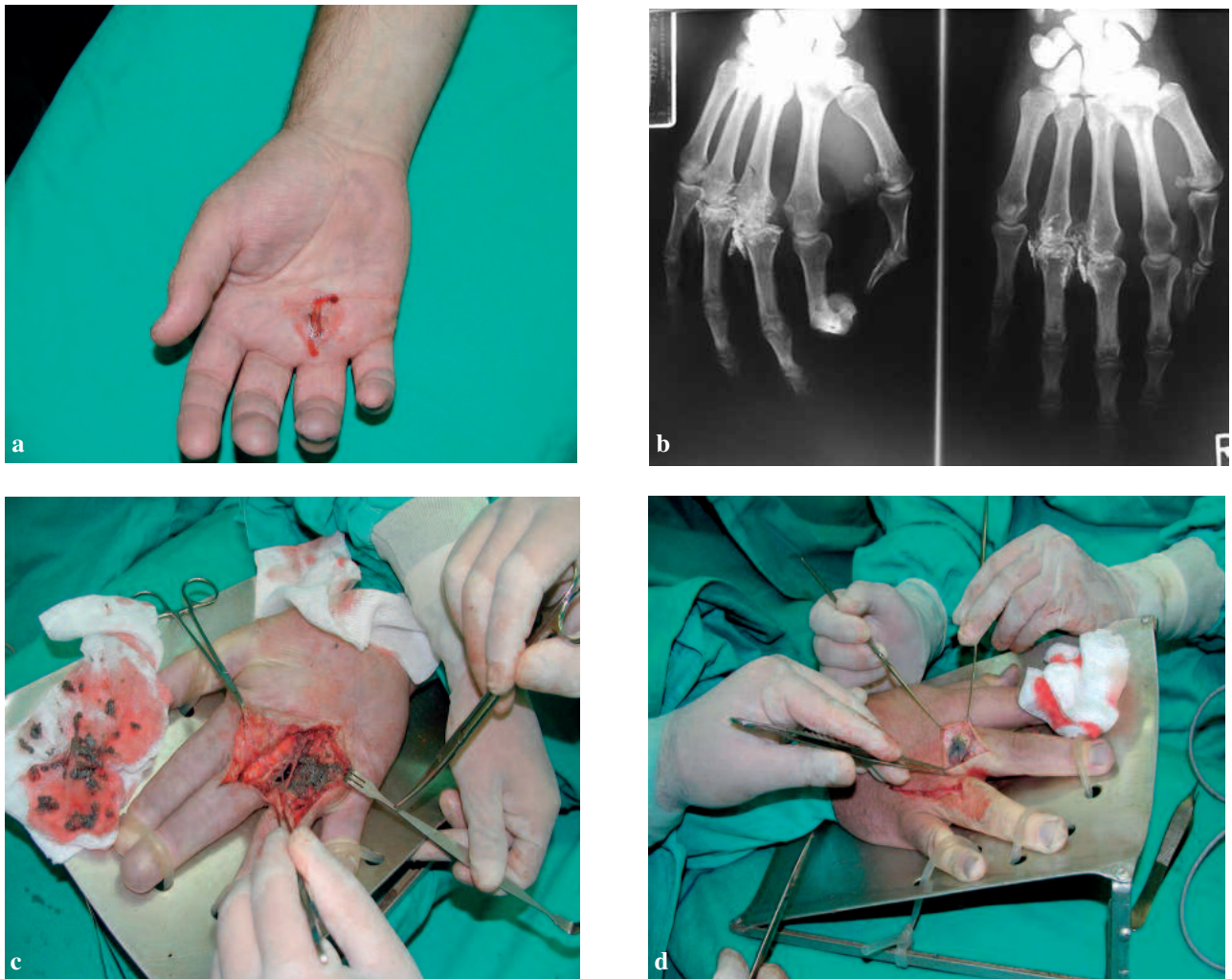


Fig. 1

- High pressure injection injury in a 41-year-old man.
 a) Clinical aspect at admission : small punctiform palmar skin lesion.
 b) X-ray of the right hand with radiodense material.
 c) Clinical aspect intraoperatively : exploration and debridement of the paint.
 d) Clinical aspect intraoperatively : exploration of the dorsal side.

6 months. A year after the injury the patient was re-evaluated. He had normal vascularisation, sensibility and complete active and passive range of motion of the fingers and hand.

Case 2

A 30-year-old right-handed man presented to the surgical emergency department approximately two hours after a work-related injury to his right hand from a high-pressure sandblasting machine, when air and particles of sand were injected. There was no other associated trauma. The patient had normal vital signs and on clinical examination was found to have a 7×3 -cm

black area of the skin on the volar side of the radiocarpal joint with a small entry port, size $1 \times 0,5$ -cm (Fig. 2a).

Right hand, forearm, and proximal third of upper arm were swollen, with strong crepitations, and hyposensibility of the thumb and forefinger.

The X-ray of the right hand showed a large amount of radio dense material at the volar side of the radiocarpal joint, without associated fractures (Fig. 2b). Surgery under tourniquet and general anesthesia was performed.

After incision a large amount of adherent reddish foreign material was exposed and removed and a debridement of all necrotic tissue was performed (Fig. 2c), followed by forearm fasciotomy (Fig. 2d). The

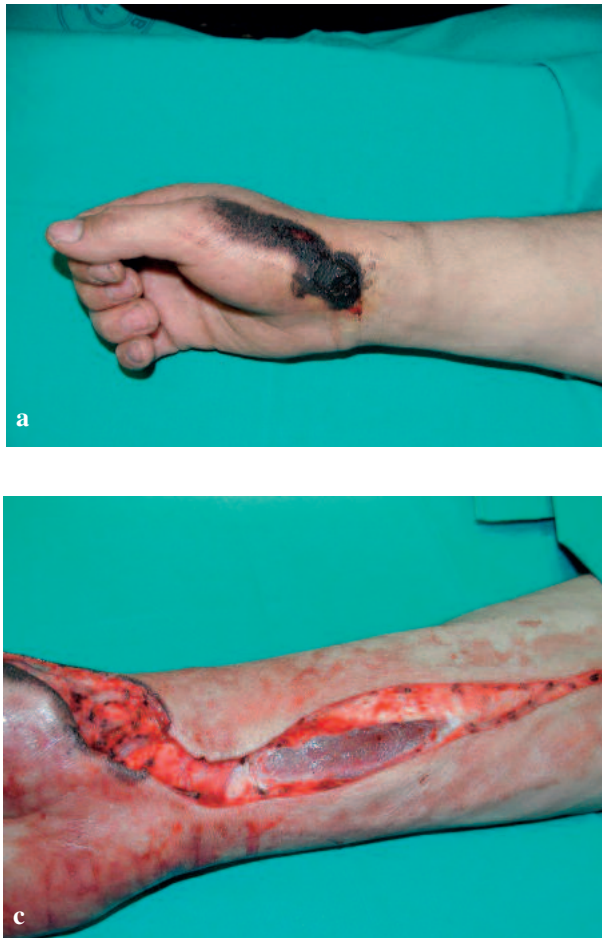
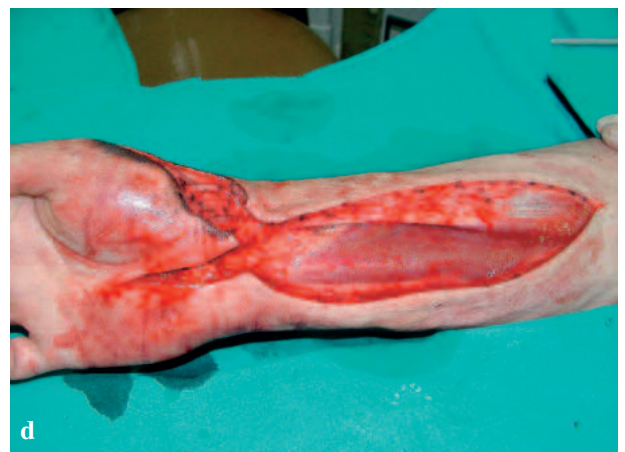
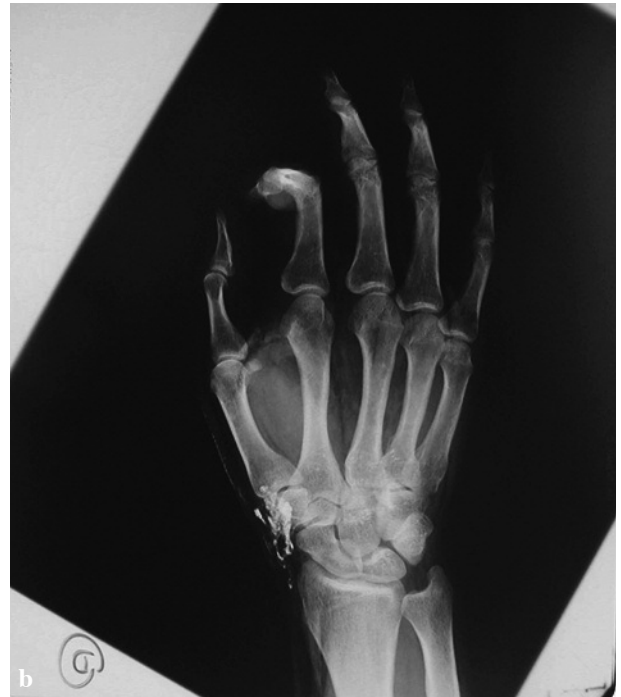
Fig. 2

- High pressure injection injury in a 30-year-old man.
 a) Clinical aspect at admission : 7 × 3-cm black area of the skin on the volar side of the radiocarpal joint with a small entry port.
 b) X-ray of the right hand with radiodense material.
 c) Clinical aspect intraoperatively : exploration and debridement of the sand.
 d) Clinical aspect intraoperatively : forearm fasciotomy.

particles of sand around the radial artery were removed. Secondary wound closure was performed six days after first exploration with suction drain in place. Patient received tetanus immunization, low molecular heparin, painkillers and intravenous antibiotics (amoxicillin/clavulanic acid and metronidasol).

Postoperative the hand was placed on a palmar splint in intrinsic plus position. There was a good wound healing. The patient had to start immediately with passive physiotherapy of the hand and three weeks post-operatively he could switch to an intensive physiotherapeutic training for about 6 months. A year after the injury the patient was re-evaluated. He had normal vascularisation, sensibility and complete active and passive range of motion of the fingers and hand.



Discussion

The first published cases of high-pressure hand injuries were injuries caused by fuel-injection systems (6). Nowadays, as technology advanced, more injection injuries with various caustic substances have been reported. In the work place, gasoline, sand, grease, and paint are common agents found under increased pressure. Less toxic pressurized agents include water, air and low-volume animal vaccines (4). The most common injuries concern the non-dominant hand (1, 4, 7), although in our cases both patients had an injury on the dominant hand. More than 50% of the injections occur in the index finger (1, 7). The second most touched region is the thumb and only 10% of the injections occur in the

hand palm or elsewhere (7), although in our cases both patients had injury on the palmar side. There are few most important factors in pathophysiology of high-pressure injuries. Factors of importance in pathophysiology of pressure accidents are: the high pressure, chemical damage, volume of injected substance, site of injection, infection and time between injury and operative treatment. The pressure plays an important role, it varies from 40 to 800 bar, at a pressure more than 7 bar direct contact with the skin is not necessary to infiltrate the subcutaneous tissues (1). The nature of the injected material is probably more important. It has been noted by many authors that injuries with paints have a worse outcome than those with oil or grease (8-10). The injected fluid spreads along the neurovascular bundles through places with the lowest resistance. This causes a traumatic dissection of the finger and compression of the neurovascular bundles with vascular spasms, tissue ischemia and thrombosis as a consequence. When substance is injected there is the chemical damage by the fluid itself. Some fluids have cytolytic properties and can cause tissue destruction, necrosis and intense inflammatory responses (1). Injuries with water, air, or low-volume vaccines may be amenable to non-operative treatment (4, 9). A next important factor which is determinative for the seriousness of the injury is the volume of injected substances. A larger quantity of the injected fluid causes a higher pressure in the tissues and therefore a larger risk on compression of the neurovascular bundles and tissue ischemia (1).

Very important factor is the site of injection, especially concerning large volumes. The hand palm has larger expansion capacity than a finger tip. The site of injection ascertains whether the fluid can penetrate in the tendon sheath itself or not (1). An amputation is often necessary with injections into a digit, while injections into the palm have better prognosis (10). An infection plays a role in the vast destruction of tissues. Finally, the time between injury and operative treatment has been regarded as a key determinant by a number of authors for the outcome of high-pressure injection injuries. On average patients are only seeking medical advice after 9 h (1). According to STARK *et al.* patients undergoing decompression earlier than 10 hours post-injury fared better (8). PINTO *et al.* have reported on the outcome of 25 patients injured with a variety of materials. They had the lowest amputation rates in the literature (16%), and postulated that presentation after more than 48 hours precluded application of their consistent practice of aggressive early debridement and open wound packing, which they thought was responsible for the favorable results (7). CHRISTODOULOU *et al.* reported the functional outcome of 15 patients with high-pressure injection injuries. According their findings this time factor is not always the most important variable. In their series all

patients were treated operatively, with a mean delay of 11.7 hours. They state that the eventual prognosis is influenced by different factors and that the prognosis of patients with an injection under very high pressure and with very toxic materials is bad as the prognosis of patients treated only after 10 h with a less detrimental injection. They conclude that deterioration of hand function is a predictable outcome of high-pressure injuries (9). GELBERMAN *et al.* have not been able to confirm the relationship of the delay to the outcome. A large number of their 26 patients treated by early surgery did not do as well as expected, whereas several with later surgery recovered satisfactorily (10). In our two cases patients were treated immediately operatively, within two or three hours after the injury. Both patients had excellent postoperative result with normal vascularisation, sensibility and complete active and passive range of motion of the fingers and hand. It is difficult to draw any conclusive evidence from these studies, because there seems to be a multitude of factors in play. From the information available to us, however, it seems likely that the time factor has so far been overestimated. If the pressure is high and the injected material toxic enough to cause vascular damage, it may not be possible to salvage the digit, however early the decompression is performed. Most of the authors agree that only a fast and wide exploration under general anesthesia or plexus block is the suitable treatment for a high-pressure injection injury (1, 3). Pushing the fluid to the outside or making relieving incisions for decompression is insufficient to prevent additional subcutaneous damage. All injected material and necrotic substances must be removed, followed by a saline irrigation.

Conclusion

High-pressure injection injuries to the hand are a true hand surgery emergency, they are characterized by punctiform skin lesion but with severe subcutaneous damage of the tissues. The initial clinical presentation can be misleading as a result of which an adequate treatment is frequently postponed. An intoxication caused by the fluid must be excluded. Prompt diagnosis and immediate aggressive surgical intervention are necessary to save the patients' digit/limb. The fast and wide surgical exploration must be carried out with complete debridement of the foreign material and necrotic tissue. A long-term and intensive physiotherapy afterwards will influence the outcome of the hand function in a positive way. Therefore it is very important to inform users of high-pressure guns about the seriousness of such injuries and to take preventive measures. Where necessary, these patients should be encouraged to consider retraining for alternative occupations to prevent them from becoming disabled.

References

1. VERHOVEN N., HIERNER R. High-pressure injection injury of the hand : an often underestimated trauma : case report with study of the literature. *Strategies Trauma Limb Reconstr*, 2008, **3** : 27-33.
2. DAILIANA H., KOTSAKI D., VARITIMIDIS S., MOKA S., BAKAROZI M., OIKONOMOU K., MALIZOS N. K. Injection injuries : seemingly minor injuries with major consequences. *Hippokratia*, 2008, **12** : 33-36.
3. HOGAN C. J., RULAND R. T. High-pressure injection injuries to the upper extremity : a review of the literature. *J Orthop Trauma*, 2006, **20** : 503-511.
4. SNARSKI J. T., BIRKHANN R. H. Non-operative management of a high-pressure water injection injury to the hand. *CJEM*, 2005, **7** : 124-126.
5. O'NEILL A. C., ISMAEL T. S., MCCANN J., REGAN P. J. Fish vaccine injection injuries of the hand. *Br J Plast Surg*, 2005, **58** : 547-549.
6. REES C. E. Penetration of tissue by fuel oil under high pressure from a diesel engine. *JAMA*, 1937, **109** : 866-867.
7. PINTO M., TURKULA-PINTO L., COONEY W., WOOD M. B., DOBYNS J. High-pressure injection injuries of the hand. Review of 25 patients managed by open wound technique. *J Hand Surg [Am]*, 1993, **18** : 125-130.
8. STARK H. H., ASHWORTH C. R., BOYES J. H. Paint gun injuries of the hand. *J Bone Joint Surg Am*, 1967, **49** : 637-647.
9. CHRISTODOULOU L., MELIKYAN E. Y., WOODBRIDGE S., BURKE F. D. Functional outcome of high-pressure injection injuries of the hand. *J Trauma*, 2001, **50** : 717-720.
10. GELBERMAN R. H., POSCH J. L., JURIST J. M. High-pressure injection injuries of the hand. *J Bone Joint Surg Am*, 1975, **57** : 935-937.

Z. Pogorelić, M.D., Ph.D.
 Department of Pediatric Surgery
 University Hospital Split
 Spinčićeva 1
 21 000 Split, Croatia
 Tel. : +38521556182
 Fax : +38521556225
 E-mail : zenon@vip.hr