

# Contraception-Related Deep Venous Thrombosis and Pulmonary Embolism in a 17-Year-Old Girl Heterozygous for Factor V Leiden, Prothrombin G20210A Mutation, MTHFR C677T and Homozygous for PAI-1 Mutation: Report of a Family with Multiple Genetic Risk Factors and Review of the Literature

Jasna Lenicek Krleza<sup>a</sup> Gordana Jakovljevic<sup>b</sup> Ana Bronic<sup>d</sup> Désirée Coen Herak<sup>e</sup>  
Aleksandra Bonevski<sup>b</sup> Jasminka Stepan-Giljevic<sup>b</sup> Goran Roic<sup>c</sup>

Departments of <sup>a</sup>Laboratory Diagnostics, <sup>b</sup>Oncology and Hematology and <sup>c</sup>Radiology, Children's Hospital Zagreb and University School of Medicine, <sup>d</sup>Department of Laboratory Diagnostics, University Hospital of Traumatology, and <sup>e</sup>Department of Laboratory Diagnostics, University Hospital Centre, Zagreb, Croatia

## Key Words

Deep venous thrombosis · Pulmonary embolism · Oral contraceptives · Teenagers · Prothrombotic risk factors

## Abstract

We present the case of a 17-year-old girl who suddenly woke up with localized pain in the left groin and the inability to twist her leg. After comprehensive physician and laboratory examinations, deep venous thrombosis with consequent pulmonary embolism was ascertained. She had not experienced any recent trauma, but she had started to take oral contraceptives 6 months prior to the onset of the symptoms. Her parents and sisters had been asymptomatic throughout their lives, but the family history revealed a few thromboembolic accidents. Using DNA analysis, heterozygosity for factor V Leiden, prothrombin gene mutation G20210A and methylenetetrahydrofolate reductase C677T, as well as the homozygous 4G/4G genotype in the plasminogen activator

inhibitor 1 were identified in our patient. Subsequently, DNA analysis was performed in all living family members, and multiple factors associated with thrombophilia were discovered. Our case confirms the multifactorial cause of thromboembolic events and emphasizes the importance of oral contraceptive use in the onset of venous thrombosis, especially in teenage females. In addition, this case indicates that teenage females with a family history of thrombosis who are making choices about contraception could most likely benefit from advanced thrombophilia testing.

Copyright © 2010 S. Karger AG, Basel

## Introduction

Venous thromboembolism (VTE) that encompasses deep venous thrombosis (DVT) and pulmonary embolism (PE), with an overall incidence of approximately 1–2 per 1,000 individuals per year, is a serious disorder with

potential major complications such as death, recurrences, and the development of a disabling postthrombotic syndrome [1, 2]. The predisposition to form clots inappropriately (thrombophilia) can arise from genetic factors, acquired changes in the clotting mechanism, or an interaction between both [3]. In the older population, VTE occurs mainly in the context of marked environmental influences such as surgery, obesity, and underlying malignancy. VTE in children and teenagers is usually associated with gene mutations in the presence of underlying conditions [4, 5]. It has been established that abnormalities of the anticoagulant mechanisms in plasma such as antithrombin (AT), protein C (PC), and protein S (PS) deficiencies are related to VTE accidents. Besides, the presence of activated PC (APC) resistance, a phenomenon mostly attributable to the presence of a factor V Leiden (FV Leiden) mutation [6–8], and the prothrombin gene mutation G20210A (FII 20210A) are also associated with an increased VTE risk [3, 6]. These mutations are more prevalent than the deficiency of the anticoagulant proteins AT, PC, and PS, accounting for a much higher population-attributable risk in Caucasians. Heterozygous carriers of FV Leiden have a 5- to 10-fold increased VTE risk, whereas homozygous carriers have a more than 50-fold increased risk. Furthermore, the presence of other inherited and/or environmental established risk factors increases the risk of VTE exponentially [3, 6, 7]. Antiphospholipid antibody syndrome and moderate hyperhomocysteinemia represent the most common acquired risk factors for VTE [3, 6, 7]. Antiphospholipid antibody syndrome is characterized by repeated positive tests for lupus anticoagulant (LA) and/or anti- $\beta_2$  glycoprotein and anticardiolipin antibodies (ACA). Moderate hyperhomocysteinemia, mostly due to a common C677T methylenetetrahydrofolate reductase (MTHFR) gene polymorphism, should be considered an independent risk factor for VTE since these patients have the same rate of VTE recurrence as those with other predisposing factors (APC, PC, and PS) [3, 6]. In addition, the considerable contribution of an increased VTE risk could be due to abnormalities of the fibrinolytic system. PAI-1 polymorphism is not considered an independent risk factor for VTE, and some literature data suggest an additional role of this polymorphism in VTE occurrence in subjects who are carriers of genetic or acquired thrombophilic factors. High plasma levels of PAI-1 have been associated with an increased risk of initial and recurrent DVT in Caucasians as well as with a 4G/5G insertion/deletion polymorphism in the promoter region of the PAI-1 gene [7–9]. Numerous other proposed causes of thrombophilia have been tested in a small

number of patients, and none of them have gained widespread acceptance as risk factors for thrombosis [6, 7, 10]. It is recommended that low-molecular-weight heparin (LMWH) be used in the initial treatment of VTE, followed by oral anticoagulant therapy (OAT) for at least 3 months, but the specific and appropriate therapy is highly dependent on the defining etiology [11, 12].

To date, there are no strong evidence-based guidelines regarding screening and who to test for evidence of thrombophilia, and decisions are likely individual. It has been presumed that a population-wide screening for thrombophilic risk factors in asymptomatic individuals is not indicated [13]. Regarding children, the decision to test asymptomatic individuals with a family history of VTE should be made after a discussion with the family, whereas symptomatic individuals should be tested for a full panel of thrombophilic risk factors because of the possible coexistence of multiple thrombotic risk factors [13–15].

## Patient and Methods

### *Patient and Family History*

Our patient was a 17-year-old girl with ascertained DVT and consequent PE. Her first-degree relatives (mother, father, and 2 sisters) and an uncle had been asymptomatic up to the time of reporting, but the family history revealed a few thromboembolic accidents. In the maternal lineage, thrombophlebitis was diagnosed in the propositus's grandmother, whereas the grandfather (deceased) had DVT during his life. In the paternal lineage, the propositus's grandfather had an episode of PE at the age of 85. The propositus's 47-year-old mother had 3 pregnancies in the period between 23 and 31 years of age with no complications and had never taken oral contraceptives (OC).

### *Blood Collection and Assays*

Peripheral blood samples were collected from the patient and all living family members. Blood for coagulation analysis was collected into tubes containing 0.109 M sodium citrate (Vacutainer; France). Samples for the determination of fasting homocysteine (Hcy) were collected into tubes containing K3-EDTA, placed immediately on ice, and centrifuged as soon as possible. Plasma samples were stored at  $-20^{\circ}\text{C}$  until assay. For the determination of C-reactive protein (CRP) and ACA, blood was collected into a plain glass Vacutainer tube. Samples for complete blood counts were collected from the peripheral capillary blood system in tubes containing K3-EDTA (Kabe Labortechnik GmbH, Germany), and the counts were performed on a Sysmex hematology analyzer (Sysmex K-4500, Germany).

Prothrombin time, activated partial thromboplastin time, thrombin time, fibrinogen, and the functional activities of AT and PC were determined on a Sysmex CA-500 analyzer using commercially available reagents (Siemens, USA). Free PS antigen was determined according to the method of Comp et al. [16] using PS polyclonal rabbit antibody (Dako, Denmark). Factor VIII activity

**Table 1.** Results of the laboratory analyses

Analysis	I	II	III	IV	V	Reference interval
CRP, mg/l	32	139	114	73	12	<5
ESR, mm/h	35	60	70	16	–	2–15
Fibrinogen, g/l	8.8	10.2	7.3	5.3	3.0	1.8–3.5
D-dimer, mg/l	4.55	4.35	3.92	2.15	0.87	<0.5
AT, %	117.3	89.0	71.3	83.2	108.4	70–120
PC, %	–	118.6	–	–	106.2	70–140
Free PS antigen, %	–	38.8	–	60.0	–	70–123
Factor VIII, U/dl	–	–	–	113.0	–	50–150
PLG, %	–	141.7	–	–	–	75–150
PAI-1, U/ml	–	3.9	–	–	–	0.3–3.5
APC ratio	–	1.42	–	1.47	–	>2.0
LA	–	negative	–	–	–	negative
ACA-IgG, GPL units/ml	–	8	–	–	–	<10
ACA-IgM, MPL units/ml	–	4	–	–	–	<10
Homocysteine, $\mu$ mol/l	–	9.5	–	–	–	5.0–15.0

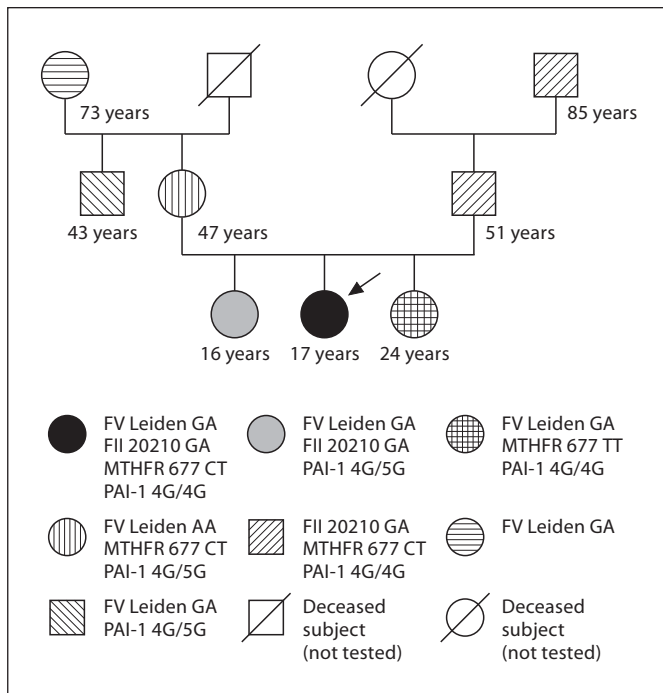
I = Analysis performed upon admission to the emergency pediatric clinic (first day of hospitalization); II = analysis performed immediately after the establishment of the diagnosis of DVT and before the therapy with LMWH was started (second day of hospitalization); III = analysis performed 1 week after hospital admission when the diagnosis of PE had been established; IV = analysis performed 5 weeks after hospital admission when OAT was initiated; V = analysis performed 6 weeks after hospital admission before discharge from the hospital. PLG = Plasminogen.

was determined using a 1-stage clotting assay, whereas plasminogen, PAI-1, and anti-Xa activities were determined using chromogenic substrate assays (Siemens) on BCS XP and BCT coagulation analyzers (Siemens). APC resistance was investigated using a venom-based assay, i.e. STA-STACLOT APC-R (Stago, France), modified as previously described [17]. The presence of LAs was determined according to the criteria of the Scientific and Standardization Committee of the International Society on Thrombosis and Haemostasis using 3 different tests (dilute Russell's viper venom time, LA-sensitive activated partial thrombin time, and dilute prothrombin time) [18]. ACA (IgG and IgM isotype antibodies) were detected by ELISA (Euroimmun, Germany) [19]. Total plasma Hcy levels that included all Hcy plasma types were measured using the fluorescence polarization immunoassay method with Hcy reagent (Abbott Laboratories, USA) on an AxSYM analyzer (Abbott Diagnostics, USA) [20]. On the same analyzer, we determined D-dimer concentrations using a microparticle enzyme immunoassay reagent kit (Axis-Shield Diagnostics, UK). CRP concentration was determined on an Olympus AU-400 analyzer using an immunoturbidimetric reagent kit (Olympus America, Inc.) [21].

Genomic DNA was extracted from peripheral blood samples by the salting-out method described by Miller et al. [22]. Genotyping for FV Leiden and FII 20210A was carried out using the PCR-RFLP method according to Zöller et al. [23] and Poort et al. [24], respectively. MTHFR and PAI-1 genotyping was performed by real-time PCR using melting curve analysis on a LightCycler (Roche Diagnostics, Switzerland) [25, 26].

## Results – Clinical Course and Laboratory Findings

A 17-year-old girl woke up with localized pain in the left groin and the inability to twist her leg. In the next hour, thorns and a swelling of the left leg with consequent paresis occurred. On admission, comprehensive physician and laboratory examinations were performed (column I in table 1). The complete blood count was within the reference interval, although relative thrombocytopenia was observed. The patient had not experienced any recent trauma, but 6 months prior to the onset of the symptoms had started taking OC pills containing 3 mg drospirenone and 30  $\mu$ g ethinylestradiol (Yasmin; Schering) because of the absence of a monthly menstruation. As clinical signs of DVT were present together with an increased D-dimer concentration, a Doppler ultrasound was performed and it showed flow changes in the left femoral and iliac veins. The diagnosis of DVT was confirmed by phleboscintigraphy of the left leg. The chest X-ray findings were within the normal range. After the diagnosis of DVT was established, an extended laboratory analysis before the introduction of therapy with enoxaparin twice daily every 12 h (1 mg/kg body weight) was performed (column II in table 1). Decreased free PS antigen and increased PAI-1 activity were



**Fig. 1.** Pedigree of the family investigated. The propositus is indicated by an arrow.

detected. The obtained APC ratio was below the cutoff value ( $<2.0$ ) indicating the probable presence of FV Leiden (APC ratios between 1.36 and 1.80 for heterozygotes and between 1.13 and 1.29 for homozygotes). CRP and fibrinogen levels were significantly higher than they had been the previous day, with a persistently high D-dimer concentration. The complete blood counts, Hcy level, AT and PC activities were within the reference intervals. The presence of LA and ACA was not identified. Because of persisting tachycardia during the first week of hospitalization, PE was suspected; therefore, a lung scintigraphy scan was performed. Pulmonary emboli were ascertained in both lungs. Genetic analysis revealed that our patient was a heterozygous carrier of FV Leiden, FII 20210A, and MTHFR C677T. In addition, the presence of the homozygous 4G/4G PAI-1 genotype was found. The obtained results and the positive family history of thrombosis prompted us to screen all of the patient's first-degree family members (mother, father, and 2 sisters), an uncle and her grandparents still alive for the same mutations. Figure 1 shows the pedigree of the investigated propositus's family. In all family members at least 1 mutation was identified. In the paternal lineage the propositus's father and grandfather were homozygous carriers of the PAI-1 4G allele, and double heterozygous car-

riers of FII 20210A and MTHFR C677T. In the maternal lineage the propositus's mother was a homozygous carrier of FV Leiden, and a double heterozygous carrier of MTHFR C677T and PAI-1 4G/5G. Both the propositus's sisters were heterozygous carriers of FV Leiden. Additionally, her 24-year-old sister was a homozygous carrier of MTHFR C677T and the PAI-1 4G allele, whereas her 16-year-old sister was a heterozygous carrier of FII 20210A and PAI-1 4G/5G. The propositus's grandmother was a heterozygous carrier of FV Leiden, as was the propositus's uncle who, additionally, was a heterozygous carrier of PAI-1 4G/5G.

While in hospital, the patient was carefully monitored during LMWH therapy with anti-Xa activities between 0.70 and 1.0 IU/ml. After 5 weeks, when radiological imaging and control Doppler ultrasound showed VTE regression (recanalization), OAT was introduced and carefully monitored to maintain the therapeutic range (international normalized ratio 2.0–3.0). Before starting OAT, free PS antigen and APC resistance were once again determined (column IV in table 1). After discharge from the hospital, the patient received detailed instructions about wearing compressive stockings, the seriousness of her condition, the possibility of VTE recurrence, and the importance of taking OAT.

## Discussion

In this study, we describe the sequence of the clinical and laboratory diagnosis of a 17-year-old girl who presented to the emergency pediatric clinic with suspected DVT 6 months after she had started taking OC.

The initial low level of free PS antigen was probably due to the use of OC and the acute thromboembolic event. The relative thrombocytopenia observed upon admission could be due to a recent sinus infection a few days before hospitalization (and the use of amoxicillin) and acute DVT. The diagnosis of PE was probably delayed because persisting tachycardia was the only clinical symptom.

After an enhanced laboratory examination, multiple inherited factors associated with thrombophilia were discovered in our patient: heterozygosity for FV Leiden, FII 20210A, and MTHFR C677T, together with the PAI-1 4G/4G genotype.

It has been established that the presence of either FV Leiden or FII 20210A is associated with an increased risk of VTE. Besides, a strong interaction between FV Leiden or FII 20210A and OC use has been identified, increasing the risk from 4-fold in genetically unaffected persons to 30-fold in FV Leiden carriers, and to 16-fold in FII 20210A



carriers [27–30]. Furthermore, in up to 40% of patients with FII 20210A FV Leiden is also present, as it is in our case [6].

High plasma levels of PAI-1 have been associated with an increased risk of first and recurrent DVT in Caucasians as well as with a 4G/5G insertion/deletion polymorphism in the promoter region of the PAI-1 gene. Data obtained in a recent meta-analysis suggest that PAI-1 4G/5G polymorphism is probably a mild risk factor for VTE. However, the 4G allele appears to increase the risk of VTE, particularly in subjects with other genetic thrombophilic defects [7, 8, 31–33].

As a combination of 4 inherited prothrombotic risk factors that indicate a high risk of recurrent thrombosis was identified in our patient, it is necessary to introduce prolonged OAT for at least 12 months or a life-long duration with secondary prophylaxis in all situations with a high risk (pregnancy and surgery) [34]. For women requiring long-term OAT who are attempting pregnancy, frequent pregnancy tests are suggested as well as substitution with LMWH when pregnancy is achieved [35].

In addition to pharmacology therapy, inferior vena cava (IVC) filters are used in adults in order to prevent PE in the presence of a contraindication to anticoagulant therapy or in patients with a high risk of proximal DVT. There is limited experience with IVC filters in children. They are usually placed temporarily in older children with VTE with ongoing bleeding or in children at high risk of bleeding due to a serious underlying illness, and the main complication is postthrombotic syndrome and chronic venous stasis. As there are no specific guidelines for the use of IVC filters in children, they were not considered for our patient [35–37].

Since thromboembolic events were reported in the patient's family history, DNA analysis was extended to her first-degree relatives (mother, father, and 2 sisters), an uncle, and her grandparents still alive. As shown in figure 1, different combinations of inherited prothrombotic risk factors have been identified in the propositus's family members. Although the propositus's first-degree relatives were asymptomatic, particular importance relates to the propositus's sisters who are of reproductive age (pregnancy and/or decision about contraception).

It is known that the coexistence of risk factors can lead to clinically apparent thrombotic disorders at an early age. So far there are no strong evidence-based guidelines regarding screening and who to test for evidence of thrombophilia. Therefore, decisions are likely to be individual. The management of such patients includes the discontinuation of OC and an appropriate intervention for acute thrombosis. However, a cost-benefit analysis performed

on the basis of the prevalence of the FV Leiden mutation and the risk of venous thrombosis in women taking OC suggests that a general screening of the most common hereditary risk factors for VTE is not cost-effective. Our case of a thrombophilic family shows the usefulness of such a determination in young girls who have the right to choose prophylaxis in situations in which it can be avoided as well as in inevitable situations of high risk [38, 39].

This case, together with previously published cases, illustrates the importance of taking a thorough personal and family history prior to the initiation of OC in all patients [40], and to screen for at least FV Leiden and FII 20210A in teenage females with a positive history of DVT before the use of OC.

## Conclusion

The obtained data confirm the multifactorial nature of thrombosis and emphasize the importance of transitory risk conditions such as OC use in the onset of thromboembolic incidents, especially with the coexistence of inherited risk factors.

Furthermore, we think that teenage females with a known or recorded family history of VTE and who are making choices about contraception could most likely benefit from advanced thrombophilia testing. If the results of screening are positive and the patient requests OC, alternate methods of contraception or therapy are recommended.

Besides, knowledge of a hereditary defect in a patient is obviously of great use to clinicians in determining the length of OAT as well as for preventing the recurrence of the thrombotic event. Furthermore, by detecting the defect in family members, we can identify those at high risk and provide them with appropriate preventive advice in high-risk conditions such as pregnancy avoidance (contraception), or facilitate a targeted prevention during unavoidable high-risk situations (pregnancy and surgery).

## References

- 1 Vossen CY, Conard J, Fontcuberta J, Makris M, Van der Meer FJ, Pabinger I, Palareti G, Preston FE, Scharrer I, Souto JC, Svensson P, Walker ID, Rosendaal FR: Risk of a first venous thrombotic event in carriers of a familial thrombophilic defect: the European Prospective Cohort on Thrombophilia (EPCOT). *J Thromb Haemost* 2005;3:459–464.
- 2 Tapson VF: Acute pulmonary embolism. *N Engl J Med* 2008;358:1037–1052.

- 3 Khan S, Dickerman JD: Hereditary thrombophilia. *Thromb J* 2006;4:15.
- 4 Prandoni P: Prevention and treatment of venous thromboembolism with low-molecular-weight heparins: clinical implications of the recent European guidelines. *Thromb J* 2008;6:13.
- 5 Anderson AF, Spencer FA: Risk factors for venous thromboembolism. *Circulation* 2003;107(suppl 1):19–26.
- 6 Bick RL: Hereditary and acquired thrombophilic disorders. *Clin Appl Thromb Haemost* 2006;12:125–135.
- 7 Endler G, Mannhalter C: Polymorphisms in coagulation factor genes and their impact on arterial and venous thrombosis. *Clin Chim Acta* 2003;330:31–55.
- 8 Sartori MT, Danesin C, Saggiorato G, Tormene D, Simioni P, Spiezia L, Patrassi GM, Girolami A: The PAI-1 gene 4G/5G polymorphism and deep vein thrombosis in patients with inherited thrombophilia. *Clin Appl Thromb Hemost* 2003;9:299–307.
- 9 Tsantes AE, Nikolopoulos GK, Bagos PG, Bonovas S, Kopterides P, Vaiopoulos G: The effect of the plasminogen activator inhibitor-1 4G/5G polymorphism on the thrombotic risk. *Thromb Res* 2008;122:736–742.
- 10 Tripodi A, Mannucci M: Laboratory investigation of thrombophilia. *Clin Chem* 2001;47:1597–1606.
- 11 Nicolaides AN, Fareed J, Kakkar AK, Bredin HK, Goldhaber SZ, Hull R, Kakkar VV, Michiels JJ, Myers K, Samama M, Sasahara A, Kalodiki E: Prevention and treatment of venous thromboembolism: International Consensus Statement (guidelines according to scientific evidence). *Int Angiol* 2006;25:101–161.
- 12 Hirsh J, Guyatt G, Albers GW, Harrington R, Schünemann HJ, American College of Chest Physicians: Antithrombotic and thrombolytic therapy: American College of Chest Physicians Evidence-Based Clinical Practice Guidelines (8th Edition). *Chest* 2008;134:473.
- 13 Baglin T: Management of thrombophilia: who to screen? *Pathophysiol Haemost Thromb* 2003/2004;33:401–404.
- 14 Manco-Johnson MJ, Grabowski EF, Hellgreen M, Kemahli AS, Massicotte MP, Muntean W, Peters M, Nowak-Göttl U: Laboratory testing for thrombophilia in pediatric patients. On behalf of the Subcommittee for Perinatal and Pediatric Thrombosis of the Scientific and Standardization Committee of the International Society of Thrombosis and Haemostasis (ISTH). *Thromb Haemost* 2002;88:155–156.
- 15 Raffini L: Thrombophilia in children: who to test, how, when, and why? *Hematology Am Soc Hematol Educ Program* 2008:228–235.
- 16 Comp PC, Doray D, Patton D, Esmon CT: An abnormal plasma distribution of protein S occurs in functional protein S deficiency. *Blood* 1986;67:504–508.
- 17 Coen Herak D, Milos M, Zadro R: Improvement of STA: STACLOT APC-R test for the detection of factor V Leiden by using APCR ratio. *J Thromb Haemost* 2005;3(suppl 1):P1292.
- 18 Brandt JT, Triplett DA, Alving B, Scharrer I: Criteria for the diagnosis of lupus anticoagulants: an update. *Thromb Haemost* 1995;74:1185–1190.
- 19 Harris EN, Gharavi AE, Patel SP, Hughes GR: Evaluation of the anti-cardiolipin antibody test: report of an international workshop held 4 April 1986. *Clin Exp Immunol* 1987;68:215–222.
- 20 Refsum H, Smith AD, Ueland PM, Nexø E, Clarke R, McPartlin J, Johnston C, Engbaek F, Schneede J, McPartlin C, Scott JM: Facts and recommendations about total homocysteine determinations: an expert opinion. *Clin Chem* 2004;50:3–32.
- 21 Baudner S, Dati F: Standardization of the measurement of 14 proteins in human serum based on the new IFCC/BCR/CAP international reference material CRM 470. *J Lab Med* 1996;20:145–152.
- 22 Miller SA, Dykes DD, Polesky HF: A simple salting out procedure for extracting DNA from human nucleated cells. *Nucleic Acids Res* 1988;16:1215.
- 23 Zoller B, Svensson PJ, He X, Dahlback B: Identification of the same factor V gene mutation in 47 out of 50 thrombosis-prone families with inherited resistance to activated protein C. *J Clin Invest* 1994;94:2521–2524.
- 24 Poort SR, Rosendaal FR, Reitsma PH, Bertina RM: A common genetic variation in the 3'-untranslated region of the prothrombin gene is associated with elevated plasma prothrombin levels and an increase in venous thrombosis. *Blood* 1996;88:3698–3703.
- 25 Aslanidis C, Nauck M, Schmitz G: High-speed prothrombin G→A 20210 and methylenetetrahydrofolate reductase C→T 677 mutation detection using real-time fluorescence PCR and melting curves. *Biotechniques* 1999;27:234–238.
- 26 Naucka M, Wieland H, März W: Rapid, homogeneous genotyping of the 4G/5G polymorphism in the promoter region of the PAI1 gene by fluorescence resonance energy transfer and probe melting curves. *Clin Chem* 1999;45:1141–1147.
- 27 Vandenbroucke JP, Koster T, Briët E, Reitsma PH, Bertina RM, Rosendaal FR: Increased risk of venous thrombosis in oral contraceptive users who are carriers of factor V Leiden mutation. *Lancet* 1994;344:1453–1457.
- 28 Helmerhorst FM, Bloemenkamp KW, Rosendaal FR, Vandenbroucke JP: Oral contraceptives and thrombotic disease: risk of venous thromboembolism. *Thromb Haemost* 1997;78:327–333.
- 29 Martinelli I, Taioli E, Bucciarelli P, Akhavan S, Mannucci PM: Interaction between the G20210A mutation of the prothrombin gene and oral contraceptive use in deep vein thrombosis. *Arterioscler Thromb Vasc Biol* 1999;19:700–703.
- 30 Rosendaal FR, Helmerhorst FM, Vandenbroucke JP: Oral contraceptives, hormone replacement therapy and thrombosis. *Thromb Haemost* 2001;86:112–123.
- 31 Segui R, Estelles A, Mira Y, Espana F, Villa P, Falco C, Vaya A, Granca S, Ferrando F, Aznar J: PAI-1 promoter 4G/5G genotype as an additional risk factor for venous thrombosis in subjects with genetic thrombophilic defects. *Br J Haematol* 2000;111:122–128.
- 32 Tsantes AE, Nikolopoulos GK, Bagos PG, Rapti E, Mantzios G, Kapsimali V, Travlou A: Association between the plasminogen activator inhibitor-1 4G/5G polymorphism and venous thrombosis: a meta-analysis. *Thromb Haemost* 2007;97:907–913.
- 33 Meltzer ME, Lisman T, Doggen CJ, de Groot PG, Rosendaal FR: Synergistic effects of hypofibrinolysis and genetic and acquired risk factors on the risk of a first venous thrombosis. *PLoS Med* 2008;5:e97.
- 34 Nowak-Göttl U, Kurnik K, Krümpel A, Stoll M: Thrombophilia in the young. *Hamostaseologie* 2008;28:16–20.
- 35 Bates SM, Greer IA, Pabinger I, Sofaer S, Hirsh J, American College of Chest Physicians: Venous thromboembolism, thrombophilia, antithrombotic therapy, and pregnancy: American College of Chest Physicians Evidence-Based Clinical Practice Guidelines (8th Edition). *Chest* 2008;133:844S–886S.
- 36 Chan AK, Deveber G, Monagle P, Brooker LA, Massicotte PM: Venous thrombosis in children. *J Thromb Haemost* 2003;1:1443–1455.
- 37 Monagle P, Chalmers E, Chan A, DeVeber G, Kirkham F, Massicotte P, Michelson AD, American College of Chest Physicians: Antithrombotic therapy in neonates and children: American College of Chest Physicians Evidence-Based Clinical Practice Guidelines (8th Edition). *Chest* 2008;133:887S–968S.
- 38 Lindhoff-Last E, Luxembourg B: Evidence-based indications for thrombophilia screening. *Vasa* 2008;37:19–30.
- 39 Wu O, Robertson L, Twaddle S, Lowe GD, Clark P, Greaves M, Walker ID, Langhorne P, Brenkel I, Regan L, Greer I: Screening for thrombophilia in high-risk situations: systematic review and cost-effectiveness analysis. The Thrombosis: Risk and Economic Assessment of Thrombophilia Screening (TREATS) study. *Health Technol Assess* 2006;10:1–110.
- 40 Savelli SL, Kerlin BA, Springer MA, Monda KL, Thornton JD, Blanchong CA: Recommendations for screening for thrombophilic tendencies in teenage females prior to contraceptive initiation. *J Pediatr Adolesc Gynecol* 2006;19:313–316.