

Prevalence of dental pathology in wolves (*Canis lupus* L.) in Croatia - a case report

Dubravka Pavlović^{1*}, Tomislav Gomerčić¹, Goran Gužvica², Josip Kusak¹,
and Đuro Huber¹

¹Department of Biology, Faculty of Veterinary Medicine University of Zagreb, Zagreb, Croatia

²Oikon Ltd, Institute for Applied Ecology, Zagreb, Croatia

PAVLOVIĆ, D., T. GOMERČIĆ, G. GUŽVICA, J. KUSAK, Đ. HUBER: Prevalence of dental pathology in wolves (*Canis lupus* L.) in Croatia. Vet. arhiv 77, 291-297, 2007.

ABSTRACT

Skulls (N = 34) of gray wolves (*Canis lupus*) from Croatia were examined for acquired pathological changes of teeth. Skulls originated from wolves which had died due to various reasons in Croatia between 1997 and 2006. Age of examined animals ranged from 7 months to 8.5 years. Three skulls (8.9%) had pathological changes of teeth or alveolar bone. All dentitions with pathological changes belonged to females older than 2 years. Periodontitis, with changes in the alveolar bone, was determined on the alveolus of lower fourth premolar (P4) in two individuals and on the alveolus of the mandibular first molar (M1) in one specimen. A complicated crown-root fracture was found in two individuals. All caries lesions were found on premolars and molars. Caries was found on the upper jaw in one animal and on the lower jaw of another animal, while a third animal had it on both jaws. Pathological changes in the dentition of wolves in Croatia have not been previously recorded in Croatia. Data on pathological changes of wolves' teeth contribute to the knowledge of biology and health of this species, especially on factors limiting longevity.

Key words: gray wolf, teeth, periodontitis, caries, pathology, Croatia

Introduction

The prevalence of caries in wild mammals is generally rare, but periodontal disease is common in many wild, domestic and feral mammals (MILES and GRIGSON, 1990). The permanent dentition of wolves comprises 42 teeth, the dental formula being I3/3, C1/1, P4/4, and M2/3. Pathological changes in the dentitions of wolves in Croatia have not been previously recorded. In a study of wolf skulls from Central Europe and the former Soviet

*Contact address:

Dubravka Pavlović, DVM, Department of Biology, Faculty of Veterinary Medicine, University of Zagreb, Heinzelova 55, 10000 Zagreb, Croatia, Phone: +385 1 2390 141; Fax: +385 1 2441 390; E-mail: dpavlovic@vef.hr

Union, VILA et al. (1993) found pathological changes in wolf dentitions, including cases of alveolar bone loss. The aim of the present study was to record the nature and prevalence of acquired dental pathology in wolves in Croatia.

The presence of dental and/or periodontal disorders was studied on 34 skulls of gray wolves (*Canis lupus*) from the osteological collection of the Department of Biology at the Faculty of Veterinary Medicine. All skulls originated from wolves that died due to various reasons in Croatia between 1997 and 2006 (HUBER et al., 2002). Pathological changes, such as caries, tooth fracture and periodontitis with changes in the alveolar bone were observed on three skulls. Caries on wolf dentitions and periodontal lesions in the alveolar bone were determined by macroscopic examination. Periodontal status was assessed by classification adapted for use on dry skulls (VERSTRAETE et al., 1996), while tooth fractures were classified according to the World Health Organization classification of human dental fractures, as modified for use in carnivores (VERSTRAETE, 2003). The object was to evaluate the role of dentition, the wolf's main depredation tool, as a potential limiting factor for survival and for the duration of lives in wolves in Croatia.

Case report

Examined dentitions belonged to individuals ranging in age from 7 months to 8.5 years; 17 examined dentitions were from females, 15 were from males, and for two the gender was unknown. Three (8.8%) of 34 examined wolf skulls showed pathological changes in the form of caries and periodontitis, with a case of alveolar bone loss. Also, two of these three dentitions showed a complicated crown-root fracture. All three affected dentitions belonged to females older than 2 years with a permanent and complete set of teeth. Age of examined wolves was determined by the number of layers in the cementum of premolars (GIPSON et al., 2000).

Wolf WCRO 42 (died in a traffic accident, 2.1 years, 29 kg), had dark-coloured marks of caries of the occlusal surface on mandibular and on first, second and third molars. Signs of periodontal disease were observed on the maxillary fourth premolar. Horizontal bone loss was found in the area of the alveolus of this tooth

Wolf WCRO 2 (shot, 8.5 years, 37 kg) showed initial stage of caries development on occlusal part of the fourth premolar and on the maxillary first and second molars. Periodontitis of the mandibular first molar and osteolysis in the bone tissue of molar alveoli was observed in the same animal (Fig. 1). The lingual side of the same tooth was partially missing and these changes indicate a complicated crown-root fracture (VERSTRAETE, 2003). The changes in molar alveolus associated with periodontal disease showed resorption of the alveolar margin and widening of the periodontal space, which was consistent with periodontitis stage four (VERSTRAETE et al., 1996).

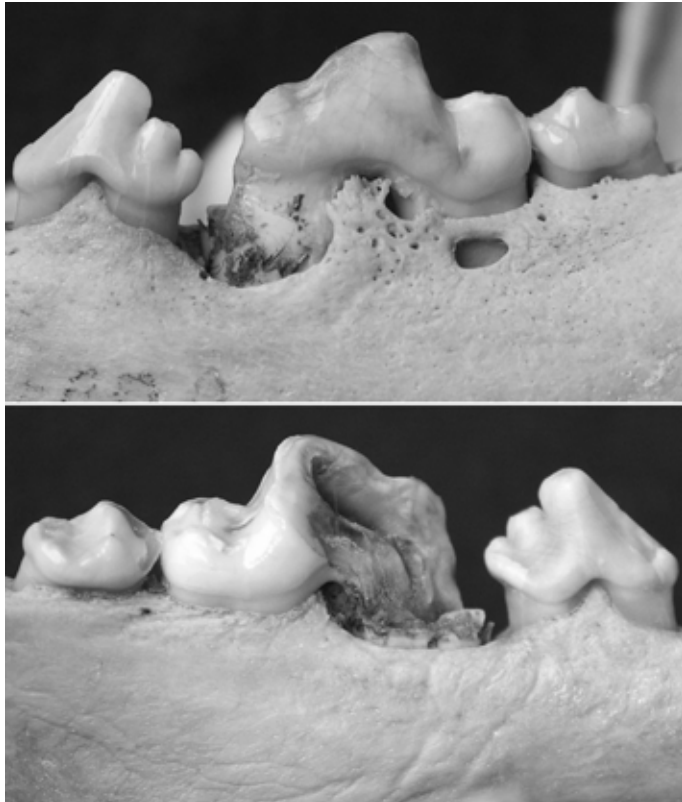


Fig. 1. Periodontitis of the mandibular first molar and osteolysis in the bone tissue of molar alveoli, with a complicated crown-root fracture of the same tooth, buccal view (top), lingual view (bottom) in wolf N° WCRO 2, 8.5-year-old female

Wolf WCRO 59 (shot, 5.1 years, 37 kg), had developed caries on the molar occlusal surfaces of both jaws (Fig. 2), and on the second incisor and first maxillary premolar. Additionally, the right maxillary fourth premolar showed periodontitis with signs of alveolar bone loss (periodontitis stage three). The bucal aspect of the same tooth was partially missing, which indicate a complicated crown-root fracture (Fig. 3). Deposit of calculus was visible on the same tooth.

Extremely abraded tooth crowns with exposure of dentin were observed on the three specimens on the opposite side to these with pathological changes. No pathological changes were found in the alveoli of remaining teeth.

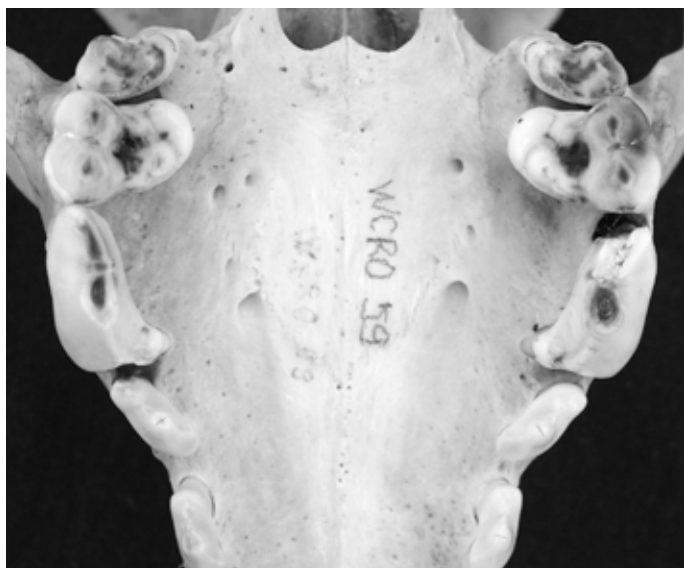


Fig. 2. Initial stage of caries on the occlusal surfaces of the maxillary molars in wolf N° WCRO 59, 5.4-year-old female

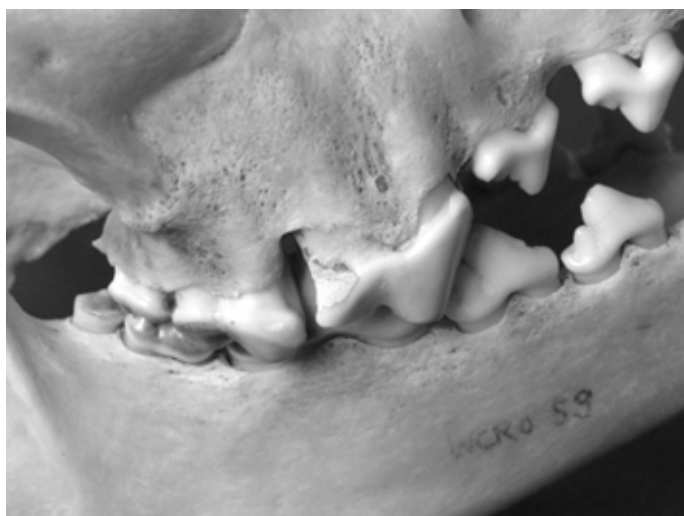

Fig. 3. Periodontitis with signs of alveolar bone loss in alveoli of fourth maxillary premolar with a complicated crown-root fracture and deposit of calculus on the same tooth, buccal view, in wolf N° WCRO 59, 5.4-year-old female

Discussion

According to VERSTRAETE (1999), grooves and uneven occlusal surfaces of tooth crowns are ideal sites for the initiation of a caries process. Caries is generally rare in wild mammals (MILES and GRIGSON, 1990). GOMERČIĆ (2005) found no caries in 58 examined lynx (*Lynx lynx*) skulls from Croatia. In this study, 8.8% of samples of wolf skulls from Croatia showed signs of caries. This may indicate that caries is more frequent in wild canids than in wild felids of Croatia. In all three wolves caries was determined on the first and second molar similar to the appearance of caries in dogs (HALE, 1998).

Periodontitis caused the gradual destruction of the bone of the alveoli in all three affected individuals. In a study of wolf skulls VILA et al. (1993) observed 38 (12.4%) individuals with alveolar resorption due to periodontal disease. Three (8.8%) of 34 examined wolf skulls from Croatia were affected with alveolar bone loss. Bone loss affected the alveoli of premolars in two specimens and the alveoli of molars in one specimen. According to VILA et al. (1993) alveolar bone loss predominantly affects premolar teeth. According to HAMP et al. (1997), periodontitis in dogs most frequently affects the caudal maxillary and mandibular premolars and molars. PENMAN and HARVEY (1990) found periodontitis in 80% of 4-year-old dogs. According to DE BOWES et al. (1996) and HUNGERFORD et al. (1999) periodontal changes may occur after tooth damage or may be an initial factor for tooth loss. Two of three examined wolf dentitions with periodontal lesions also had a complicated crown-root fracture. Due to pathological changes, affected teeth in all three individuals had partially or completely lost their function. Gray wolves, like all other carnivores (*Carnivora*) from the Canidae family, have a heterodont and secodont dentition. Occlusion of the mandibular first molar and the maxillary fourth premolar work like a pair of scissors especially designed to slice and shear flesh. Pathological changes on the teeth of one side of the jaw caused severe abrasion of the tooth crowns, with exposure of dentin on the opposite side of the jaw. This change was observed in all three specimens. These findings suggest that animals were exerting more chewing pressure on the opposite, unaffected, side of the jaw. According to HAMP et al. (1984) and HUNGERFORD et al. (1999) dental diseases are related to factors such as age, hygiene, nutrition, specific dietary imbalances and food consistency. Data on pathological changes of wolves' teeth contribute to knowledge of the biology of this large carnivore. The original cause of initial dental pathology remained unknown, but may even have occurred due to stochastic reasons. The average body mass of wolves from Croatia is 28 kg (KUSAK, 2002; KUSAK et al., 2005), while all three wolves with dental pathology had an above average body mass, which suggests that the described pathology did not affect predatory and feeding efficiency.

References

- DE BOWES, L. J., D. MOSIER, E. C. LOGAN, E. HARVEY, S. LOWRY, D. C. RICHARDSON (1996): Association of periodontal disease and histologic lesions in multiple organs from 45 dogs. *J. Vet. Dent.* 13, 57-60.
- GIPSON, P. S., W. BALLARD, R. M. NOWAK, D. MECH (2000): Accuracy and precision of estimating age of gray wolves by tooth wear. *J. Wildl. Manage.* 64, 752-758.
- GOMERČIĆ, T. (2005): Kraniometrijske i druge značajke populacije euroazijskog risa (*Lynx lynx*) u Hrvatskoj. Master of science thesis, University of Zagreb, Zagreb.
- HALE, F. A. (1998): Dental caries in dog. *J. Vet. Dent.* 15, 79-83.
- HAMP, S. E., S. E. OLLSON, K. FARSO-MADSEN, P. VIKLANDS, J. FORNELL (1984): A macroscopic and radiologic investigation of dental disease of the dog. *Vet. Radiol.* 25, 86-92.
- HAMP, S. E., M. HAMP, S. E. OLLSON, R. LINDBERG, P. SCHAUMAN (1997): Radiography of spontaneous periodontitis in dogs. *J. Periodontal Res.* 32, 589-597.
- HUBER, Đ., J. KUSAK, A. FRKOVIĆ, G. GUŽVICA, T. GOMERČIĆ (2002): Causes of wolf mortality in Croatia in the period 1986-2001. *Vet. arhiv* 72, 131-139.
- HUNGERFORD, L. L., M. A. MITCHELL, C. M. NIXON, T. E. ESKER, J. B. SULLIVAN, R. KOERKENMEIER, S. M. MARETTA (1999): Periodontal and dental lesions in raccoons from a farming and recreational area in Illinois. *J. Wildl. Dis.* 35, 728-734.
- KUSAK, J. (2002): Uvjeti za život vuka (*Canis lupus* L.) u Hrvatskoj. Dissertation. Faculty of Science, University of Zagreb, pp. 1-247.
- KUSAK, J., A. MAJIĆ SKRBINŠEK, Đ. HUBER (2005): Home ranges, movements, and activity of wolves (*Canis lupus*) in the Dalmatian part of Dinarids, Croatia. *Eur. J. Wildl. Res.* 51, 254-262.
- MILES, A. E. W., O. GRIGSON (1990): Colyers variations and diseases of the teeth of animals. Revised edition, Cambridge University Press, Cambridge. pp. 455-574.
- PENMAN, S., C. E. HARVEY (1990): Periodontal disease. In: *Manual of Small Animal Dentistry* (Crossley D. A., S. Penman, Eds.). BSAVA, Cheltenham. pp. 37-39.
- VERSTRAETE, F. J. M., R. J. VAN AARDE, B. A. NIEUWOUDT, E. MAUER, P. H. KASS (1996): The dental pathology of feral cats on Marion Island, part II: periodontitis, external odontoclastic resorption lesions and mandibular thickening. *J. Comp. Pathol.* 115, 283-297.
- VERSTRAETE, F. J. M. (1999): *Self Assessment Colour Review of Veterinary Dentistry*. Manson Publishing/The Veterinary Press, London. pp. 1-224.
- VERSTRAETE, F. J. M. (2003): Oral pathology. In: *Textbook of Small Animal Surgery* (Slater D. H., Ed.) 3rd ed., W. B. Saunders, Philadelphia. pp. 2683-2651.
- VILA, C. E., C. V. URIOS, J. CASTROVIEJO (1993): Tooth losses and anomalies in the wolf (*Canis lupus*). *Can. J. Zool.* 71, 968-971.

Received: 5 April 2006

Accepted: 28 May 2007

PAVLOVIĆ, D., T. GOMERČIĆ, G. GUŽVICA, J. KUSAK, D. HUBER: Pojavnost patoloških promjena na vučjim zubima (*Canis lupus L.*) u Hrvatskoj. Vet. arhiv 77, 291-297, 2007.

SAŽETAK

Pregledane su 34 lubanje sivoga vuka (*Canis lupus*) i opisane stečene patološke promjene na zubima. Lubanje su potjecale od vukova koji su zbog različitih razloga stradali u Hrvatskoj od 1997. do 2006. godine. Dob tih vukova kretala se u rasponu od sedam mjeseci do osam i pol godina. Patološke promjene na alveolarnoj kosti zabilježene su na zubalima triju lubanja, odnosno na 8,8% pregledanih lubanja. Sve lubanje na čijim su zubalima nađene patološke promjene pripadale su ženkama starijima od dvije godine. U dvije jedinke opisan je periodontitis s promjenama u alveolarnoj kosti donjega četvrtoga pretkutnjaka (P4), a u jedne na gornjem prvom kutnjaku (M1). Potpuna fraktura zuba opisana je u dvije jedinke. U sve tri jedinke na pretkutnjacima i kutnjacima bio je prisutan i karijes i to na zubima gornje čeljusti kod jedne, donje čeljusti kod druge, a kod treće na zubima donje i gornje čeljusti. U hrvatskoj literaturi dosad nisu opisane patološke promjene na zubalu u ove vrste velike zvijeri. Podaci o patološkim promjenama na vučjim zubima pridonose boljem poznavanju biologije, osobito čimbenika koji utječu na životni vijek ove vrste.

Ključne riječi: vuk, zubi, periodontitis, karijes, patološke promjene, Hrvatska
