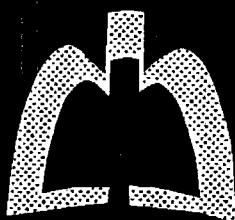


PEDIATRIC PULMONOLOGY

Volume 34, Number 5, November 2002



 **WILEY-LISS**
ISSN 8755-6863

This journal is online
 **Interscience**
www.interscience.wiley.com

Pulmonary Alveolar Microlithiasis in Childhood: Clinical and Radiological Follow-Up

Stipan Jankovic, MD, PhD,^{1*} Neven Pavlov, MD, PhD,² Ante Ivkovic, MD,³ Ivana Erceg, MD,³
Meri Glavina-Durdov, MD, PhD,⁴ Jadranka Tocilj, MD, PhD,⁵ Slavica Dragisic-Ivulic, MD,²
and Dragan Primorac, MD, PhD²

Summary. This report describes a case of pulmonary alveolar microlithiasis that was diagnosed in an 8.5-year-old girl by high-resolution computed tomography (CT) and open lung biopsy. Presence of symptoms (productive cough, fever), their periodic occurrence (lasting up to 1 week), and comparatively long asymptomatic periods should be emphasized. Despite extensive X-ray abnormalities, tests of pulmonary interstitium involvement and exercise tests revealed normal results. A therapeutic regimen, including disodium etidronate, was administered for 18 months with no significant clinical or radiological improvement. *Pediatr Pulmonol.* 2002; 34:384–387.

© 2002 Wiley-Liss, Inc.

Key words: pulmonary alveolar microlithiasis; high-resolution computed tomography; disodium etidronate.

INTRODUCTION

Pulmonary alveolar microlithiasis (PAM) is a rare disorder of unknown etiology. As of 1996, only 36 cases of PAM were recorded in children under age 12 years.^{1–3} It occurs predominantly in adults in the second decade of life, with slightly more females affected.⁴ Until 1993, 173 cases had been reported from all over the world, and for unknown reasons PAM is most prevalent in Turkey.⁵ PAM is characterized by intraalveolar calcifications diffusely arranged in the middle and lower parts of lungs. No general disturbance in calcium metabolism has been demonstrated.⁶ Children with PAM are commonly asymptomatic, although occasionally chronic cough as a nonspecific symptom is present. The diagnosis is usually based on the characteristic miliary (spotlike) “sand storm” changes on chest X-ray, usually detected incidentally. In some cases, clinical and radiological findings may resemble miliary tuberculosis.⁷

CASE REPORT

M.V., an 8.5-year-old girl, was sent from a regional hospital in Bosnia and Herzegovina with a diagnosis of miliary tuberculosis. She was admitted to our Department of Pediatrics because of pain in the chest and productive cough. The parents were not consanguineous; both were healthy, as was a 5-year-old brother (all had normal chest X-rays). History revealed that the patient, from age 4 months up to approximately 1 year, suffered from frequent high temperatures (up to 41°C) lasting up to a week, with a clinical picture of bronchitis. She was treated with antibiotics and mucolytic agents. Thereafter, she was

healthy until age 8 years. At that time, her symptoms reappeared: temperature up to 39°C, bronchitis, pneumonia, and cough with expectoration of purulent sputum lasting up to 10 days. Afterwards she would become afebrile and feel subjectively better.

This time the patient was sent to the hospital because of pain in the chest and cough. At admission she was eupneic and afebrile, with a productive cough. Her body weight was in the 10th and her height between 10th and 25th percentiles. Breath sounds were diminished over the lungs bilaterally (more markedly in the basal zones). Laboratory findings included an elevated erythrocyte sedimentation rate (50 mm/hr). Complete blood counts, urine, electrolytes in serum, calcium, phosphorus, alkaline phosphatase, urea, creatinine, uric acid, C3 and C4 complement

¹Department of Radiology, University Hospital Split, Split, Croatia.

²Department of Pediatrics, University Hospital Split, Split, Croatia.

³Department of Genetics and Developmental Biology, University of Connecticut School of Medicine, Farmington, Connecticut.

⁴Department of Pathology, University Hospital Split, Split, Croatia.

⁵Department of Pulmonology, University Hospital Split, Split, Croatia.

*Correspondence to: Stipan Jankovic, M.D., Ph.D., Department of Radiology, University Hospital Split, 21000 Split, Croatia.
E-mail: dragan.primorac@st.tel.hr

Received 9 January 2000; Accepted 12 January 2001.

DOI 10.1002/ppul.10183

Published online in Wiley InterScience (www.interscience.wiley.com).

components, fibrinogen, C-reactive protein, immunodiffusion (IgA, IgG, IgM), parathyroid hormone, and acid-base status were normal. Electrophoresis of serum proteins (EFP) indicated slightly elevated total proteins, α_1 , α_2 , and β -globulins. Ratio of Ca/creatinine (in 24 hr urine) was 1.48 mmol/day (2.47 mg/kg/day; within normal limits). Ratio of Ca (urine)/creatinine (urine) was 0.07 (no hypercalciuria). PPD3 IU showed 6 mm induration (she had the BCG scar). The *M. tuberculosis* culture from gastric lavage taken for 3 successive days was negative.

Chest radiographs revealed bilateral diffuse punctiform shadows in the middle and lower pulmonary fields (Fig. 1). High-resolution computed tomography (CT) was performed and showed tiny miliary consolidations, primarily in an alveolar setting, symmetrically in both lungs (Fig. 2).

Open biopsy of the right lung lobe revealed firm and gritty subpleural pulmonary tissue. Histologically, alveoli contained numerous concentrically lamellated concretions measuring 50–100 μm in diameter (Fig. 3). Histohistochemically, they are calcospherites which have polysaccharide-rich core and a rim of tricalcium phosphate with small amounts of magnesium and aluminium (periodic acid-Schiff reagent method for mucopolysaccharides was positive, von Kossa alizarin red method for calcium was




Fig. 1. Chest X-ray of 8.5-year-old girl. Parenchyma punctiform shadows bilaterally diffuse in lungs, predominantly in the middle and lower fields, more to the center where they form modular shadows up to a few millimeters in diameter.

ABBREVIATIONS

BAL	Bronchoalveolar lavage
BCG	Bacillus Calmette-Guerin
CT	Computed tomography
EFP	Electrophoresis of serum proteins
HRCT	High-resolution computed tomography
PAM	Pulmonary alveolar microlithiasis
PPD	Purified protein derivate

Childhood Pulmonary Alveolar Microlithiasis

385

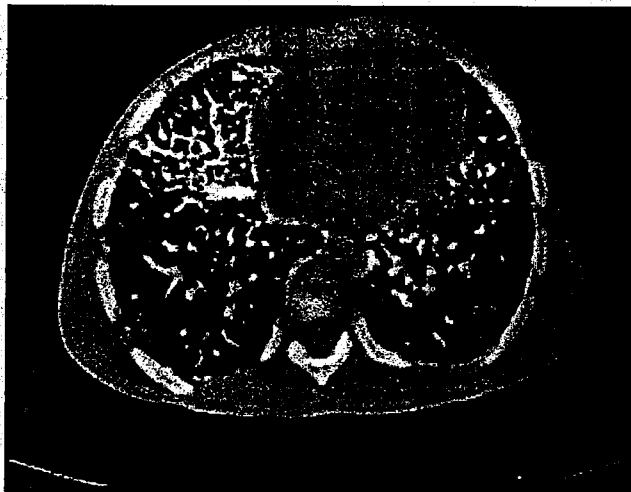


Fig. 2. High-resolution CT of the thorax (4- and 2-mm scans). Tiny, firm miliary consolidations, primarily in an alveolar setting, can be seen symmetrically, mainly hilopetally in both lobes of the lungs. Interstitial fibrous changes in the form of netlike and stripped interstitial beams are also present, predominantly in anterior segments of lung lobes. Elements of retractive pulmonary changes with compensatory local hyperinsufflations can also be seen.

positive). Intraalveolar septa are thin, with mild chronic inflammatory cell infiltrates without significant fibrosis.

Pulmonary function tests were normal (spirometry, flow-volume curve, diffusing capacity of the lungs, and exercise tests).

The disodium salt of 1-hydroxyethylidene diphosphonic acid (disodium etidronate) was used at a dose of 400 mg per day for 18 months. Despite this therapy, no significant clinical or radiological improvement was reported (Fig. 4).

DISCUSSION

The first report of a high incidence of PAM in family members was published in 1954.⁸ Further, a number of

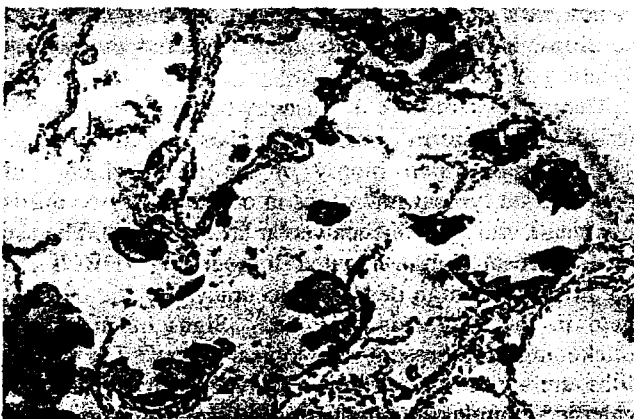

Fig. 3. Pathohistological findings. Alveoli contained numerous concentrically lamellated concretions measuring 50–100 μm (von Kossa, $\times 400$).

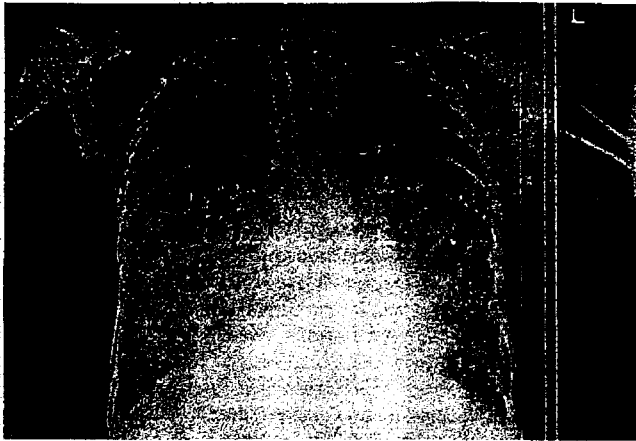

Fig. 4. Chest X-ray of 8.5-year-old girl after 18 months of treatment with disodium etidronate. Despite therapy, no radiological improvement was seen (compare with Fig. 1).

papers published on this condition underline a familial component of PAM in siblings,⁹ relatives,¹ and twins,^{9,10} suggesting the possible autosomal-recessive character of the disease. So far, no definitive predisposing factors have been identified, such as an environmental exposure to toxic substances, or airborne or infectious agents.

Children with PAM are commonly asymptomatic; sometimes a chronic cough occurs as the main symptom. However, in most cases, a persistent cough of more than 3 years' duration,¹¹ clinically significant interstitial pulmonary disease,¹² and lymphocytic interstitial pneumonitis have been reported. Hemoptysis has been reported in one patient.¹³ While expectoration of unidentifiable microliths has not been reported in children, there are several reports of microliths in sputum specimens of adults.¹⁴ Dyspnea develops with the progress of the disease, and it may spread slowly, having benign characteristics,⁶ even though there is no report of spontaneous remission of the disease. With the progress of PAM, pulmonary insufficiency with cyanosis, hypoxya, and clubbing of fingers develops, and death results from impaired pulmonary function and cor pulmonale.

The diagnosis of PAM is usually based on the characteristic "sand storm" changes on chest X-ray. It can be confirmed by open biopsy of the lung, which will demonstrate typical microliths in one third to two thirds of alveoli, and by bronchoalveolar lavage (BAL). The use of high-resolution computed tomography (HRCT), a method with a high degree of accuracy, may be of great help in the diagnosis of PAM.¹⁵ Signs of interstitial thickening may present radiological signs.¹⁶ The microliths are characterized by intraalveolar depositions of calcified granules, usually varying in size from about 0.1–0.3 mm in diameter.

Our patient had the following symptoms: pain in the chest, intensive cough, abundant expectoration of purulent

sputum, high temperature with duration of a week per episode. Between the above-mentioned episodes there were longer asymptomatic periods (some of them lasting for a couple of years). Our patient was sent for hospital treatment with a diagnosis of miliary tuberculosis. She had her first chest X-ray done immediately before admission. Despite impressive changes on the chest X-ray, no sign of pulmonary function disorders could be found (normal findings of spirometry, flow-volume curve, diffusing capacity of the lungs, and exercise tests) which would suggest any extensive disease of the pulmonary interstitium. HRCT of the lungs revealed irregularly arranged changes in the lungs (most pronounced in the middle and lower lung fields, more to the center). Interstitial fibrous changes were also present, mainly in the anterior lung segments, with retractive changes of the lung parenchyma and compensating local hyperinsufflations. We could find no evidence of ventilation disorders. No specific therapy of PAM has been reported. There are a few reports of lung transplantation, which might be the only therapy for patients with progressive disease.¹⁷ Glucosteroid therapy may lead to improvement of pulmonary function and exercise tolerance.¹² Gocmen et al.¹⁸ gave diphosphonate and disodium etidronate to a 3.5-year-old-girl with PAM in order to inhibit the growth of hydroxyapatite microcrystals (duration, 36 months at a dose of 15 mg/kg). They obtained radiological improvement in the form of some clearing of lung bases, as well as subjective improvement of the general condition.

We treated our patient for 18 months with disodium etidronate, but the results suggest no radiological improvement (Fig. 4). Similar results were published by Mariotta et al.¹⁹ Our experience allows us to emphasize the importance of HRCT in diagnosis of PAM in children. Although the final evidence of diagnoses can be obtained only by lung biopsy, HRCT can yield highly accurate data on the involvement and intensity of pulmonary changes, which are particularly important when pulmonary function tests are normal. We started the therapy with disodium etidronate, firmly believing that a control HRCT will be of great help in the evaluation of its efficiency.

REFERENCES

1. Biary MS, Adullah MA, Assaf HM, Wazzan A. Pulmonary alveolar microlithiasis in a Saudi child and two cousins. *Ann Trop Paediatr* 1993;13:409–413.
2. Schmidt H, Lorcher U, Kitz R, Zielen S, Ahrens P, Koning R. Pulmonary alveolar microlithiasis in children. *Pediatr Radiol* 1996;26:33–36.
3. Wallis C, Whitehead B, Malone M, Dinwiddie R. Pulmonary alveolar microlithiasis: diagnosis by transbronchial biopsy. *Pediatr Pulmonol* 1996;21:62–64.
4. Mariotta S, Guidi L, Papale M, Ricci A, Bisetti A. Pulmonary alveolar microlithiasis: review of Italian reports. *Eur J Epidemiol* 1997;13:587–903.

Childhood Pulmonary Alveolar Microlithiasis 387

5. Ucan ES, Keyf AI, Aydılek R, Yalcin Z, Sebit S, Kudu M, Ok U. Pulmonary alveolar microlithiasis: review of Turkish reports. *Thorax* 1993;48:171-173.
6. Phelan PD, Olinsky A, Robertson C. Pulmonary alveolar microlithiasis. In: Phelan PD, Olinsky A, Robertson C, editors. *Respiratory illness in children*. London: Blackwell Scientific Publications; 1994. p 338-341.
7. Shisido S, Toritani T, Nakano H, Tokushima T. A case of alveolar microlithiasis which developed spontaneous pneumothorax due to progression of emphysematous bullae during 34 years after established diagnoses. *Nippon Kyobu Shikaku Gakkai Zasshi* 1993;31:881-885.
8. Mikhail V. Pulmolithiasis endalveolaris et interstitialis difusa. *Klin Med (Mosk)* 1954;32:31.
9. Arguelles M, Quinonez MG, Cicero R, Giacinti P. Pulmonary alveolar microlithiasis in two siblings. *Rev Invest Clin* 1993;45:593-596.
10. Caffrey PR, Captain MC, Altman RS. Pulmonary alveolar microlithiasis occurring in premature twins. *J Pediatr* 1965;16:758-763.
11. Turktas I, Saribas S, Balkanci F. Pulmonary alveolar microlithiasis presenting with chronic cough. *Postgrad Med J* 1993;69:70-71.
12. Rajen FA, Schoenfeld B, Wiesemann HG. Pulmonary alveolar microlithiasis and lymphocytic interstitial pneumonitis in a ten year old girl. *Eur Respir J* 1992;5:1283-1285.
13. Thind GS, Bhatia JL. Pulmonary alveolar microlithiasis. *Br J Dis Chest* 1978;72:151.
14. Tao LC. Microliths in sputum specimens and their relationship to pulmonary alveolar microlithiasis. *Am J Clin Pathol* 1978;69:482.
15. Korn MA, Schurawitzki H, Klepetko W, Burghuber OC. Pulmonary alveolar microlithiasis: findings on high resolution CT. *AJR* 1992;158:981-982.
16. Melamed JW, Sostman HD, Ravin CE. Interstitial thickening in pulmonary alveolar microlithiasis; an underappreciated finding. *J Thorac Imaging* 1994;9:126-128.
17. Stamatis G, Zerkowski HR, Doetsch N. Sequential bilateral lung transplantation for pulmonary alveolar microlithiasis. *Ann Thoracic Surg* 1993;56:972-975.
18. Gocmen A, Toppare MF, Kiper N, Buyukpamukcu N. Treatment of pulmonary alveolar microlithiasis with diphosphonate—preliminary results of a case. *Respiration* 1992;59:250-252.
19. Mariotta S, Guidi L, Mattia P, Torelli L, Pallone G, Pedicelli G, Bisetti A. Pulmonary microlithiasis. Report of two cases. *Respiration* 1997;64:165-169.