

# BILE DUCT INJURIES DURING OPEN AND LAPAROSCOPIC CHOLECYSTECTOMY AT SESTRE MILOSRDNICE UNIVERSITY HOSPITAL FROM 1995 TILL 2001

Zvonimir Puljiz, Tomislav Kuna, Bjorn Dario Franjić, Hrvoje Hochstädter, Aljoša Matejčić  
and Miroslav Bekavac Bešlin

University Department of Surgery, Sestre milosrdnice University Hospital, Zagreb, Croatia

**SUMMARY** – Bile duct injury is one of the most severe complications of cholecystectomy. Several multi-center studies have demonstrated these injuries to be more commonly associated with laparoscopic cholecystectomy than with open cholecystectomy. During a 7-year period, from January 1995 till December 2001, 4528 patients underwent cholecystectomy at the University Department of Surgery, Sestre milosrdnice University Hospital in Zagreb, Croatia. Laparoscopic cholecystectomy was performed in 2657 (58%) of these patients. Bile duct injury was recorded in 15 (0.33%) patients, three (0.16%) of them submitted to open cholecystectomy. Of the latter, partial transection of the common bile duct occurred in two patients and complete transection in one patient. In the series of patients with laparoscopic cholecystectomy, bile duct injury occurred in 12 (0.45%) patients, with complete transection of the common bile duct observed in five, partial transection in three, and bile duct injury with a metal clip in three patients. Common bile duct stricture without apparent intraoperative injury developed in one patient during the late postoperative period. All these 15 patients with iatrogenic bile duct injury that occurred during either open or laparoscopic cholecystectomy were surgically managed. Roux-en-Y choledochojunostomy was performed in nine patients, whereas the remaining six patients underwent common bile duct reconstruction by creating a terminoterminal anastomosis and T-tube insertion. Stricture of the anastomosis in the late postoperative period developed in five of these patients, who underwent secondary reconstruction of biliary continuity by Roux-en-Y choledochojunostomy.

*Key words: Common bile duct injuries, etiology; Common bile duct, surgery; Cholecystectomy laparoscopic, methods; Intraoperative complications, surgery*

## Introduction

Cholecystectomy is the most frequently performed operation in abdominal surgery<sup>1</sup>. Laparoscopic cholecystectomy replacing open cholecystectomy is now performed in more than 80% of patients surgically treated for symptomatic gallstones<sup>2</sup>. Laparoscopic cholecystectomy has

many advantages including less postoperative pain, absence of postoperative ileus, reduced hospital stay, faster convalescence, and satisfactory cosmetic result. The mortality rate after open and laparoscopic cholecystectomy is 0.5% and 0.014%-0.13%, respectively, whereas the respective morbidity rates are 15% and 0.14%-0.65%<sup>3</sup>.

The complications which may occur during and after any laparoscopic operation are grouped as follows:

- 1) injuries caused by Veress needle or trocar insertion: bleeding from epigastric vessels, injury of large retroperitoneal vessels, injuries of abdominal organs, postoperative wound infection, and postoperative hernia;

Correspondence to: *Zvonimir Puljiz, M. D.*, University Department of Surgery, Sestre milosrdnice University Hospital, Vinogradska c. 29, HR-10000 Zagreb, Croatia

E-mail: [zvonimir.puljiz@zg.hinet.hr](mailto:zvonimir.puljiz@zg.hinet.hr)

Received September 17, 2002, accepted in revised form August 29, 2003

- 2) injuries caused by laparoscopic instruments:
  - mechanical: bile duct injuries, liver hemorrhage, pneumothorax due to diaphragm injury,
  - thermal: late common bile duct stricture, bowel necrosis; and
- 3) complications of pneumoperitoneum: ventricular arrhythmia, reduction of cardiac preload, reduction of functional residual lung capacity, CO<sub>2</sub> embolization, pneumothorax, pneumomediastinum.

Additional complications associated with laparoscopic cholecystectomy are bile duct injuries, bile leak from accessory bile ducts or due to clip displacement from the cystic duct, retained stones in the common bile duct, perforation of the gallbladder, bleeding from the liver, cystic or hepatic artery, and subphrenic abscess. Bile duct injury can be iatrogenic or may occur due to abdominal trauma.

Bile duct injuries are most severe complications of laparoscopic cholecystectomy. According to the results of several multicenter studies, the rate of these injuries ranges from 0.06% to 0.5%<sup>3-8</sup>. The rate of bile duct injuries on laparoscopic cholecystectomy is 2- to 3-fold that recorded on open cholecystectomy, however, the total number of complications is lower in the former. There are several classifications of the lesions of bile duct injuries based on their extent and etiology (Siewert, Waye)<sup>3,9</sup>. The strictures (and injuries) can also be classified according to the location on the common bile duct (Bismuth)<sup>3</sup>.

The most common reasons for bile duct injury on laparoscopic cholecystectomy are:

- 1) difficult intraoperative findings with altered anatomic relations in the area, which is quite common in acute or subacute cholecystitis;
- 2) unclear identification of the Calot's triangle structures;
- 3) intraoperative bleeding from the cystic or hepatic artery; and
- 4) frequent anatomic variation in the region (of cystic duct or cystic artery) and the lack of their identification and recognition.

## Patients and Methods

Our retrospective analysis showed that 4528 patients had undergone cholecystectomy at the University Department of Surgery, Sestre milosrdnice University Hospital, Zagreb, Croatia, during the period from January 1995 till December 2001. There were 3622 (80%) women and 906 (20%) men, mean age 49.6 (range 16-85) years. Symptom-

atic gallstones were the indication for cholecystectomy, either as an elective operation or as an emergency procedure for acute cholecystitis. Preoperative evaluation included clinical examination, standard laboratory tests, abdominal ultrasonography (US), and endoscopic retrograde cholangiopancreatography (ERCP) in patients suspected of bile duct stones or stricture of the papilla of Vater.

In total, 2657 (58%) patients were operated on by the laparoscopic technique (Table 1). The percentage of laparoscopic cholecystectomy showed a rising tendency and reached 68% in the period after 1998. The technique used at our Department is the French or European method of laparoscopic cholecystectomy using 3 or 4 ports, their basis being founded by Mouret<sup>3</sup>. The year 1995 was chosen as the starting point for this retrospective study because a considerable number of laparoscopic cholecystectomies had been performed at that time. The technique was adopted earlier. In the same year, the first iatrogenic bile duct injury was recorded<sup>10</sup>. ERCP was performed in patients suspected of having sustained iatrogenic bile duct injury to determine the localization of the injury. All patients with bile duct injuries associated with either open or laparoscopic cholecystectomy were treated surgically with either Roux-en-Y choledochojejunostomy or reconstruction of the common bile duct by creating a termino-terminal (TT) anastomosis with T-tube insertion. Late strictures of the anastomosis were treated surgically by resection of the site of stenosis and creation of a new Roux-en-Y choledochojejunostomy.

*Table 1. The total Number of cholecystectomies and iatrogenic bile duct injuries at the university department of Surgery, Sestre milosrdnice University Hospital, Zagreb, from 1995-2001*

Cholecystectomy	No. of patients (%)	No. of bile duct injuries (%)
Laparoscopic	2657 (58)	12 (0.45)
Open	1873 (42)	3 (0.16)
Total	4528 (F 3622/80%)	15 (0.33)

## Results

Bile duct injury during cholecystectomy was recorded in 15 (0.33%) of 4528 patients, i.e. in three and 12 patients operated on by open cholecystectomy and laparoscopic cholecystectomy, respectively (Table 1). Of these 15 patients with iatrogenic bile duct injury, five (33%) were operated on for subacute or acute cholecystitis, and the

Table 2. Types of bile duct injuries on laparoscopic cholecystectomy, time of recognition and mode of treatment

Type of injury	No. of patients (%)	Time of recognition			Mode of treatment	
		Intraop.	Postop. Early	Postop Late	TT anastomotic	Biliodigestive anastomosis
Metal clip	4 (33)	1	3		2	2
Partial transection	2 (16.7)	1	1		2	
Complete transection	5 (42)	2	3		1	4
Stricture	1 (0.83)			1		1
Total	12	4 (33%)	7 (67%)	1	5 (42%)	7 (58%)

remaining ten patients underwent elective operation for symptomatic gallstones.

Bile duct injury occurred in three patients (two female and one male) on open cholecystectomy. One of these patients was operated on in the state of acute inflammation, empyema of the gallbladder. In all three patients, the lesion was recognized in the early postoperative period and iatrogenic injury was verified by ERCP. Reoperation was performed in the early postoperative period, 5-17 days of primary operation. Partial transection of the common bile duct was observed in two patients, and complete transection in one patient. Roux-en-Y choledochojejunostomy was performed in two of these patients, and TT anastomosis of the common bile duct with T tube insertion in one patient.

Bile duct injury during laparoscopic cholecystectomy was recorded in 12 patients (three male and nine female). Four (33%) of these patients were operated on for acute or subacute cholecystitis, whereas eight patients underwent elective operation for symptomatic gallstones. In six

patients the injury occurred during the 1995-1998 period, whereas in the remaining six patients it occurred after 1998. Complete transection of the common bile duct was recorded in five and partial transection in three patients. Bile duct injury due to metal clip application occurred in three patients, and stricture of the common bile duct without apparent intraoperative injury was detected in one patient as a late postoperative complication (Table 2). Intraoperatively, bile duct injury was recognized in four of 12 (33%) patients submitted to laparoscopic cholecystectomy, with conversion to open surgery in three of these patients. In one patient, reoperation was done during the early postoperative period. The remaining eight patients in whom injuries were postoperatively recognized were surgically treated during the early postoperative period, 4-22 days of laparoscopic cholecystectomy. Most patients developed jaundice, bile leak from the abdominal drain was noted, and two patients developed biliary peritonitis. A common bile duct injury was demonstrated by ERCP in all patients. Reconstruction of the common bile duct was

Table 3. Reoperations for late anastomosis strictures following operative treatment for bile duct injuries during laparoscopic cholecystectomy

Type of injury	No. of patients	Primary treatment		Time of occurrence stricture	Way of Secondary treatment
		Biliodigestive anastomosis	TT anastomosis		
Complete transection	3	3		6 months to several years	3 of which: – 1 previous PTC dilatation of the site of stenosis – 1 liver transplantation
Stricture	1		1	3 months	1
Metal clip	1		1	6months	1
<b>Total</b>	<b>5 of 12 (42%)</b>				<b>5 of 5 (100%)</b>

Table 4. Relationship between the rate of reoperation, and time and mode of treatment (bile duct injuries on laparoscopic cholecystectomy)

Primary treatment	No. of patients (N = 12)	Reoperation for late anastomosis stricture
TT anastomosis	5	2 (29%)
Biliodigestive anastomosis	7	3 (43%)
Time to primary treatment:		
intraoperative conversion	3	2 (67%)
early postoperative period	8	3 (37.5%)

carried out by creating a TT anastomosis with T tube placement in five patients, and by Roux-en-Y choledochojejunostomy in seven patients (Table 2).

Stricture of the anastomosis developed in five (42%) of these 12 patients during the late postoperative period (3 months to several years of laparoscopic cholecystectomy) and was demonstrated by ERCP. Secondary reconstruction of biliary continuity was carried out in all five patients by resecting the site of stenosis and creating a new biliodigestive anastomosis by Roux-en-Y choledochojejunostomy. Three of these patients were operated on at the University Department of Surgery, Sestre milosrdnice University Hospital in Zagreb (Tables 2-4).

### Summary of patients reoperated on

1) One patient with complete transection of the common bile duct on laparoscopic cholecystectomy was treated with Roux-en-Y choledochojejunostomy. The patient developed liver insufficiency and underwent liver transplantation several years later at another hospital.

2) In one patient, a common bile duct injury on laparoscopic cholecystectomy caused by metal clip applica-

tion was intraoperatively recognized and the procedure was converted. The metal clip was removed and TT anastomosis of the common bile duct with T tube insertion was created. The patient was reoperated on three months later for common bile duct stenosis, by resection of the site of stenosis and creation of a new Roux biliodigestive anastomosis.

3) In one patient, complete transection of the common bile duct on laparoscopic cholecystectomy was intraoperatively recognized. The patient underwent reoperation with Roux-en-Y choledochojejunostomy in the early postoperative period. The patient was hospitalized on several occasions for cholangitis and evaluation of subhepatic collection. Stricture of the common bile duct was verified 6 months of laparoscopic cholecystectomy. Dilatation of the stenosis and stent insertion on PTC were performed at another hospital. Because of the occurrence of another common bile duct stricture, the patient was reoperated again at another hospital one year of laparoscopic cholecystectomy.

4) One patient with complete transection of the common bile duct on laparoscopic cholecystectomy was treated by Roux-en-Y choledochojejunostomy. One year of laparoscopic cholecystectomy the patient was reoperated on for cholangitis due to stricture of the common bile duct. Reconstruction of the common bile duct was performed by resection of the site of stenosis and creation of a new Roux-en-Y choledochojejunostomy.

5) Eight days of laparoscopic cholecystectomy one patient was reoperated on for peritonitis caused by secretion from an aberrant bile duct. No common bile duct injury was found. Six months of laparoscopic cholecystectomy the patient was reoperated on for common bile duct stricture. The site of stenosis was resected and a new Roux-en-Y choledochojejunostomy was performed.

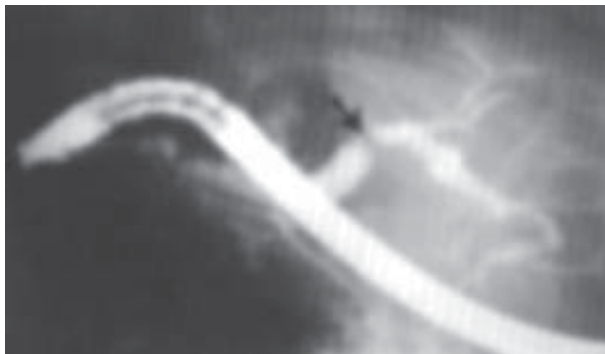


Fig. 1. ERCP: stricture of the common bile duct (arrow).

## Discussion

The total number of complications is lower with laparoscopic than with open cholecystectomy. Bile duct injury is the most severe complication of cholecystectomy and is more common on laparoscopic than on open cholecystectomy. According to our results, the rate of iatrogenic bile duct injuries associated with laparoscopic and open cholecystectomy was 0.45% and 0.16%, respectively.

Bile duct injuries occurring during open and laparoscopic cholecystectomy may be recognized intraoperatively or during the early or late postoperative period. According to various authors, 27% to 66% of iatrogenic bile duct injuries are recognized intraoperatively<sup>3-8</sup>. At our hospital, the injury was recognized intraoperatively in one third of patients, being detected as bile leak into the subhepatic space.

Clinical presentation of bile duct injury in the early postoperative period includes pain, nausea, vomiting, fever, jaundice, prolonged bile secretion from the abdominal drain (which may also be the only sign), or peritonitis. Stricture of the common bile duct that occurs in the late postoperative period is accompanied by repeat bouts of cholangitis or peritonitis. Any unexpected clinical presentation in the postoperative period should raise suspicion of complications. To estimate the site and severity of the lesion, additional diagnostic procedures are needed, including abdominal US (for visualization of subhepatic collection and dilatation of bile ducts), computed tomography (the site of injury is demonstrated in 88% of cases), ERCP (most important method for the diagnosis, the site of injury demonstrated in 97% of cases), PTC, and MRCP (ERCP shows only an approximate position of complete bile duct transection, thus PTC or MRCP being necessary). We performed US and ERCP in all our patients clinically suspect of bile duct injury. Complete transection of the common bile duct was the most common injury.

When the injury is verified, biliary continuity should be reconstructed and peritonitis treated. The following can be done, depending on the type and severity of common bile duct injury:

- 1) endoluminal placing of a stent in the common bile duct (endoscopically);
- 2) TT anastomosis of the common bile duct with T tube insertion;
- 3) Roux-en-Y choledochojejunostomy; and
- 4) reconstruction of biliodigestive continuity by jejunum interpositioning<sup>11</sup>.

At our hospital, common bile duct injuries were generally treated by Roux-en-Y choledochojejunostomy in patients with complete transection or stricture of the common bile duct, whereas partial transection of the common bile duct was generally treated by TT anastomosis and T tube insertion.

Strictures of the common bile duct occurring in the late postoperative period were generally managed as follows:

- 1) high strictures (Bismuth II, III and IV): the only option is surgical reconstruction by resection of the site of stenosis and creation of biliodigestive anastomosis (hepatojejunal); and
- 2) low strictures (Bismuth I, at least 2 cm from the left and right bile duct confluence): surgical reconstruction or common bile duct dilatation on PTC followed by endoluminal stenting.

The iatrogenic bile duct injuries associated with laparoscopic cholecystectomy were equally distributed in the first and second half of the study period, i.e. six patients before and after 1998 each. Although a higher rate of common bile duct injuries would be expected in the period before 1998 due to the surgeons' learning the technique, the lack of its decline in the period after 1998 may be explained by the greater number of patients operated on laparoscopically in general as well as of the patients operated on for acute and subacute cholecystitis with all accompanying discomforts and difficult intraoperative findings. Three of the four patients with common bile duct injury associated with laparoscopic cholecystectomy performed for subacute or acute cholecystitis were operated on after 1998.

## Conclusion

On laparoscopic cholecystectomy, the rate of common bile duct injuries is 3-fold that on open cholecystectomy (0.45% *vs* 0.16%). The most common type of iatrogenic bile duct injury is complete transection, accounting for 42% of these injuries. The treatment of common bile duct injuries is burdened with a high number of anastomosis strictures in the late postoperative period, which occurred in 42% of the patients reoperated on. The number of patients requiring reoperation was relatively lower when the iatrogenic injury was treated in the early postoperative period than intraoperatively at the time of injury recognition (37.5% *vs* 67%). The expected reduction in the rate of iatrogenic bile duct injuries on laparoscopic cholecystectomy in the second half of the study period failed to oc-



cur, which was explained by the frequent operative treatment of patients with difficult intraoperative findings and constant influx of surgeons entering the program of laparoscopic cholecystectomy.

Although the latest experience has shown a decrease in the rate of iatrogenic bile duct injuries associated with laparoscopic cholecystectomy, it is not possible to avoid them completely. Therefore, we cannot put too much emphasis on the importance of prevention as the most relevant factor in reducing the number of iatrogenic lesions of the common bile duct during laparoscopic cholecystectomy. The prevention includes the following:

- clear visualization and identification of all structures of Calot's triangle before applying metal clips and dividing the structures,
- clipping the cystic arteries before binding the cystic duct,
- awareness of the frequent presence of anatomic variation in the region,
- performing surgery in the early stage of acute cholecystitis, and
- not delaying conversion to open surgery when necessary.

## References

1. MIJIĆ A, BEKAVAC BEŠLIN M, HOCHSTÄDTER H, GEORGIJEVIĆ A, FERENČIĆ Ž, HORŽIĆ M. Laparoscopic cholecystectomy: our first 100 patients. *Acta Clin Croat* 1996;35:71-4.
2. NURIAK, MURAT K, MUTLU D, ERHAN R, MESUTA, METE D. A risk score for conversion from laparoscopic to open cholecystectomy. *Am J Surg* 2001;181:520-5.
3. ČALA Z. Laparoskopiska kolecistektomija. Zagreb: GHZ, 2001:182-92.
4. SOLHEIM K, BUANES T. Bile duct injury in laparoscopic cholecystectomy. *Int Surg* 1995;80:361-4.
5. BERGMAN JJ, Van den BRINK GR, RAUWS EA, de WIT L, OBERTOP H, HUIBREGTSE K, TYTGAT GN, GOUMA DJ. Treatment of bile duct lesions after laparoscopic cholecystectomy. *Gut* 1996;38:141-7.
6. ADAMSEN S, HANSEN OH, FUNCH-JENSEN P, SCHULZE S, STAGE JG, WARAS P. Bile duct injury during laparoscopic cholecystectomy, a prospective nationwide series. *J Am Coll Surg* 1997;184:571-8.
7. BRESSANI DOLDI S, MARINONI M, LATTUADA E, MICHELETTI G, ZAPPA MA. Complete section of the main bile duct during laparoscopic cholecystectomy. Surgical treatment. *Minerva Chir* 2000;55:377-81.
8. DECKER D, KANIA U, DECKER P, LOW A, ILIRNER K. Bile duct injuries after laparoscopic cholecystectomy. *Zentralbl Chir* 1995;120:467-71.
9. SIEWERT JR, UNGEHEUERA, FEUSSNER H. Bile duct lesions in laparoscopic cholecystectomy. *Chirurg* 1996;67:467.
10. HOCHSTÄDTER H, BEKAVAC BEŠLIN M, MIJIĆ A, GEORGIJEVIĆ A. Laparoscopic surgery at the Sestre milosrdnice University Hospital, Zagreb. *Acta Clin Croat* 1996;35:41-3.
11. PIETSCH M, FECHTIG T, FRIEDRICH J, BREUING D, ERBARD J. Long-term follow-up of bile duct injury by laparoscopic cholecystectomy and reconstruction with jejunum interposition. *Chirurg* 2000;71:1500-3.
12. GOUMA DJ, RAUWS EA, KEULENTANS YC, ARGNTATTN JJ, HUIBREGTSE K, OBERTOP H. Bile duct injuries after laparoscopic cholecystectomy. *Ned Tijdschr Geneesk* 1999;143:606-11.
13. HELLINGER A, LANGE R, PEITGEN K, STEPBAN V, KMUSE U, EZBANL J. Bile duct lesions in laparoscopic cholecystectomy – methods of reconstruction and results. *Zentralbl Chir* 1997;122:1092-8.
14. GOUMA DJ, GO PM. Bile duct injury during laparoscopic and conventional cholecystectomy. *J Am Coll Surg* 1994;178:229-33.
15. LICHTENSTEIN S, MOORMAN DW, MALATESTA JQ, MARTIN ME. The role of hepatic resection in the management of bile duct injuries following laparoscopic cholecystectomy. *Am Surg* 2000;66:372-6.
16. LILLEMORIE KD, MELTON GB, CAMERON JL, PITT HA, CAMPBELL KA, TALAMINI MA, SAUTER PA, COLEMAN J, YEO CJ. Postoperative bile duct strictures: management and outcome in the 1990s. *Am Surg* 2000;232:430-41.
17. SCHOL FP, GO PM, GOUMA DJ. Outcome of 49 repairs of bile duct injuries after laparoscopic cholecystectomy. *World J Surg* 1995;19:753-6.
18. BEKAVAC BEŠLIN M, MIJIĆ A, SUPANC V, HOCHSTÄDTER H, KUNA T, HALKIĆ T, PERIĆ M. Laparoscopic cholecystectomy and perioperative ERCP. *Hepatogastroenterology* 2000;47:1221-2.
19. SUPANC V, DUVNJAK M, PAVIĆ T, BEKAVAC BEŠLIN M. Cystic duct clip migration – first reported case of successful endoscopic extraction of common bile duct stones resulting from surgical clips in Croatia. *Acta Clin Croat* 1999;38:55-7.
20. PULJIZ Z, KUNA T, FRANJIĆ BD, HOCHSTÄDTER H, BEKAVAC BEŠLIN M. Ozljede glavnog žučnog voda kod klasičnih i laparoskopskih kolecistektomija u KB "Sestre milosrdnice" od 1995. do 2002. Abstract Book, Third Croatian Congress of Surgery, Pula, May 15-18, 2002:231.

## Sažetak

OZLJEDE GLAVNOG ŽUČOVODA TIJEKOM OTVORENE I LAPAROSKOPSKE KOLECISTEKTOMIJE U  
KLINIČKOJ BOLNICI "SESTRE MILOSRDNICE" OD 1995. DO 2001. GODINE

Z. Puljiz, T. Kuna, B. D. Franjic, H. Hochstädter, A. Matejčić i M. Bekavac-Bešlin

Ozljeda glavnog žučovoda jedna je od najtežih komplikacija kolecistektomije. Nekoliko je multicentričnih studija pokazalo kako su ove ozljede češće kod laparoskopske negoli kod otvorene kolecistektomije. Tijekom sedmogodišnjeg razdoblja, od siječnja 1995. do prosinca 2001. godine, na Klinici za kirurgiju Kliničke bolnice "Sestre milosrdnice" u Zagrebu izvedena je kolecistektomija u 4528 bolesnika. Laparoskopska kolecistektomija učinjena je u 2657 (58%) bolesnika. Ozljeda glavnog žučovoda zabilježena je u 15 (0,33%) bolesnika. Ozljeda glavnog žučovoda nastala je u troje (0,16%) operiranih bolesnika metodom otvorene kolecistektomije. Djelomično presijecanje glavnog žučovoda nastupilo je kod dvoje bolesnika, a potpuno presijecanje kod jednog bolesnika. U skupini bolesnika kod kojih je učinjena laparoskopska kolecistektomija do ozljeda glavnog žučovoda došlo je u 12 (0,45%) operiranih: potpuno presijecanje glavnog žučovoda u petero, djelomično presijecanje u troje, ozljeda metalnom kopčom također u troje te suženje glavnog žučovoda bez intraoperacijski vidljive ozljede u jednog bolesnika i to u kasnom poslijeoperacijskom razdoblju. Svi bolesnici s jatrogenom ozljedom glavnog žučovoda koja je nastala nakon otvorene ili laparoskopske kolecistektomije liječeni su kirurški. Koledokojeuno-anastomoza po Rouxu izvedena je u devetoro bolesnika a kod šestoro bolesnika napravljena je rekonstrukcija glavnog žučovoda pomoću terminoterminalne anastomoze i uvođenjem T cjevčice. Suženje anastomoze nastupilo je u kasnom poslijeoperacijskom razdoblju u petoro bolesnika. Zato je kod njih izvedena sekundarna rekonstrukcija žučnog kontinuiteta pomoću koledokojeuno-anastomoze po Roux-u.

*Ključne riječi: Ozljede glavnog žučovoda, etiologija; Glavni žučovod-kirurgija; Kolecistektomija, laparoskopska, metode; Intraoperacijske komplikacije, kirurgija*